

# Tumour-Positive Axillary Sentinel Nodes and Their Association with Non-sentinel Node Involvement in Subsequent Axillary Clearance in Breast Cancer

S Pedamallu, D Crawford, M Lwin

## Citation

S Pedamallu, D Crawford, M Lwin. *Tumour-Positive Axillary Sentinel Nodes and Their Association with Non-sentinel Node Involvement in Subsequent Axillary Clearance in Breast Cancer*. The Internet Journal of Surgery. 2009 Volume 22 Number 2.

## Abstract

**Introduction:** This study is based on our observation that more than half of the breast cancer patients with only one tumour-positive axillary sentinel node are found to have regional disease limited to the sentinel node after completion of axillary clearance. These patients are exposed to the morbidity of axillary clearance with no tangible additional therapeutic benefit. **Methods:** Axillary clearance was performed in all tumour-positive sentinel node patients. **Results:** Out of 38 consecutive patients with tumour-positive sentinel nodes, 23 patients had one tumour-positive sentinel lymph node involved and the other 15 patients had more than one tumour-positive sentinel lymph nodes; 13.04% of single tumour-positive sentinel node patients (Group1) and 33.3% of more than one tumour-positive sentinel node patients (Group2) had metastasis to the non-sentinel nodes. **Conclusions:** More than one tumour-positive sentinel nodes patients are 2.56 times more likely to have positive non-sentinel lymph nodes than patients with only one tumour-positive sentinel node. As this association is not statistically significant, the current practice of axillary dissection following positive sentinel nodes should be continued.

## INTRODUCTION

Sentinel node is the first draining node on the direct lymphatic drainage pathway from the tumour site<sup>8</sup>. There may be single or several sentinel nodes. It is assumed that there is no nodal metastasis in the axilla, if the sentinel node is negative<sup>2</sup>. Sentinel lymph node biopsy (SLNB) offers the assessment of lymph node status for the surgical and pathological nodal staging of breast cancer<sup>1</sup>. It is a less invasive method than axillary clearance for axillary staging. Selective axillary dissection as a treatment option for regional disease control, based on the results of SLNB is the accepted standard<sup>2,7</sup>. General consensus is to omit axillary clearance in sentinel node negative patients. In our 2 years of experience in performing SLNB, more than half of the patients with only one axillary sentinel nodal involvement were found to have regional disease limited to the sentinel node after completion of axillary dissection. These patients are exposed to the morbidity of axillary clearance<sup>6</sup> with no therapeutic benefit<sup>8</sup>. Using data from patients with positive sentinel lymph nodes, this study is aimed at finding the association between number of tumour-positive sentinel lymph nodes and involvement of non-sentinel nodes found

on subsequent axillary clearance in early breast cancer.

## SUBJECTS AND METHODS

Thirty-eight consecutive patients, who underwent axillary dissection following tumour-positive sentinel lymph nodes in their axilla from September 2006 to August 2008 were included in the study. Twenty-three patients were found to have one tumour-positive sentinel lymph node (Group1) and the remaining 15 patients had more than one tumour-positive sentinel lymph nodes (Group2).

Combination technique is advocated in the national training programme in United Kingdom (NEW START) for sentinel node biopsy in breast cancer<sup>3</sup>. Briefly, sentinel lymph node biopsy involved combined technique using radio-colloid the day before the surgery if the list is the morning or on the day of surgery, if the list is in the afternoon and peri-areolar subdermal injection of patent blue dye into the tumour quadrant 5-10 minutes before the surgery. Preoperative lymphoscintigraphy was performed after injection of the radio-labelled colloid. The intraoperative gamma-probe navigator was used to track the SLN. Harvested sentinel lymph nodes were subjected to histopathological

examination using Haematoxylin and Eosin assessment. In all cases of tumour-positive sentinel lymph nodes, subsequent axillary clearance was performed as a second surgery and the tissue was sent for histology.

**RESULTS**

Out of 38 consecutive patients with tumour-positive axillary sentinel nodes, 23 patients had one tumour-positive sentinel lymph node (Group1) and the other 15 patients had more than one tumour-positive sentinel lymph nodes (Group2). After subsequent axillary clearance, metastasis to non-sentinel nodes were found in 3 out of 23 patients in Group1 (13.04%) and 5 out of 15 patients in Group2 (33.33%) (Table1).

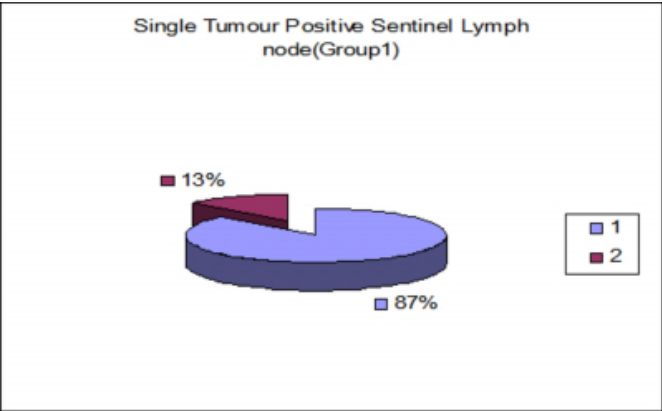
**Figure 1**

Table1: Association between number of tumour-positive sentinel nodes and non-sentinel node involvement (Fisher’s exact test, P=0.138)

	Patients with Negative Non-sentinel Nodes	Patients with Positive Non-sentinel Nodes	Total
Group1 (One SN involved)	20	3	23
Group2 (More than 1 SN involved)	10	5	15

**Figure 2**

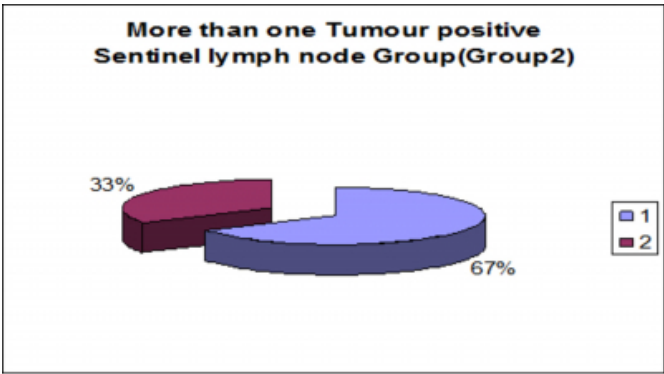
Figure 1



1: Tumour Negative Non-Sentinel nodes  
2: Tumour Positive Non-Sentinel nodes

**Figure 3**

Figure 2



1: Tumour Negative Non-Sentinel nodes  
2: Tumour Positive Non-Sentinel nodes

From our study, it is evident that patients in group2 (more than 1 tumour-positive sentinel node group) are 2.56 times more likely to have a tumour-positive non-sentinel lymph node in the subsequent axillary dissection than group1 (single tumour-positive sentinel node group). This effect is tested for statistical significance using Fisher’s Exact Test. The association between the number of positive sentinel nodes and positive non-sentinel nodes in the subsequent axillary dissection was not statistically significant (P = 0.138).

**DISCUSSION**

Sentinel node biopsy (SNB) has become accepted method of staging the axilla in early breast cancer<sup>2</sup>. The demonstration of sentinel node metastases usually invokes a complete axillary dissection, because this procedure allows nodal substaging, by specifying the number of lymph nodes involved and results in the best rates of regional disease control<sup>1</sup>.

The sentinel nodes are usually the only tumour-positive nodes in more than half of patients with sentinel node metastases<sup>8</sup>. Axillary clearance is therefore beneficial in less than half of patients with tumour-positive sentinel nodes<sup>4,8</sup>.

Many series before the sentinel node era and practically all studies on sentinel nodes and subsequent axillary dissection suggest that regional metastases are limited to the sentinel nodes in a significant percentage of the patients<sup>1</sup>. Studies of patients undergoing SLN biopsy with a concomitant axillary lymph node dissection have demonstrated that axillary metastasis will be limited to SLN in 30 to 70% of cases<sup>4</sup>. It is evident from literature review that further axillary clearance

following one positive SN is of no therapeutic benefit for most of these patients<sup>1,4,12,8</sup>. On the other hand, in those patients with tumour-positive sentinel lymph nodes, policy of not performing an axillary clearance will result in understaging and leaving disease untreated<sup>2</sup>.

Our study is unique in that it is aimed at testing the association between number of tumour-positive sentinel lymph nodes and non-sentinel nodal involvement in subsequent axillary clearance. Results showed that patients with more than one tumour-positive sentinel nodes are more likely (2.5times) to have positive non-sentinel nodes in the subsequent axillary clearance. But this effect is found to be statistically insignificant. These findings emphasise the importance of validating this association with a large sample trial. "Comparison of Complete Axillary Lymph Node Dissection with Axillary Radiation Therapy in Treating Women with Invasive Breast Cancer" (AMAROS trial), sponsored by the European Organization for Research and Treatment of Cancer, might come up with some answers regarding the alternative modalities for investigation and treatment of residual axillary disease.

**Conclusion:** Patients with more than one tumour-positive sentinel nodes are 2.56 times more likely to have positive non-sentinel lymph nodes than patients with only one tumour-positive sentinel node. As this effect is statistically insignificant, the current practice of axillary clearance in all tumour-positive sentinel node cases irrespective of the number of involved nodes has to continue, despite the morbidity with no additional therapeutic benefit in more than half of these patients.

## References

1. Cserni G, Burzykowski T, Vinh-Hung V, et al. Axillary sentinel node and tumour-related factors associated with non-sentinel node involvement in breast cancer. *Jpn J Clin Oncol* 2004; 34(9):519-24.
2. Fentiman IS. Is axillary clearance the standard of care for breast cancer patients with sentinel node involvement? (Review). *Future Oncology* 2006; 2(5):621-6.
3. Somasundaram KS, Chicken DW, Keshtgar M. Detection of the sentinel lymph node in breast cancer. *British Medical Bulletin* 2007; 84:117-131.
4. Rivers A, Hansen N. Axillary management after sentinel lymph node biopsy in breast cancer patients. *Surg Clin N Am* 2007; 87:365-77.
5. Mansel RE, Fallowfield L, Kissin M, et al. Randomized multicenter trial of sentinel node biopsy versus standard axillary treatment in operable breast cancer: the ALMANAC Trial. *J National Cancer Inst.* 2006; 98(12):599-609.
6. Husen M, Paaschburg B, Flyger HL. Two-step axillary operation increases risk of arm morbidity in breast cancer patients. *Breast* 2006; 15(5):620-8.
7. Leidenius M, Vaalavirta L, Heikkila P, et al. The prevalence of risk factors for four or more metastatic axillary lymph nodes in breast cancer patients undergoing sentinel node biopsy. *Journal of Surgical Oncology* 2008; 98(1):21-6.
8. Leidenius MH. Sentinel node biopsy in breast cancer [Review]. *Acta Radiologica* 2005; 46(8):791-801.
9. Goyal A, Newcombe RG, Chhabra A, et al. Morbidity in breast cancer patients with sentinel node metastases undergoing delayed axillary lymph node dissection (ALND) compared with immediate ALND. *Annals of Surgical Oncology* 2008; 15(1):262-7.
10. Wetzig NR, Gill PG, Ung O, et al. Participation in the RACS sentinel node biopsy versus axillary clearance trial. *ANZ J Surg* 2005; 75(3):98-100.
11. Mignotte H, Treilleux I, Faure C, et al. Axillary lymph-node dissection for positive sentinel nodes in breast cancer patients. *EJSO* 2002; 28(6):623-6.
12. Nos C, Harding-MacKean C, Freneaux P, et al. Prediction of tumour involvement in remaining axillary lymph nodes when the sentinel node in a woman with breast cancer contains metastases. *British Journal of Surgery* 2003; 90(11):1354-60.

**Author Information**

**Srinivas B. Pedamallu, MRCS(Edin)**

Department of Breast & General Surgery, Ysbyty Gwynedd Hospital

**D. J. Crawford, FRCS**

Department of Breast & General Surgery, Ysbyty Gwynedd Hospital

**M. Lwin, FRCS**

Department of Breast & General Surgery, Ysbyty Gwynedd Hospital