

Left Cervical Chyloma After Cervical Rib Excision

H Ashraf, A Ahangar, M Ashai, G Singh

Citation

H Ashraf, A Ahangar, M Ashai, G Singh. *Left Cervical Chyloma After Cervical Rib Excision*. The Internet Journal of Surgery. 2008 Volume 18 Number 2.

Abstract

Post-traumatic and post-surgical chylothorax is a common entity. Surgical excision of a cervical rib can be done either by transcervical or transaxillary approach, though transaxillary is recommended one. Injury to thoracic duct is quite rare in surgeries involving excision of a cervical rib. We report a case of a 40-year-old female who presented with a swelling in the left cervical region which had developed after left cervical rib excision done 3 months ago. Excision of the cyst revealed a chyloma. A chyloma after cervical rib excision has never been reported before.

INTRODUCTION

Chylomas are cysts or pseudocysts that arise from the thoracic duct and its tributaries. Chylomas can be either congenital or acquired.¹² Acquired chylomas can result from thoracic surgery, radical neck dissection, blunt or penetrating trauma, or tumor erosion, or they can occur secondary to subclavian vein line placement.²³

The thoracic duct is the lymphatic manhole of the body where the whole lymph drained from the body tissues and organs is dumped so as to be returned back to the circulation. Its unique anatomical course makes it vulnerable to trauma.²⁴ The thoracic duct congregates most of the chyle and lymph from the blood. Chyle is a turbid, milky fluid composed of emulsified fat, triglycerides, proteins, glucose, electrolytes, antithrombin globulin, prothrombin, and fibrinogen, as well as cellular components such as lymphocytes and erythrocytes.²⁴

Beginning as cistern chyli, at the level of the second lumbar vertebral body near the aortic bifurcation, it ascends up through the aortic opening and to the right of the aorta.¹² It continues up posterior to the esophagus in the posterior mediastinum between the aorta and the azygos vein.² At vertebral level T4 it turns to the left before exiting the thoracic inlet. It then ends in the fork between left subclavian vein and left internal jugular vein.¹ It is here that the duct system is at risk of trauma or injury during neck surgery.⁴

CASE REPORT

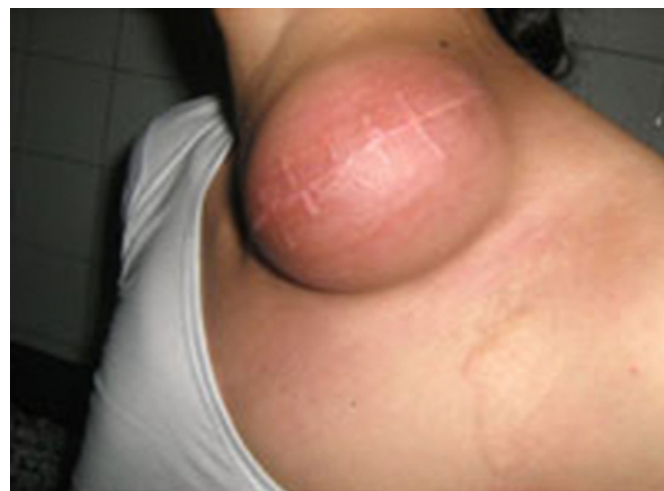We describe the case of a 40-year-old female who

presented with a soft cystic swelling in the left supraclavicular fossa. The patient was earlier operated for a left-sided cervical rib some 3 months back wherein excision of cervical rib by transcervical route was done by an orthopaedic surgeon. Two days post surgery, the patient developed a swelling in the left supraclavicular region which was gradually increasing in size. There was a history of slight difficulty in breathing but no history of dysphagia or dysphonia at the time of presentation.

Examination of the swelling revealed a 8x8cm soft, mobile mass in the left supraclavicular region hanging over the left clavicle. The swelling was lateral to the left sternocleidomastoid muscle (SCM) in the supraclavicular fossa (figure 1).

Figure 1

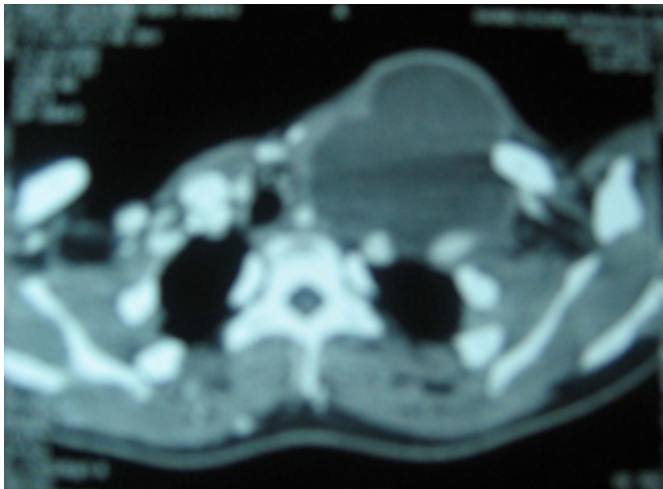
Figure 1



Bronchoscopy and oesophagoscopy were normal. Auscultation did not reveal any bruit or murmur. X-ray of the chest showed normal lung fields and clear costophrenic recesses. Fine-needle aspiration revealed milky fluid which was consistent with chyle. Contrast-enhanced computed tomography (CECT) scan revealed a 7.2x8 x7cm non-enhancing, well-marginated cystic mass of low attenuation displacing the jugular vessels and the left SCM anteromedially and the subclavian vessels posteriorly.

Figure 2

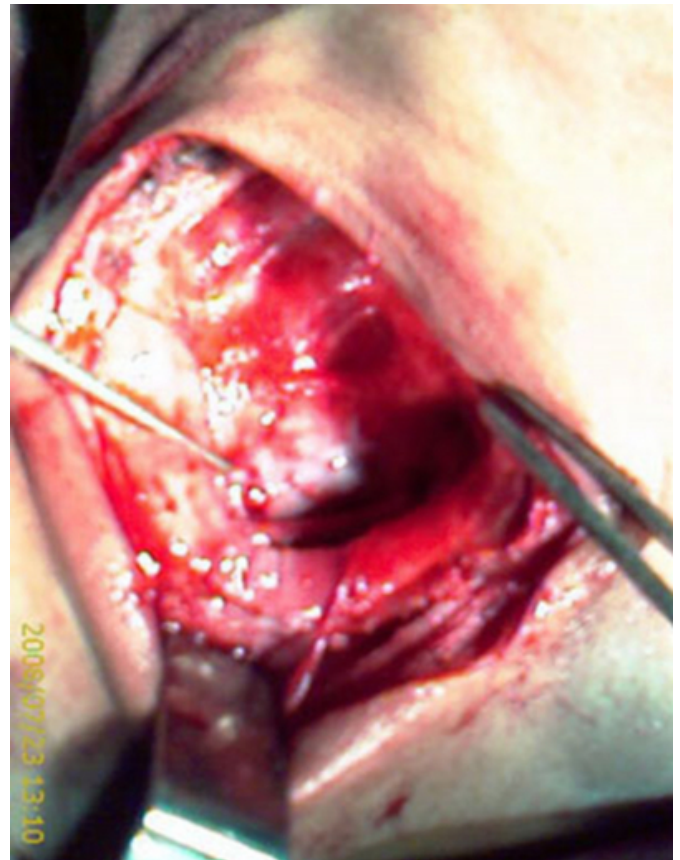
Figure 2



At surgery, an 8cm cystic mass was identified with associated lymphatic channels. Prior to incision the patient was fed with a meal of olive oil to ensure rich chylous return into the chyloma sac. The lymphatic channels were identified

Figure 3

Figure 3



and ligated with sutures. The mass was excised and sent for histopathology which was consistent with a pseudocyst. The postoperative period was uneventful.

DISCUSSION

Only a few post-traumatic or postsurgical cervical chylomas without associated chylothorax have been reported in the literature, and they were all left-sided.^{1,2,3,4,5,6} Chyloma in the left supraclavicular region has been seen after right thyroidectomy,⁴ blunt,⁵ and penetrating trauma of neck.⁷ Our case report is perhaps the first of its kind where cervical rib excision has led to this complication thereby further substantiating the use of the transaxillary route as the best for such surgery.

From the Department of Cardiovascular and Thoracic Surgery, Sheri Kashmir Institute of Medical Sciences, Soura, Srinagar, Kashmir, India

References

1. O'Neill JN. Ligation of thoracic duct for chylothorax due to blunt trauma. Case report. *Am Journal of Surg* 1965; 31: 757-8.
2. Sinclair D, Woods E, Saibil EA, Taylor GA. 'Chyloma': A persistent post-traumatic collection in the left supraclavicular

region. *J Trauma* 1987; 27: 567–9.

3. Livermore GH, Kryzer TC, Patow CA. Aneurysm of the thoracic duct presenting as an asymptomatic left supraclavicular neck mass. *Otolaryngol Head Neck Surg* 1993; 109 (3 Pt 1): 530–3.

4. Madnani D, Myssiorek D. Left cervical chyloma following right thyroidectomy. *Ear Nose Throat J* 2003; 82: 522–4.

5. Mosahebi A, Gleeson M, Owen WJ. Mass in the neck after whiplash injury. *J R Soc Med* 1998; 91: 493–4.

6. Seelig MH, Klingler PJ, Oldenburg WA. Treatment of a postoperative cervical chylous lymphocele by percutaneous sclerosing with povidone-iodine. *J Vasc Surg* 1998; 27: 1148–51.

7. Gomez J, Palacios E, Gupta JD. Post-traumatic cervical chyloma. *Ear Nose Throat J* 2008; 87: 12, 14

Author Information

Hakeem Z Ashraf, MCh

Senior Resident, Department of CVTS, SKIMS SRINAGAR

A.G. Ahangar, MCh

Professor and H.O.D, Department of CVTS, SKIMS SRINAGAR

Masrat Ashai, MBBS

House Surgeon, Department of CVTS, SKIMS SRINAGAR

Gurbinder Singh, MS

Resident, Department of CVTS, SKIMS SRINAGAR