

Appendicular Abscess Masquerading As A Liver Abscess: Value Of Laparoscopy In Diagnosis And Management

M Rangarajan, C Palanivelu, R Senthilkumar, M Madankumar

Citation

M Rangarajan, C Palanivelu, R Senthilkumar, M Madankumar. *Appendicular Abscess Masquerading As A Liver Abscess: Value Of Laparoscopy In Diagnosis And Management*. The Internet Journal of Surgery. 2005 Volume 8 Number 1.

Abstract

Subhepatic appendix is a rare position of the appendix. Inflammation of this appendix is a very rare condition and does not alter the outcome of the surgery. It can mimic cholecystitis. We present a case of abscess in the right hypochondrium, diagnosed as liver abscess. Laparoscopy revealed the truth — a subhepatic appendicular perforation with abscess. It was successfully managed. Laparoscopy in complicated appendicitis is still controversial. There are not many reports on the laparoscopic management of perforated subhepatic appendices. Care has to be taken in dissection and securing the appendicular base as the cecum will be friable. Laparoscopy is very useful, especially when the diagnosis is in doubt. Even in complicated appendicitis, it is safe and has all the benefits of minimally invasive therapy.

INTRODUCTION

Appendectomy continues to be one of the commonest procedures in general surgery. Acute appendicitis is a very common abdominal emergency, accounting for 1% of all surgical operations.¹ The various positions are retrocecal (65.28%), pelvic (31%), subcecal (2.26%), preileal (1%) and postileal (0.4%). Subhepatic and lateral pouch are very rare sites. Subhepatic position of the appendix is the direct result of a developmental anomaly.² Arrested cecal descent occurs where the cecum lies in the subhepatic position but does not descend to the right iliac fossa, known as maldescent. Intestinal malrotation is another developmental anomaly that occasionally causes an unusual array of symptoms in adults. Delay in diagnosis results in a ruptured appendix. Ruptured appendix in a subhepatic position is very rare.³ According to our Internet search; there are only a handful of reports of ruptured subhepatic appendicitis with abscess. The purpose of this report is to highlight the fact that subhepatic appendicular abscess mimics liver abscess; and sometimes even CT scan or USG cannot differentiate one from the other.

CASE REPORT

The patient was a 56-year old female who presented with fever, vomiting and right hypochondrial pain. On palpation of the abdomen, there was tenderness and a vague mass in the right hypochondrium. She was admitted with a diagnosis of acute cholecystitis. Complete blood count was taken and

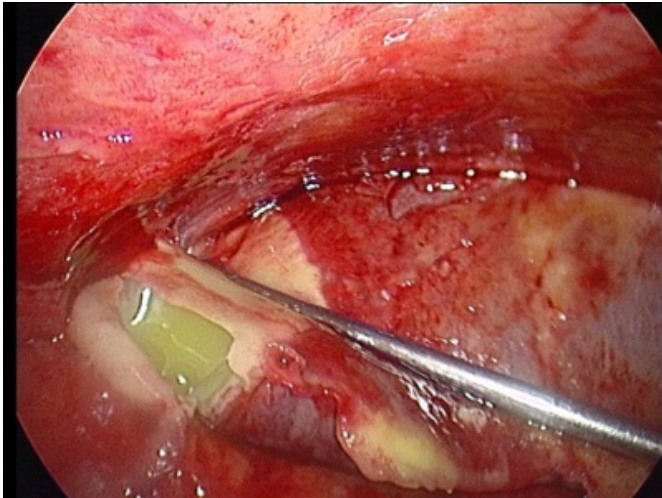
it revealed leukocytosis and mild anemia. LFT was normal. Chest radiogram was essentially normal. Ultrasonogram (USG) showed a cystic mass of size 8 x 6cm in the right hypochondrium inferior to the liver; and a part of it attached to the liver. An opacity was also seen within the mass. Appendix was not visualized. The gall bladder was normal. CT scan also confirmed the USG findings of the possibility of a liver abscess. Due to doubtful diagnosis, we decided to perform a diagnostic laparoscopy.

1. Pneumoperitoneum - Veress needle.
2. Umbilical port - laparoscope (30°, 10mm).
3. Right hand working port - epigastrium.
4. Left hand working port - right midclavicular line, 7cm below the right costal margin.

There was an inflammatory mass consisting of small bowel, cecum and omentum adherent to the inferior border of the liver. The liver as such was normal. The mass was separated from the liver with blunt dissection. Gentle nudging with the tip of a suction probe resulted in outpouring of pus from the mass (figure 1).

Figure 1

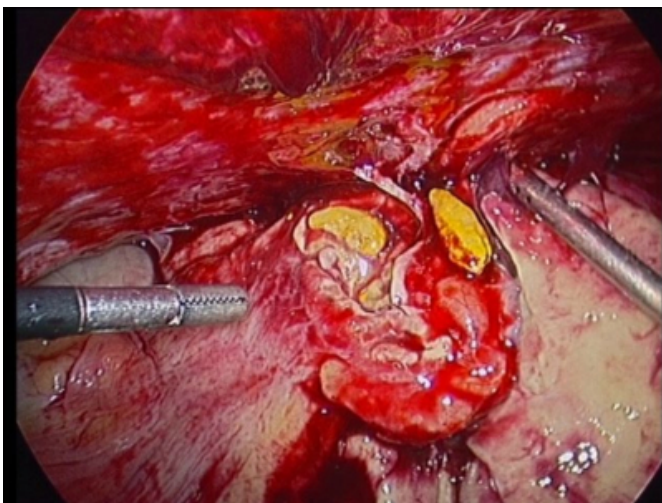
Figure 1: pus from abscess cavity; liver is seen on the right



This was sucked out and further blunt dissection was carried out with the suction probe. Along with the pus came fecoliths (figure 2) – it was an appendicular abscess arising from a perforated subhepatic appendix.

Figure 2

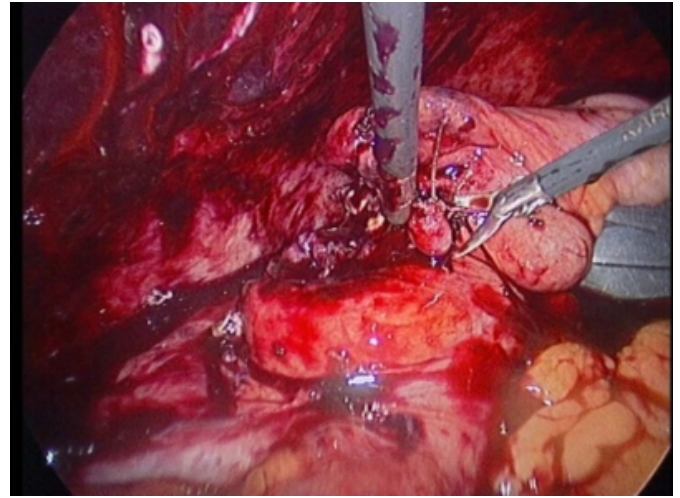
Figure 2: large fecoliths in the abscess cavity



Once the appendix was identified, submucosal appendectomy was done, as is our practice in these situations. There is always a lucid zone between the muscular wall and the mucosa of the appendix. After division of the muscle on the lateral aspect longitudinally, the entire mucosa can be removed as a tube. The dissection is performed by blunt dissection in the lucid zone using suction tip as a blunt dissector. It is easy to identify and dissect in this plane the entire mucosa up to base of the appendix. Two pre-tied endoloops were applied at the base and the appendix cut with scissors (figure 3).

Figure 3

Figure 3: dividing appendix after endoloop application



The abscess cavity was drained with a wide-bore drainage tube. She had purulent discharge through the drainage tube that gradually stopped on the 4th postoperative day POD. Liquids were allowed on the 3rd POD, after she moved her bowels. The patient was discharged on the 7th POD, totally symptom-free. Follow-up USG done after 1 month was normal.

DISCUSSION

The use of laparoscopic appendectomy for complicated appendicitis is controversial, ever since Kurt Semm performed the first successful LA in 1982. There are many studies to prove that LA is safe and effective in cases of peritonitis, perforation and abscess, with a conversion rate of 39%.¹ The presence of phlegmon, nonvisualized appendix, technical failures and bleeding were the reasons for conversion. Preoperative data had no predictive value for conversion. CT scan is the investigation of choice in these situations. Sometimes, a subhepatic appendicitis with fecolith can mimic cholelithiasis.² Appendicitis should be considered when characteristic signs and symptoms are present, even if the location of abdominal pain is atypical.⁴

In this case, laparoscopic submucosal appendectomy was used to remove the appendix. Submucosal appendectomy is a modified technique of LA. In case of dense fibrous adhesions of mesoappendix particularly when it is short, it is difficult to dissect from the mesentery, ileum, cecum and control of mesoappendix may be difficult or dangerous and may even result in injury to the adjoining bowel or mesentery. This technique prevents immediate complications. Late complications are also unlikely as the

entire diseased mucosa is removed. Even in the open technique, the same problem is present and a similar technique is necessary for safe removal of the appendix. Suturing of the base was not attempted as the tissue was friable. It is advisable to either suture through the normal cecal tissue or leave it unsutured and drain the wound. In an interesting study to determine outcome of appendicitis according to location, complicated appendicitis (gangrenous changes, perforation or abscess formation) was not found to be associated with the location of the appendix.⁵

CONCLUSION

LA is safe and effective in patients with appendicitis with peritonitis, perforation, and abscess, resulting in shorter hospital stays and less complication. It should be the initial procedure of choice for most cases of complicated appendicitis, regardless of anatomic position.

CORRESPONDENCE TO

Dr. M.Rangarajan, GEM Hospital, 45-A, Pankaja Mill Road, Coimbatore – 641045, INDIA. Tel: 0091-422-2324105
Mobile: 0091-9842320672 Fax: 0091-422-2320879 E-mail: rangy68@gmail.com

References

1. Ball CG, Kortbeek JB, Kirkpatrick AW, Mitchell P.: Laparoscopic appendectomy for complicated appendicitis: an evaluation of postoperative factors. *Surg Endosc.* 2004 Jun;18(6):969-73.
2. Rappaport WD, Warneke JA.: Subhepatic appendicitis. *Am Fam Physician.* 1989 Jun;39(6):146-8.
3. Kulvatunyou N, Schein M.: Perforated subhepatic appendicitis in the laparoscopic era. *Surg Endosc.* 2001 Jul;15(7):769.
4. Mancini GJ, Mancini ML, Nelson HS Jr.: Efficacy of laparoscopic appendectomy in appendicitis with peritonitis. *Am Surg.* 2005 Jan;71(1):1-4.
5. Chan WT, Cheng NHY, Cheng KC, et al.: Does appendix position affect the clinical outcome of acute appendicitis? *Ann Coll Surg Hong Kong.* Nov. 2002;6(4):109-112.

Author Information

Muthukumaran Rangarajan, MS, DipMIS

Professor of Surgery & Registrar in Surgical Gastroenterology, GEM Hospital

Chinnusamy Palanivelu, MNAMS, MS, MCh, FRCS, FACS

Director, GEM Hospital

Rangaswamy Senthilkumar, MS

Registrar in Surgical Gastroenterology, GEM Hospital

Madhupalayam Velusamy Madankumar, MS

Registrar in Surgical Gastroenterology, GEM Hospital