

# Sentinel Node Biopsy, Introduction and Application of the Technique in a Senology Unit of a District Hospital - Prospective Study.

Z Sidiropoulou, L De Sousa, L Ramalho, C Firmino, R Madureira

## Citation

Z Sidiropoulou, L De Sousa, L Ramalho, C Firmino, R Madureira. *Sentinel Node Biopsy, Introduction and Application of the Technique in a Senology Unit of a District Hospital - Prospective Study.* The Internet Journal of Surgery. 2008 Volume 20 Number 2.

## Abstract

In this paper we report the results of Sentinel Node Biopsy technique applied in the Senology Unit of the Hospital Nossa Senhora do Rosário-EPE, Barreiro, Portugal after 3 years of application and a minimum of 12 months of follow-up. Objective: To evaluate the results achieved according to the international guidelines. Patients and Methods: This work presents the two phases of the implementation of the technique, validation and application, describing the outcomes in a range of a 3-year experience and regarding 117 patients with breast cancer. Results: In the validation phase we report a sensitivity of 87% and a specificity of 96%. In the application phase we report a sensitivity of 86% and a specificity of 100%. Conclusions: Once the international recommendations regarding the quality of the technique to be applied have been achieved, our concern is focused on the follow-up of the sentinel node biopsy negative patients.

## INTRODUCTION

Nowadays sentinel node biopsy plays a well established role in breast cancer staging and treatment. By definition, it consists in removal of the first node that receives the breast lymphatic drainage pathway from the primary tumour and it offers an alternative to routine axillary lymph node dissection, which is avoided when the node is negative<sup>1</sup>.

Our objective is to present the experience on sentinel node biopsy applied in our unit from January 2005 to January 2008, divided in two subgroups. The first one consisting of the "learning phase" or validation stage which includes 50 patients and the second one consisting of the application phase which includes 67 patients.

## PATIENTS AND METHODS

In both phases we achieved the Hospital's Ethics Committee approval and a written consent was obtained from all the patients.

In both phases the same data sheet model has been used, reporting: age and gender of the patient, primary tumour localization and its staging (TNM), previous biopsies, primary tumour cyto-histological type, estrogen receptor state and surgical protocol. In the same sheet, there were reported,

by responsibility of each stage chief: the technical details of radiocolloid injection and results, blue-dye injection and results, intra-operative node identification and results, surgery performed, and anatomo-pathology report.

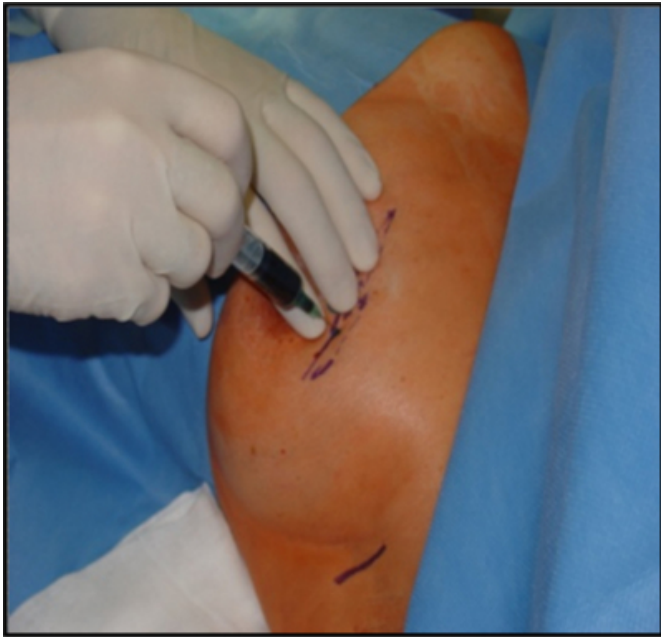In the validation phase, from January 2005 to August 2006, 50 patients were included, who underwent Sentinel Node Biopsy Sampling followed by axillary lymph node dissection (ALND). Inclusion criteria were: T1 and T2, resectable breast tumours, palpable or not, with clinically negative axillae. Patients with previous breast biopsy, multicentric tumours, clinically positive axilla and pregnancy were excluded.

The technique applied was based in a standardized protocol using:

- A peritumoral injection for palpable tumours and for non-palpable tumours a subareolar injection of 0,4cc of 99mTc-radiolabelled colloidal renium, the day before surgery (16-20 hours). After 4 hours of the radiocolloid injection, lymphoscintigraphic images were obtained. The location of the nodes (axillary and not) was marked on the skin.
- the day after, in the operating room, 2cc of Patent Blue V dye diluted with saline were injected (photo 1).

**Figure 1**

Photo 1: Patent Blue V injection

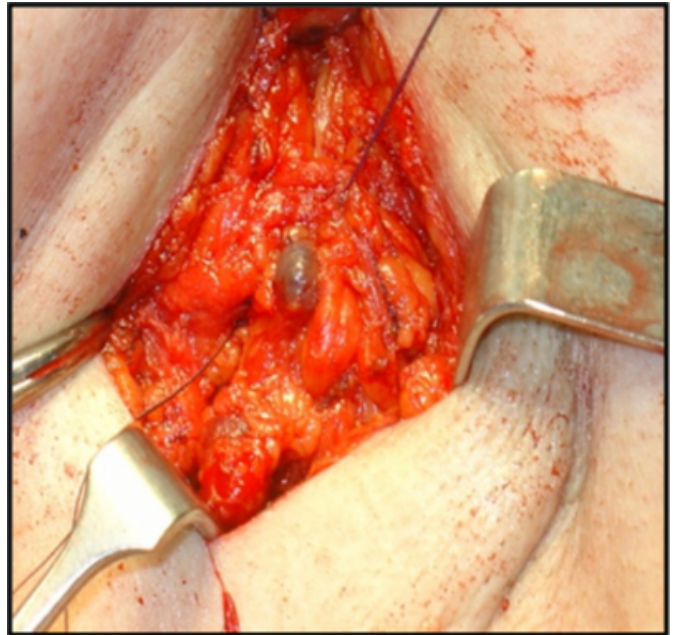


The injection was followed by brief and gentle massage of approximately 5-10 min., in order to enhance the drainage. A transversal skin incision was made 1cm below the axillary hair area.

Opening of the superficial fascia was followed by incision of the clavipectoral fascia and searching for the blue-dyed lymphatics that lead to the presumed sentinel node (Photo 2).

**Figure 2**

Photo 2: Sentinel node blue-dyed

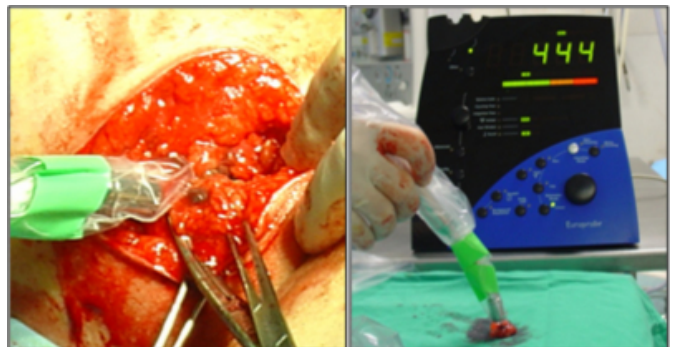


In the case that a second node existed, it was also excised. Afferent and efferent lymphatics were left tied.

- There were excised: the node or nodes blue-stained or any node with radioactive counts more than 20 times the background count. The detection probe used was a gamma IV of 140 KeV (Photos 3 and 4).

**Figure 3**

Photos 3 and 4: Radi probe detection of the sentinel node



- The node or nodes excised were immediately brought to the anatomico-pathology laboratory. The node was bisected by its major axis, half of it was analyzed in intra-operative analysis by congelation fixation and the other half followed for paraffin fixation. In the cases of negative node, more slices were obtained in order to identify possible micro-metastasis: peripheric ones, using a microtome of 200 microns. The sentinel node was evaluated with hematoxylin-

eosin and immunohistochemistry (anti-CAM 5.2) while the satellite nodes were evaluated only with hematoxylin–eosin.

- During the validation phase, all patients received a complete level III axillary dissection.

In the second phase, the therapeutic application phase, which is the actual one to be applied and after the approval of the hospital's ethical committee, we have amplified the inclusion criteria. Patients with multifocal tumours and previous breast biopsy were admitted.

In this paper we analyse the results from August 2006 to March 2008, in a series of 67 patients.

The methodology used is the same as in the validation phase, with dual technique (radio-colloid and Patent blue dye injection) performed in each patient.

In this phase we proceeded to axillary dissection only when the sentinel node was revealed to be positive or in cases in which it has not been identified.

We follow a protocol of vigilance of all our patients with special advice for axillary recurrence.

## **RESULTS: VALIDATION PHASE**

Sentinel node biopsy was performed in 43 patients (rest: 5 cases of non-identification of the node and 2 cases of instrument's failure). In the latter patients complete axillary level III excision was performed.

The results give us a sensitivity rate of 87% and a specificity rate of 96%. The mean time of sentinel node identification was 21 min., whereas the mean number of nodes isolated was of 1.65. The mean number of satellite nodes excised was 0.30.

The identification rate was 88.3%.

Surgeons considered the technique easily feasible in 73.2% of the cases.

## **RESULTS: APPLICATION PHASE**

Sentinel node biopsy was performed in 62 of 67 patients that met the criteria of inclusion (rest: 2 cases of non-identification of a sentinel node and 3 of instrument's failure). In those 5 patients complete axillary level III node dissection was performed.

The results give us a sensitivity rate of 86% and a specificity rate of 100% (since no axillary node dissection has been

performed); 42 patients have indeed been spared the invasive axillary node dissection.

The mean time of sentinel node identification was 18 min., whereas the mean number of nodes isolated was of 1.25. The mean number of satellite nodes excised was 0.50.

The identification rate was 96.9%.

Surgeons considered the technique easily feasible in 85.7% of the cases.

## **DISCUSSION**

As sentinel node biopsy is a routine technique in staging and therapeutic attitude of breast cancer, its application is of fundamental priority in a Senology Unit<sup>2</sup>. The obvious advantages regard not only minor surgical invasion and patient morbidity but also less extended operating room occupancy<sup>3</sup>.

As observed in the two distinct phases of this study, there has been a slight decrease in the sensitivity rate, in the order of 1%. The actual sensitivity rate of 86% is still an excellent result.

The false negative results respect the <5% recommendations<sup>4</sup>, even if we believe that our rate of 0% is due to the small number of this series and the relatively limited time of follow-up passed in order to identify any nodal recurrence.

The identification rate also fulfils the ASCO recommendations<sup>5</sup>. We have passed from 88.3% to an actually very good level of 96.9%.

The identification time has been slightly reduced, from 21 to 18 minutes, whereas surgeons consider the technique more easily feasible.

Our concern in this phase is focused on the follow-up of the sentinel node biopsy negative patients in order to identify possible axillary node recurrences and to evaluate the disease-free survival rates in a long-term prospective.

Until now, in March 2009, and after a minimum of 12 months and a maximum of 41 months trimestral clinical and echographic control, even if the follow-up period is still short, we report no axillary node recurrence of the disease in the cases of sentinel node negative biopsy, which we consider is an excellent result.

## **References**

1. Grube JB, Giuliano EA. The current role of sentinel node biopsy in the treatment of breast cancer. *Adv Surg* 2004; 38: 121-166
2. Cserni G. Axillary staging of breast cancer and the sentinel node. *J Clin Pathol* 2000; 53: 733-741
3. Hoar FJ, Stonelake PS. A prospective study of the value of axillary node sampling in addition to sentinel lymph node biopsy in patients with breast cancer. *EJSO* 2003; 29: 526-531
4. Allweis TM, Badriyyah M, Ad Bar V, et al. Current controversies in sentinel lymph node biopsy for breast cancer. *The Breast* 2003; 12: 163-171
5. Lyman GH, et al. American Society of Clinical Oncology Guideline Recommendations for Sentinel Lymph Node Biopsy in Early-Stage Breast Cancer. *JOC* 2005; 23: 7703-7713

**Author Information**

**Zacharoula Sidiropoulou, MD**

Hospital Nossa Sra do Rosário, Barreiro, Senology Unit, Av. Movimento das Forças Armadas Barreiro, Portugal

**Luis De Sousa, MD**

Hospital Nossa Sra do Rosário, Barreiro, Senology Unit, Av. Movimento das Forças Armadas Barreiro, Portugal

**Lurdes Ramalho, MD**

Hospital Nossa Sra do Rosário, Barreiro, Senology Unit, Av. Movimento das Forças Armadas Barreiro, Portugal

**Carlos Firmino, MD**

Hospital Nossa Sra do Rosário, Barreiro, Senology Unit, Av. Movimento das Forças Armadas Barreiro, Portugal

**Rosa Madureira, MD**

Hospital Nossa Sra do Rosário, Barreiro, Senology Unit, Av. Movimento das Forças Armadas Barreiro, Portugal