

# The Dinner Fork Deformity

D Iyer

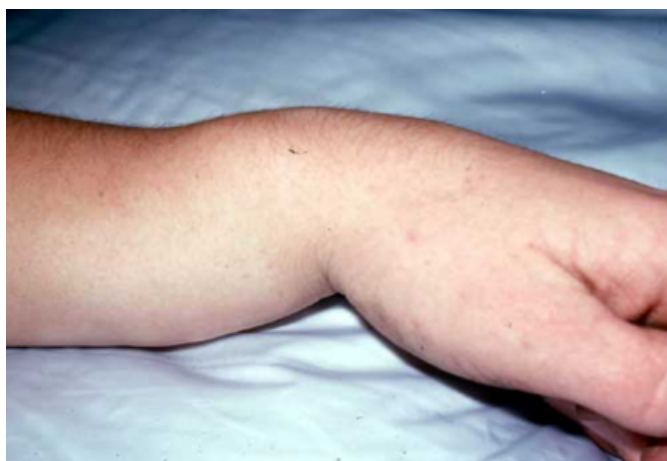## Citation

D Iyer. *The Dinner Fork Deformity*. The Internet Journal of Orthopedic Surgery. 2006 Volume 5 Number 1.

## Abstract

Fractures of the distal radius are among the most common injuries treated by the Orthopaedic surgeon. The injury that John Abraham Colles described in 1814, is a transverse fracture of the radius just proximal to the wrist, with dorsal displacement and angulation of the distal fragment, being the most prominent feature. These fractures have been estimated to account for one sixth of all fractures seen and treated in the Emergency Department.

**Figure 1**



## EXTENSION FRACTURES OF THE DISTAL RADIUS

Multiple classification schemes have been developed for extension injuries of the distal radius. These tend to be complex and cumbersome. In general, however, the greater the degree of displacement and comminution, the more severe the injury. Extension of a fracture into the radiocarpal or the Distal Radio Ulnar Joint is also a marker for a more severe injury. More complex fractures tend to be more unstable.

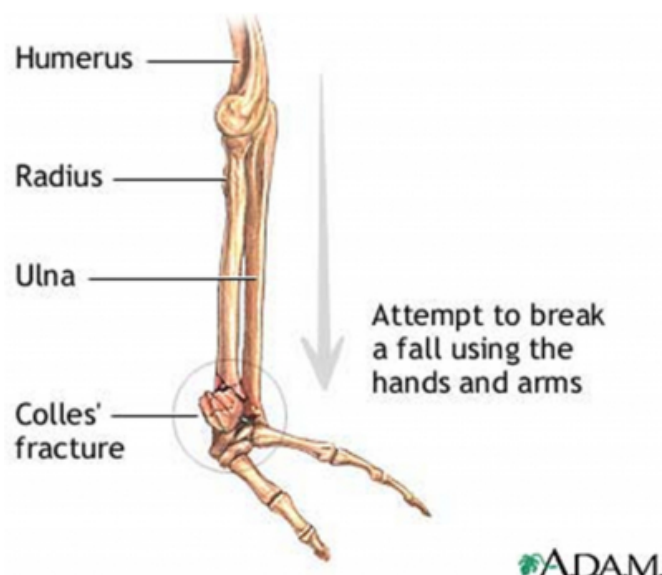
Extension fractures result from a fall on an outstretched pronated hand with the impact on the palm and subsequent forced dorsiflexion or hyperextension. On striking a hard surface, the hand becomes fixed while the momentum of the body produces the following 2 forces:

- Twisting force that causes excessive supination of the forearm

- Compression force that acts vertically through the carpus to the radius

Colles fracture is the most common extension fracture pattern. It is usually caused by a fall onto an outstretched hand (FOOSH). The term classically is used to describe a fracture through the distal metaphysis approximately 2.5 centimeters proximal to the articular surface of the radius. However, now the term tends to be used loosely to describe any fracture of the distal radius, with or without involvement of the ulna, that has dorsal displacement of the fracture fragments.

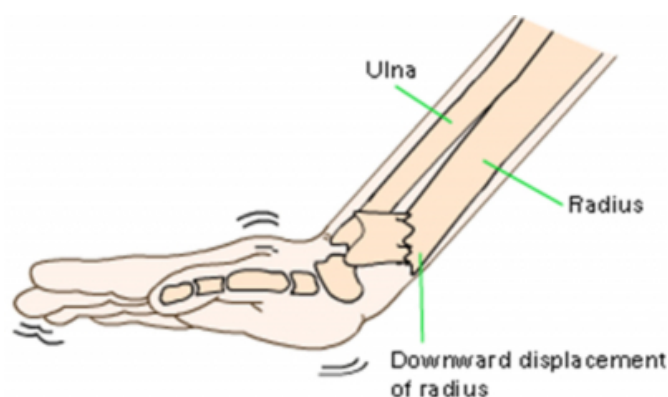
**Figure 2**



Colles fractures occur in all age groups, although certain patterns follow an age distribution. In the elderly, because of the relatively weaker cortex, the fracture is more often

extraarticular. Younger individuals tend to require a relatively higher energy force to cause the fracture and tend to have more complex intraarticular fractures. In children with open physes, an equivalent fracture is the epiphyseal slip. This is a Salter Harris Type I or Type II fracture with the deforming forces directed through the weaker epiphyseal plate.

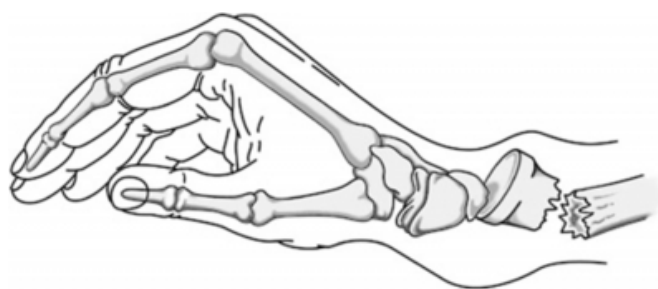**Figure 3**



©2000 Merck & Co., Inc.

There are many associated injuries with Colles' fracture. The Median Nerve is the most commonly injured and is usually compressed by the angulation of fragments. Proximal radioulnar joint subluxation or dislocation may also occur, making examination of the elbow important. Carpal fractures, flexor tendon injuries, and ulnar nerve impingement may also be found.

**Figure 4**



### UNIVERSAL CLASSIFICATION OF DORSAL DISPLACED RADIUS FRACTURES

- Type I: extra articular, undisplaced;
- Type II: extra articular, displaced;
- Type III: intra articular, undisplaced;

- Type IV: intra articular, displaced;

The classic finding in a Colles fracture is the so-called dinner fork deformity, which is produced by dorsal displacement of the distal fracture fragments.

### TREATMENT

This fracture requires immediate reduction and immobilisation in a plaster cast. The 2 keys to successful reduction of the typical Colles fracture are as follows:

- Place the hand and wrist in the position of injury and pronate the forearm, which corrects the supination twist of the distal fractured segment. This can be done with the aid of the Weinberg finger traction apparatus or with an assistant to fix the arm at the elbow. By recreating the mechanism of injury and the position of the bony fragments at injury, the periosteal ligaments are relaxed, which allows for easier reduction of the fracture.
- Extend the wrist to 90°, with the elbow fixed and the forearm supinated, and pull the distal segment back, up, and out at approximately 120°. Use both thumbs to push the distal fragment into alignment as the arm is pronated.
- Emergency Department treatment includes application of a back slab with the wrist held in flexion, with ulnar deviation and pronation of the forearm.
- The following parameters would be considered an unacceptable position of the fracture fragments and would be appropriately treated by reduction of the fracture:
  - 10 degrees of dorsal tilt from neutral measured along the long axis of the radius on the lateral view,
  - Between 5 – 10 mm of Radial shortening,
  - An intra-articular step of >2mm.

1. ORIF is indicated only in cases involving the radiocarpal joint where reduction is not satisfactory or the reduction has slipped. The most common procedures would include:
3. External fixation

4. K wires
5. Dorsal plating.
1. Obtain post reduction x-rays; assess and document neurovascular status of the extremity after reduction. Document function of the median nerve and the sensory branch of the radial nerve.
2. Serial Follow up in the Orthopaedic clinic is very necessary, with a first repeat X Ray after 5 days to 1 week. This is very important as even reduced fractures have chances of slipping.
3. The fracture normally takes around 6 weeks to unite, after which intensive physiotherapy is needed.

Colles' fractures are associated with a 20% to 30% incidence of complications, including Median and Ulnar Nerve impairment, extensor pollicis longus tendon rupture, post-reduction swelling with development of compartment syndrome, stiffness, cosmetic deformity, malunion or nonunion, and chronic pain. Early reduction is the key to avoiding these problems.

### **ACKNOWLEDGEMENTS**

I wish to thank my Father, Mr. Krishna Mohan Iyer,

Consultant Orthopaedic Surgeon, for his invaluable help and guidance, and also Mr. Nicholas Garlick, Consultant Orthopaedic Surgeon, for his immense encouragement and assistance.

### **References**

- r-0. APLEY'S SYSTEM OF ORTHOPAEDICS AND FRACTURES: 8th edition, Louis Solomon, David J. Warwick, Selvadurai Nayagam
- r-1. <http://health.allrefer.com/health/colles-wrist-fracture-colles-fracture.html> ( Accessed on 21/11/05)
- r-2. <http://mdchoice.com/emed/main.asp?template=0&page=detail&type=8&id=1078> ( Accessed on 21/11/05)
- r-3. [http://orthoinfo.aaos.org/fact/thr\\_report.cfm?Thread\\_ID=150&topcategory=Arm](http://orthoinfo.aaos.org/fact/thr_report.cfm?Thread_ID=150&topcategory=Arm) ( accessed on 21/11/05)
- r-4. <http://www.eatonhand.com/hw/hw020.htm> ( Accessed on 21/11/2005)
- r-5. <http://www.emedicine.com/emerg/topic844.htm> : Bryan Hoynak, MD, Laura Hopson, MD ( Accessed on 21/11/05)
- r-6. <http://www.nlm.nih.gov/medlineplus/ency/article/000002.htm> ( Accessed on 21/11/05)
- r-7. [http://www.wheelessonline.com/ortho/colles\\_fr](http://www.wheelessonline.com/ortho/colles_fr) ( Accessed on 21/11/05)
- r-8. SKELETAL TRAUMA ( Vol 2 ): Brown, Jupiter, Levine, Trafton.
- r-9. <http://www.cpsa.ab.ca/publicationresources/attachments-messengers/fractures.pdf> ( Accessed on 21/12/05 )

**Author Information**

**Deepa Iyer, Honorary SHO**

Dept of Orthopaedics, Royal Free Hospital