

Laparoscopic Removal And Replacement Of Tube Gastrostomy In The Management Of Buried Bumper Syndrome

P Ballester, B Ammori

Citation

P Ballester, B Ammori. *Laparoscopic Removal And Replacement Of Tube Gastrostomy In The Management Of Buried Bumper Syndrome*. The Internet Journal of Surgery. 2003 Volume 5 Number 2.

Abstract

Background/Aim: Erosion and migration of the inner bumper of a percutaneous endoscopic gastrostomy (PEG) tube through the gastric wall with overgrowth of the gastric mucosa over it results in failure of feed delivery. Removal of the PEG tube in such patients is often accomplished by laparotomy or endoscopically, approaches that have their drawbacks and limitations. We describe removal and replacement of a Freka PEG tube in a patient with a buried bumper syndrome by laparoscopic surgery without the resort to endoscopy.

Method: A 70-year-old man who was established on long term enteral feeding via a PEG tube following a cerebrovascular accident presented 3 years later with occlusion of the tube. Endoscopy demonstrated a buried internal bumper. The bumper and tube were removed laparoscopically and another gastrostomy tube was placed at laparoscopy without the need for endoscopy.

Result: The surgery was completed laparoscopically within 80 minutes. The patient resumed feeding via the new gastrostomy tube within 12 hours, had an uncomplicated recovery, and was discharged on the 3rd postoperative day.

Conclusion: Laparoscopic removal of PEG tubes complicated with the buried bumper syndrome and their simultaneous laparoscopic replacement is a safe and reliable, minimally invasive management option.

INTRODUCTION

The introduction of percutaneous endoscopic gastrostomy (PEG) tube for enteral feeding was first described in children in 1980 [1]. The application of PEG tubes for long-term enteral nutrition is now commonly employed in patients unable to feed orally due to a variety of clinical scenarios [2]. These include patients on artificial ventilation, neurological patients with lost swallowing reflex, and patients with pharyngeal or laryngeal tumours [2].

Buried bumper syndrome is a rare complication (less than 2%) of PEG tubes [3,4] where the gastric mucosa overgrows and seals the internal bumper of the tube. It is thought to arise as a result of excessive tension between the inner and outer bumpers of the PEG tube [5], and might be more frequent with tubes that have a rigid rather than soft inner bumper. Often this condition is symptomatic and leads to mechanical failure of feed delivery and peritubal discharge. Occasionally the dislocated inner bumper of the PEG tube erodes through the gastric wall leading to bleeding, perforation, peritonitis and death [6,7].

PEG tubes complicated with a buried bumper require

removal, and replacement if necessary. Removal is accomplished by endoscopic means [1,8,9] or via a mini-laparotomy [8]. More recently however, we have described the removal of a PEG tube in a patient with a buried bumper syndrome by the laparoscopic approach [10]. In addition, the role of the laparoscopic approach to insertion of gastrostomy feeding tubes in patients unsuitable for the conventional endoscopic insertion of PEG tubes is recognised [11]. We describe herein for the first time the laparoscopic removal and replacement of a 'PEG' tube in a patient with a buried bumper syndrome without the resort to endoscopic assistance for its replacement.

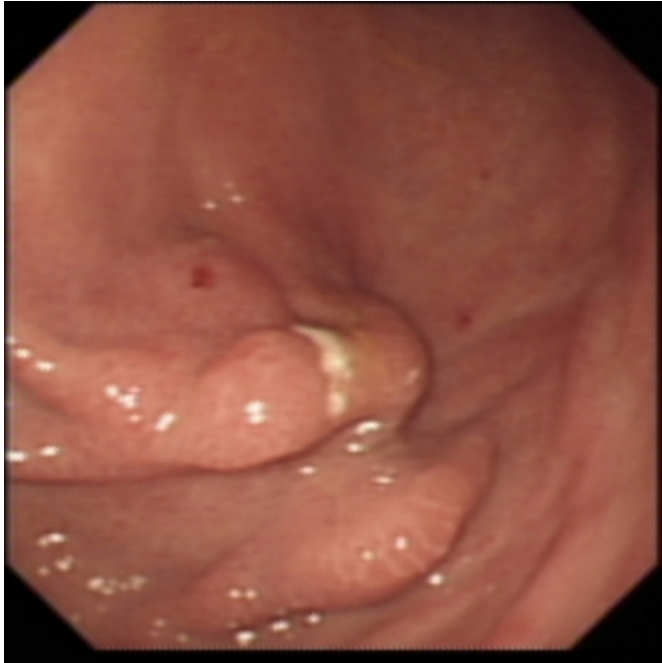
CASE REPORT PATIENT

A 70-year-old man was admitted to the medical ward with an obstructed PEG tube. He had suffered a cerebrovascular accident with a subsequent impairment of swallowing and epilepsy three years previously, and has since been enterally fed via a Freka PEG tube (Fresenius Ltd, Warrington, UK). An upper gastrointestinal endoscopy demonstrated an overgrowth of gastric mucosa over the inner bumper of the

PEG tube (Figure 1). The patient was referred to our laparoscopic unit with a diagnosis of buried bumper syndrome for the purpose of its removal and replacement. Abdominal examination revealed a Kocher and gridiron abdominal scars of previous cholecystectomy and appendicectomy respectively.

Figure 1

Figure 1: Endoscopic view shows over-healing of the gastric mucosa over the inner bumper of the PEG tube



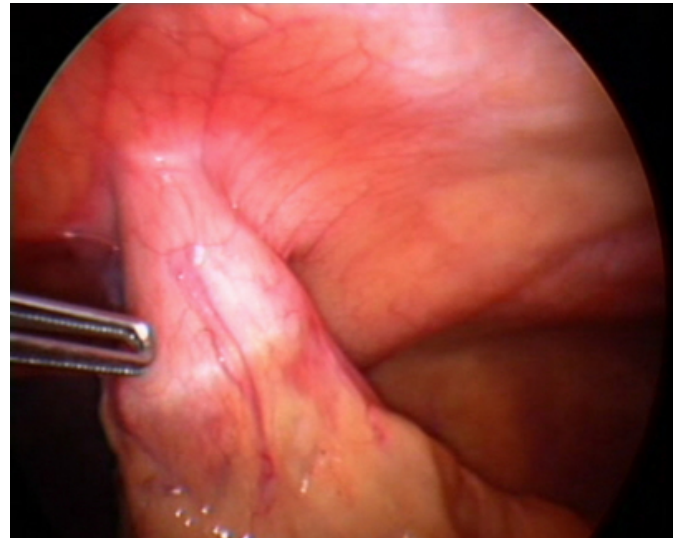
He underwent a laparoscopic removal of the buried bumper and PEG tube with its simultaneous laparoscopic replacement.

OPERATIVE TECHNIQUE

Laparoscopy was performed under general anaesthesia with the patient in supine position, and employed two 5-mm and one 12.5-mm ports under 12-mmHg intra-abdominal pressure of capnoperitoneum. The stomach was found to be adherent to the abdominal wall only at the site of the passage of the PEG tube (Figure 2). The gastric wall containing the buried bumper was excised using the ultrasonically activated scalpel (Ethicon Endo-Surgery, Cincinnati, OH, USA).

Figure 2

Figure 2: Laparoscopic view: note that the inner bumper is wider in diameter than the area of adhesion of the anterior gastric wall to the abdominal wall



A new X-Fr Freka 'PEG' tube (Fresenius Ltd, Warrington, UK) was introduced into the peritoneal cavity. An Endoclave™ device (Mantis Surgical Limited, Newbury, Berkshire, UK) was introduced through a skin puncture in the anterior abdominal wall and its spike was advanced through the anterior gastric wall at a more proximal location to the site of the removed PEG (Figure 3A). The Endoclave™ device was used to grasp and retrieve the thread-bearing end of the gastrostomy tube through the gastrotomy (Figure 3B), anterior gastric and abdominal walls until the inner bumper was placed within the gastric lumen (Figure 4A). The gastrotomy (site of excision of the gastric wall harbouring the buried bumper) was then closed with continuous Vicryl 2-0 suture (Ethicon Inc., Somerville, New Jersey, USA) in two layers (Figure 4B). The anterior gastric wall was fixed to the abdominal wall around the new gastrostomy tube with a purse string intracorporeal suture. The resected gastric wall harbouring the buried bumper (Figure 5) was retrieved at conclusion of the surgery in a water-impervious bag (Lapsac surgical tissue pouch, Cook Incorporated, Bloomington, IN, USA).

Figure 3

Figure 3: Laparoscopic view showing the Endoclaw[®]™ device advanced through the anterior gastric wall proximal to the gastrotomy after excision of the gastric wall harbouring the buried bumper (Figure 3A). The Endoclaw[®]™ device is used to grasp the threaded end of the new Freka PEG tube (Figure 3B)

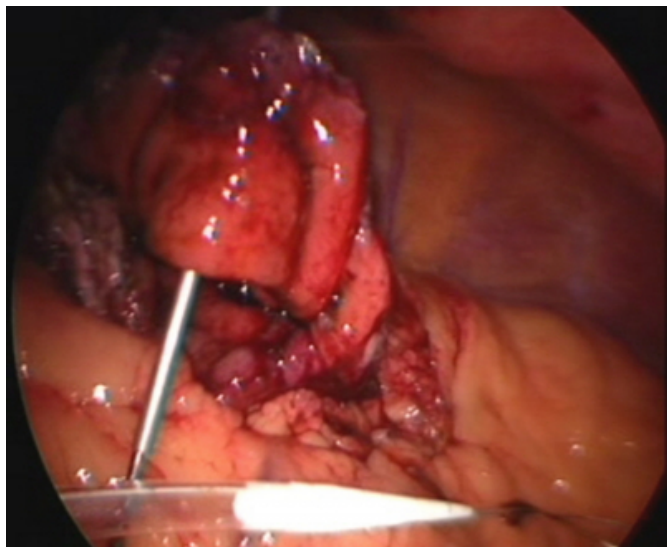


Figure 4

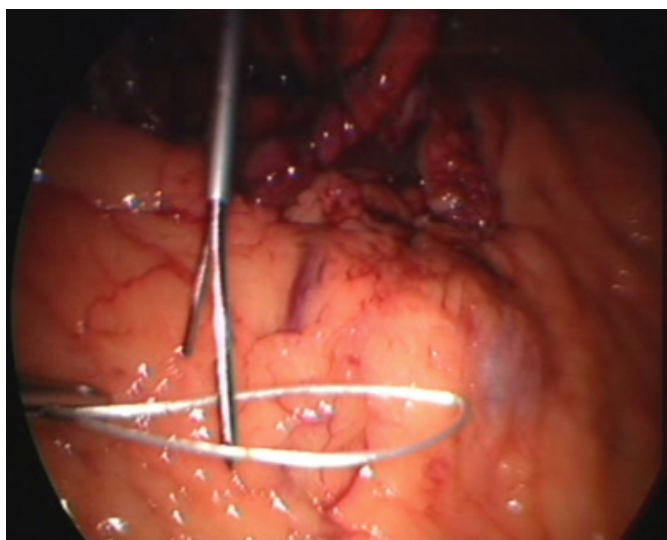


Figure 5

Figure 4: Laparoscopic view showing the new proximal site of the replacement PEG tube (Figure 4A), and suture closure of the gastrotomy (Figure 4B)

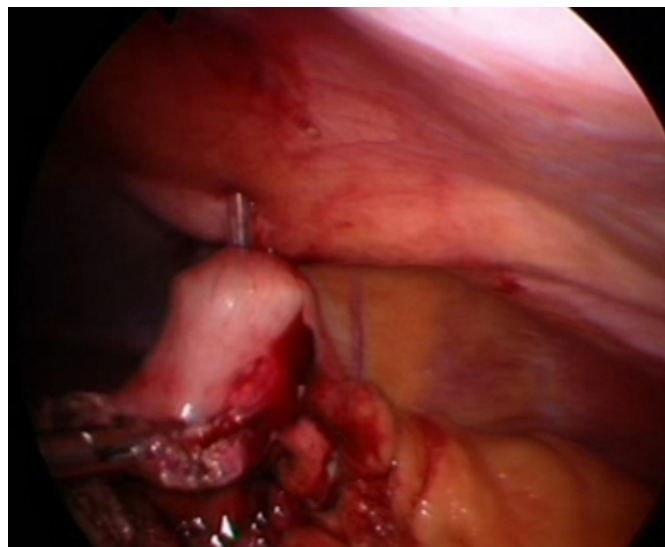


Figure 6

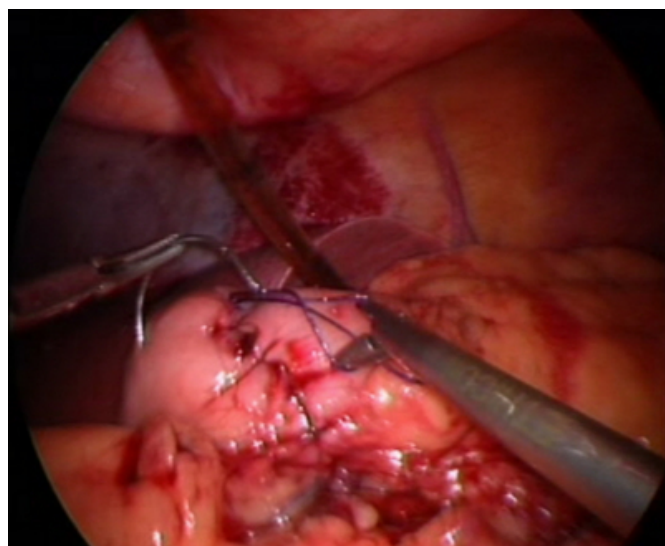
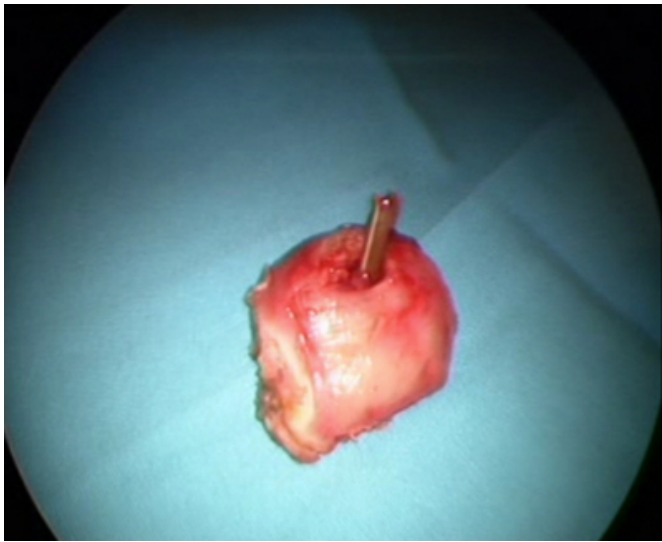

Figure 7

Figure 5: Picture showing the excised gastric wall harbouring the buried bumper



OUTCOME

The procedure was completed laparoscopically, and the total operating time was 80 minutes. There were no intraoperative or postoperative complications. The patient resumed feeding via the new gastrostomy tube within 12 hours and was discharged on the 3rd postoperative day. His feeding via the tube gastrostomy continues unhindered at follow up 6 weeks later.

DISCUSSION

The laparoscopic approach to removal and replacement of PEG tubes in patients with buried bumper syndrome is feasible and safe, and appears to offer some advantages over endoscopic and open surgical approaches.

The endoscopic approach involves incision of the overgrown mucosa with exposure and snare extraction of the buried inner bumper. However, it carries the risk of bleeding [8] and unrecognised gastric perforation. The risk of perforation may be more clearly appreciated from examination of the laparoscopic appearance of the buried bumper in our patient (Figure 2). The diameter of the area of adhesion between the gastric wall and the abdominal wall at the site of the PEG tube is smaller than the diameter of the inner bumper. Hence, endoscopic incision of the mucosa over the inner bumper with a needle-knife will extend beyond the area of adhesion risking perforation into the abdominal cavity. This risk is probably increased as a result of distension of the stomach with air during endoscopy as the stomach wall is then stretched and its thickness reduced. In addition, endoscopic

replacement of the PEG tube carries a recognised, albeit small, risk of colonic perforation [12]. Furthermore, dislodgement of the PEG tube during the initial 7-10 days after its endoscopic placement may lead to intraperitoneal leakage of gastric contents and peritonitis.

Unlike the endoscopic approach, laparoscopic removal of the buried bumper avoids the problem of an unrecognised gastric perforation. Moreover, laparoscopic replacement of the PEG tube avoids colonic injury as it is carried out under intraperitoneal vision, and safeguards against the consequences of inadvertent early tube dislodgement and removal as the gastric wall is suture fixed to the abdominal wall around the PEG tube.

Whilst the PEG tube may be removed at a mini-laparotomy at the site of passage of the tube through the abdominal wall, this local exploration may carry a considerable risk of wound infection, particularly that the buried bumper is often associated with local abscess formation [10]. The simultaneous insertion of another PEG tube through the mini-laparotomy wound may increase the recognised risk of wound infection with this procedure [12].

Unlike open surgery, the laparoscopic approach involve placement of the ports at sites distant from the PEG and avoids cutting of muscle and fascia, factors that minimise the risk of wound infection. This principle is more readily recognised in patients with acute appendicitis undergoing laparoscopic appendicectomy where the risk of wound complications is lower than that of open surgery where the wound is sited over the inflamed appendix [13,14]. Moreover, the avoidance of muscles and nerve cutting during laparoscopic surgery may explain, to a large extent, the reduction in postoperative pain compared with open surgery in instances where the cumulative length of skin incisions is not dissimilar, such as with laparoscopic appendicectomy [13].

Laparoscopic removal and replacement of the PEG tube in patients with buried bumper syndrome is safe, avoids the shortcomings of the endoscopic and open approaches, and facilitates prompt and secure resumption of enteral feeding.

CORRESPONDENCE TO

Mr. Basil J. Ammori, FRCS, MD Consultant Hepato-Pancreato-Biliary and Laparoscopic Surgeon Manchester Royal Infirmary, Oxford Road, Manchester M13 9WL, UK
Tel: 0044-161-2763510, Fax: 0044-161-2764530, E-mail:

Bammori@aol.com

References

1. Gauderer MW, Ponsky JL, Izant RJ Jr. Gastrostomy without laparotomy: a percutaneous endoscopic technique. *J Pediatr Surg* 1980;15:872-875.
2. Nicholson FB, Korman MG, Richardson MA. Percutaneous endoscopic gastrostomy: a review of indications, complications and outcome. *J Gastroenterol Hepatol* 2000;15: 21-25.
3. Gencosmanoglu R, Koc D, Tozun N. Percutaneous endoscopic gastrostomy: results of 115 cases. *Hepatogastroenterology* 2003;50:886-888.
4. Finocchiaro C, Galletti R, Rovera G, Ferrari A, Todros L, Vuolo A, Balzola F. Percutaneous endoscopic gastrostomy: a long-term follow-up. *Nutrition* 1997;13:520-523.
5. Spalinger R, Schmid P, Bertschinger P, Schob O, Largiader F. [The "buried bumper syndrome"--a rare complication of percutaneous endoscopic gastrostomy]. *Swiss Surg* 1999;5:243-246.
6. Taller A, Horvath E, Harsanyi L, Kotai Z, Simig M, Ilias L. [Percutaneous endoscopic gastrostomy: experience of three years]. *Orv Hetil* 1999;140:1347-1352.
7. Dormann AJ, Mussig O, Wejda B, Huchzermeyer H. [Successful use of a button system in "buried bumper" syndrome]. *Dtsch Med Wochenschr* 2001;126:722-724.
8. Braden B, Brandstaetter M, Caspary WF, Seifert H. Buried bumper syndrome: treatment guided by catheter probe US. *Gastrointest Endosc* 2003;57:747-751.
9. Ma MM, Semlacher EA, Fedorak RN, Lalor EA, Duerksen DR, Sherbaniuk RW, Chalpelsky CE, Sadowski DC. The buried gastrostomy bumper syndrome: prevention and endoscopic approaches to removal. *Gastrointest Endosc* 1995;41:505-508.
10. Boreham B, Ammori BJ. Laparoscopic percutaneous endoscopic gastrostomy removal in a patient with buried-bumper syndrome: a new approach. *Surg Laparosc Endosc Percutan Tech* 2002;12:356-358.
11. Roeyen G, Chapelle T, Nonneman L, De Leeuw I, Ysebaert D. Laparoscopic-assisted gastric button placement: a valuable alternative for a percutaneous endoscopic gastrostomy (PEG). *Acta Chir Belg* 2003;103:95-97.
12. Fox VL, Abel SD, Malas S, Duggan C, Leichtner AM. Complications following percutaneous endoscopic gastrostomy and subsequent catheter replacement in children and young adults. *Gastrointest Endosc* 1997;45:64-71.
13. Garbutt JM, Soper NJ, Shannon WD, Botero A, Littenberg B. Meta-analysis of randomized controlled trials comparing laparoscopic and open appendectomy. *Surg Laparosc Endosc* 1999;9:17-26.
14. Temple LK, Litwin DE, McLeod RS. A meta-analysis of laparoscopic versus open appendectomy in patients suspected of having acute appendicitis. *Can J Surg* 1999;42:377-383.

Author Information

Pedro Ballester, FRCS

Clinical Fellow HPB Surgery, Manchester Royal Infirmary

Basil J. Ammori, FRCS,MD

Consultant Surgeon, Manchester Royal Infirmary