

Synchronous primary malignancy of ovary and cervix with different histopathology: a rare presentation

K Srivastava, F Zahra

Citation

K Srivastava, F Zahra. *Synchronous primary malignancy of ovary and cervix with different histopathology: a rare presentation*. The Internet Journal of Gynecology and Obstetrics. 2009 Volume 12 Number 2.

Abstract

Background: Synchronous primary malignancies of the female genital tract are uncommon. Synchronous ovarian and cervical malignancies with different histopathology are rarer still. **Case:** A 55-year-old woman with poor general condition presented with ascites and post-menopausal bleeding. She was diagnosed to have ovarian serous adenocarcinoma, clinical stage III and cervical squamous cell carcinoma, clinical stage III B. She deteriorated rapidly after a cycle of chemotherapy and expired after nineteen days. **Conclusion:** Synchronous genital malignancies cause more clinical problems as compared to singly occurring ones. Hence such cases tend to be detected at an earlier stage. However, the prognosis is determined not only by clinical staging but also by histological grade of the adenomatous component. Incidence of multiple synchronous malignancies may be expected to increase in view of increased life expectancy.

INTRODUCTION

The incidence of synchronous primary malignancies of the female genital tract is 0.63%. Out of these the commonest is the endometrioid carcinoma of the ovary and endometrium (40%) which carries a favourable prognosis because of earlier detection and low grade malignancy [1]. Other reports of synchronous malignancies of ovary and cervix have similar histopathology so the possibility of these being metastatic lesions can be ruled out only after thorough histopathological study of the surgical specimens [2]. The present case is even rarer with entirely different histopathology of ovarian and cervical malignancy. Only one similar report could be found in English literature.

CASE REPORT

A 55-year-old woman with a poor general condition was admitted with gradual distention of abdomen for one year and irregular mild vaginal bleeding for the last three months. There was accompanying dull pain in abdomen, shortness of breath, nausea and vomiting for last one week. She had gradual loss of weight and appetite for the last three months. There was no history suggestive of haemoptysis, haematemesis, malaena, haematochezia, bone pains, recent fracture, neurological or urinary symptoms, previous menstrual disturbance or excessive vaginal discharge. There was no family history of malignancy of genital tract, breast

or colon. She was a multipara with one live issue twenty years old, widowed six years back and menopausal for last five years.

On examination she was cachexic, pale, dehydrated, tachypnoeic and had edema over feet. Abdomen was distended and tense (Fig.1) with prominent veins and fluid thrill. Superficial lymph nodes were not enlarged and breasts were soft and atrophied. Per-speculum examination revealed irregular growth of the posterior lip of cervix measuring approximately 3x3 cm which bled on touch (Fig. 2).

Figure 1

Figure 1: Malignant ascites with prominent veins.

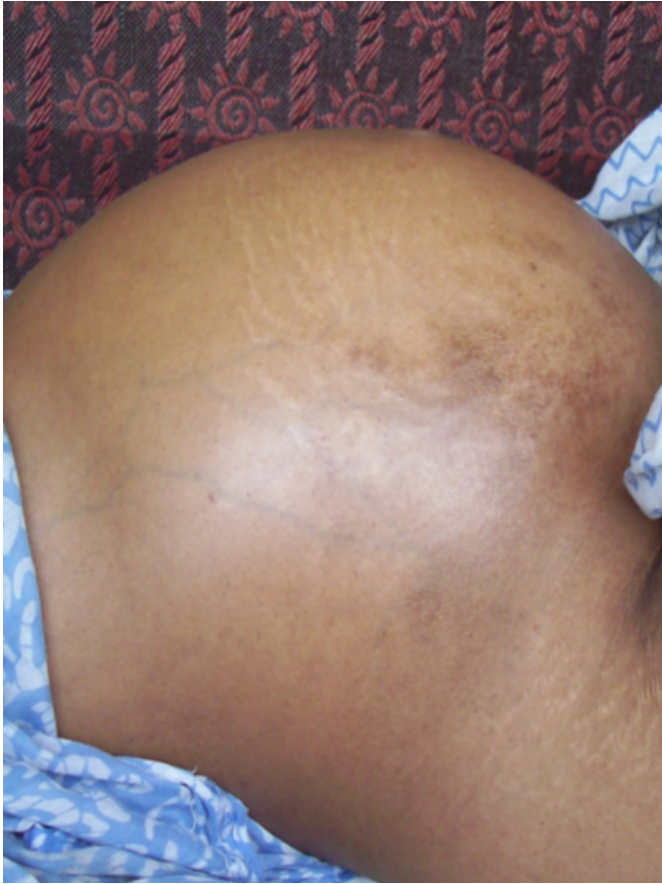
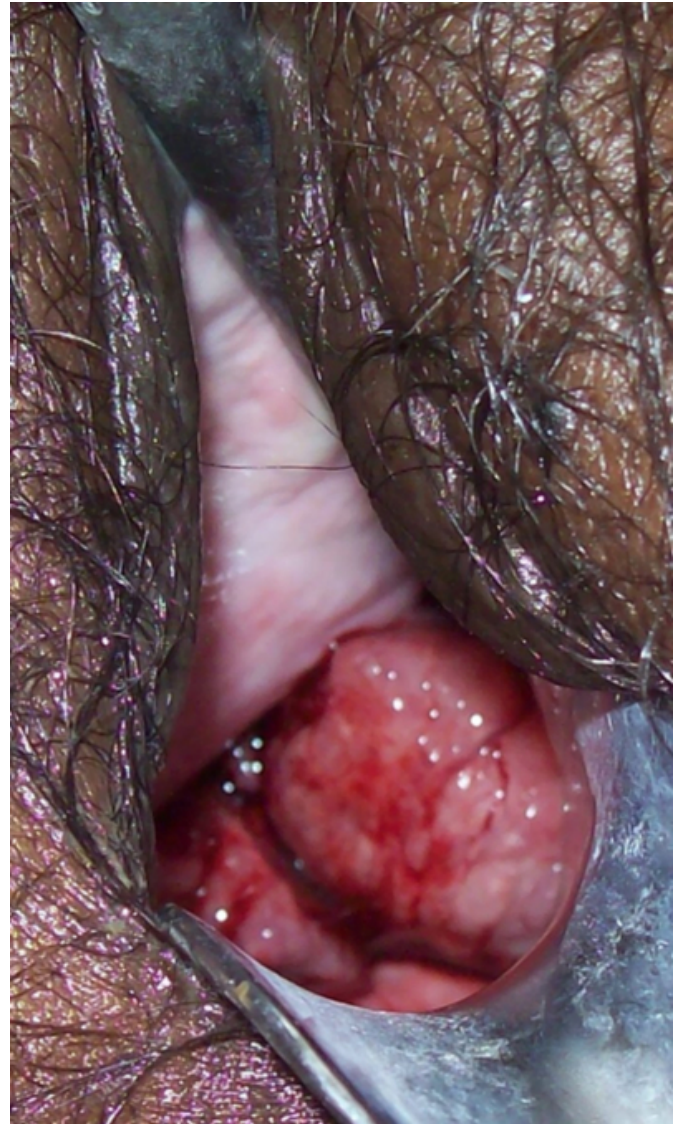
Figure 2

Figure 2: Friable cervical growth as seen on speculum examination.



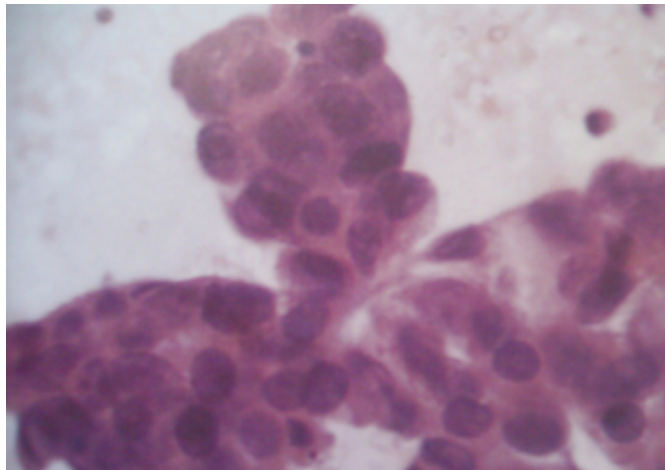
Rest of the vagina appeared normal. On per-vaginum examination the growth extended from left fornix till the left pelvic walls and there was no downward extension to the vaginal walls. A vague irregular lump could be felt in the pelvis through the right fornix. Nothing else could be made out due to ascites. On per-rectal examination rectal mucosa was free and an irregular growth could be felt extending from left parametrium to the left pelvic wall. A vague irregular lump could be felt in the pelvis on the right side. Uterus could not be made out clearly.

Vigorous supportive therapy was initiated to improve her general condition. Her haemoglobin was 9.4 gm/dl with mild anisocytosis, hypochromia and raised ESR. Blood glucose, serum electrolytes, liver and renal functions were within

normal limits. Ascitic fluid aspirate was mildly turbid and had 400 cells/mm³ consisting of lymphocytes and malignant cells. ECG and X-ray chest were within normal limits. On abdominal ultrasound, there was massive ascites. An echogenic right adnexal mass with cystic areas measuring 8.2×6.8×6.1 cm was present in the right adnexa. Right ovary was not visualized separately from the mass. Uterus measured 8.5×4.1×3.1 cm and endometrial thickness was uniformly 4 cm. There was an echogenic area extending from the left parametrium to the left pelvic wall. Left ovary measured 3.5×2.5 cm Lymph-nodes were not enlarged. Bowel, liver and kidneys appeared normal. Ultrasound guided fine needle aspiration cytology of right adnexal mass reported serous cystadenocarcinoma (Fig.3) of the ovary.

Figure 3

Fig.3: FNAC showing serous cystadenocarcinoma of the ovary.



Cervical tissue biopsy confirmed squamous cell carcinoma. A cycle of chemotherapy was given but the patient deteriorated rapidly and died after nineteen days.

DISCUSSION

In a patient with primary gynecological malignancy, synchronous malignancies elsewhere in the body have to be ruled out as their incidence is 4.3% [3]. Incidence of synchronous genital tract malignancy is 0.63%. Out of this endometrioid carcinoma of ovary and endometrium constitutes 40% [1]. Less than 20 cases of three synchronous malignancies have been reported, but almost all of them

have a similar adenomatous histological picture [2].

Squamous cell CA of the cervix being metastatic to the ovary is rare and has unusual ovarian histopathology for a primary [4]. One case of four synchronous malignancies of the genital tract with variations of adenomatous types has been reported in 2007 [5]. A single case of synchronous ovarian and cervical malignancy with ovarian endometrioid adenocarcinoma and frank squamous cell CA of cervix has been reported in 1996 [6].

It is important to distinguish multiple primary neoplasms from metastatic disease as overall survival and treatment would vary considerably. Multiple primary neoplasms do not have worse prognosis in terms of survival than single ones. The prognosis will depend not only on clinical stage but also on histopathological grading of the adenomatous component [5]. There is paucity of data for exact criteria to distinguish multiple primary from metastatic disease.

Validity of immunohistochemical and cloning studies is also not clear [5]. Centralised Registration of such cases with standardized protocol is required [7] in view of expected increase in incidence due to increase in life expectancy.

References

1. Tong SY, Lee YS, Park JS, Bae SN, Lee JM, Namkoong SE: Clinical analysis of synchronous primary neoplasms of the female reproductive tract. *Eur J Obstet Gynecol Reprod Biol*, 2008; 136(1):78-82.
2. Ilesanmi AO, Edozien LC, Williams GA, Ladipo OA: Synchronous carcinomas of cervix and ovary: case reports. *Afr J Med Med Sci*, 1994 Dec;23(4):397-400.
3. T. Takeda, S. Sagae, M. Koizumi, K. Terasawa, S. Ishioka, S. Takashima & R. Kudo: Multiple primary malignancies in patients with gynecologic cancer. *International Journal of Gynecological Cancer*, 2002; (5)1: 34-39.
4. Young RH, Gersell DJ, Roth LM, Scully RE: Ovarian metastases from cervical carcinomas other than pure adenocarcinomas. A report of 12 cases. *Cancer*, 1993; 71(2): 407-18.
5. Pekin T, Yoruk P, Yildizhan R, Yildizhan B, Ramadan S. Three synchronized neoplasms of the female genital tract: an extraordinary presentation. *Arch Gynecol Obstet*. 2007 Nov;276(5):541-5. Epub 2007 May 24.
6. Pitylski K, Bogdanowicz M, Jawornik M: Coexistence of endometrioid ovarian tumor and squamous cell carcinoma of the cervix. *Ginekol Pol*, 1996; 67(12):629-31.
7. Kilciksiz S, Gokce T, Somali I, Uysal D, Baloglu A, Yigit S: A case with three different synchronous primaries of the female genital system and their treatment. *J BUON*. 2007 Apr-Jun;12(2):291-3.

Author Information

Kumkum Rani Srivastava, MD OBG

Head, Department of Obstetrics and Gynecology, Era's Lucknow Medical College

Fatima Zahra, MD OBG

Assistant prof, Department of Obstetrics and Gynecology, Era's Lucknow Medical College