

Mayer-Rokitansky-Küster-Hauser Syndrome In A Caribbean Population: A Case Report

J Essien, J Bardales

Citation

J Essien, J Bardales. *Mayer-Rokitansky-Küster-Hauser Syndrome In A Caribbean Population: A Case Report*. The Internet Journal of Gynecology and Obstetrics. 2004 Volume 5 Number 1.

Abstract

Mayer-Rokitansky-Küster-Hauser (MRKH) syndrome is characterized by Mullerian duct system anomalies, vaginal atresia is the most frequent variant. It can be associated with renal, skeletal, spine and other malformations.

Objective: The first documented case of MRKH syndrome on the West Indian island of Nevis is reported. A 54 year-old female presented describing primary amenorrhea, infertility and protrusion of the anterior vaginal wall. Clinical and sonographic examination confirmed vaginal atresia, agenesis of the uterus, as well as a moderate cystocele. Surgical correction of the cystocele was performed, further corrective dilatory surgery of the vagina was recommended and psychological support was provided.

INTRODUCTION

Mayer-Rokitansky-Küster-Hauser (MRKH) syndrome was first described by Mayer in 1829 and Rokitansky in 1838.^{1, 2} Its incidence is 1 in 4,000 to 5,000 females and affects all races equally.³ The syndrome was described as the agenesis of the uterus and vagina due to abnormal development of the müllerian ducts; uterine and vaginal agenesis were reported by Rokitansky, while Mayer described some vaginal duplications.^{1,2,3,4} In 1910, Küster recognized urologic associations, such as renal ectopy or agenesis.⁵ In 1961, Hauser differentiated MRKH from testicular feminization.⁶ Although rare, MRKH syndrome represents 15% of cases of primary amenorrhea and as such is usually not suspected or diagnosed until adolescence.⁷ Given the reproductive, psychological and sexual repercussions that this entity has on the affected patients, continuity of medical and psychological care is a must. A variety of surgical procedures are now available that attempt to correct the deficiencies of the vaginal canal, allowing these patients to benefit from a normal sexual functioning.⁸

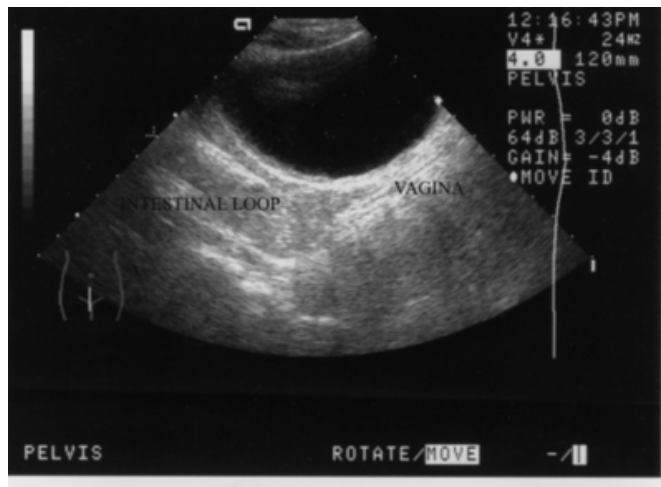
She denied any family history of congenital disorders or exposure to teratogenic agents. Hormonal tests (Estradiol, FSH, LH, TSH, Prolactin) were all within normal limits for a adult female in the follicular phase. Preliminary clinical examination revealed a normal female phenotype, normal labia majora and minora in addition to a shallow and blind vaginal pouch, measuring 4,5 centimeters in length and 3 centimeters wide. The cervix was not visualized on speculum exam. Descent of the anterior vaginal wall was diagnosed as a moderate cystocele. Transabdominal and transvaginal sonographic scan of the abdomen and pelvis confirmed congenital agenesis of the uterus and the presence of ovaries as well as the absence of urinary tract anomalies. The cystocele was corrected surgically under general anesthesia by anterior colporrhaphy. Further corrective dilatory surgery of the vagina was recommended and psychological support was provided. It is of interest to note that the Island of Nevis has a population of 11,000 and this is the first documented and reported case of Mayer-Rokitansky-Küster-Hauser syndrome.

CASE REPORT

A 54 year-old black female presented complaining primarily of a vaginal protrusion restricting further an already limited sexual function. Upon further interview, she confirmed that she has been presenting primary amenorrhea and infertility.

Figure 1

Figure 1: Transabdominal pelvic sonogram showing absence of uterus.



DISCUSSION

Under-development of the Müllerian duct system may result in different urogenital anomalies. These malformations are the source of intense concern for both the patient and her family due to their repercussions on reproductive health as well as psychological and sexual impact. Initial diagnosis of these anomalies is made usually during adolescence.^{3,7,8} Uterine anomalies have been reported to occur in 1 in 594 fertile women (0.17%) and in 1 in 29 infertile women (3.5%).³ The MRKH syndrome can be regarded as resulting from the cessation of development of the Mullerian duct between the sixth and seventh week of gestation, which in this condition extends only as far as its attachment to the caudal mesonephric ligament, the round ligament.^{3,4,7,8,9} The adjacent structures beyond this point, which include the connecting strand and smooth muscle bundles dorsal to the bladder and vaginal rudiment, are derivatives of the Wolffian duct or Gartner's duct, respectively and renal agenesis or ectopia is common.^{4,8,9} Some patients will report difficulty voiding or have recurrent urinary tract infections. It has also been suggested that this syndrome is due to a deficiency of the estrogen and gestagen receptors which may inhibit the further development of the embryonic Mullerian duct.⁴ The vertebral bodies, derived from the embryonic mesoderm, are also vulnerable at this time; however, skeletal abnormalities usually do not have clinical significance.^{4,7,9} Genetic link for MRKH syndrome has not been demonstrated and female relatives of the patient apparently have no increased risk.^{3,7,9} Patients usually present with normal pubertal development, primary amenorrhea and cyclic abdominal pain. Other concerns that

prompt medical attention include inability to have intercourse or infertility.^{3,8,9} Transabdominal ultrasound can be used as a preliminary study to evaluate for remnants of uterine tissue as well as to assess the renal system. Other imaging techniques, such as magnetic resonance imaging have been proven to give better resolution of the pelvic anatomy.^{7,8,9,10} Laparoscopy is often used in the diagnostic process or to remove remnants of uterus.⁸ The methods for surgical correction including dilation of the vaginal pouch or grafting a vaginal canal, the most common of which is the McIndoe technique which utilizes a skin graft usually from the thigh and a removable stent to prevent stenosis.⁸ Other procedures have used grafts of other origin.^{8,11,12,13} In all cases, complications include: extensive skin scarring at the donor graft site, rectovaginal and urethrovaginal fistulae, vaginal discharge, dyspareunia, vaginal stenosis, and inadequate vaginal lubrication.^{11,12} These complications have provided grounds for poor patient compliance with the subsequent long-term vaginal dilation.^{8,11} Normal sexual functioning can be attained after surgical reconstruction, although conception cannot occur without the help of a surrogate.^{11,12,13}

References

1. Mayer CAJ: Über verdoppelungen des uterus und ihre arten, nebst bemerkungen über hasenscharte und wolfsrachen. *J Chir Auger* 1829; 13:525-565.
2. Rokitansky K: Über die sogenannten verdoppelungen des uterus. *Med Jahrb Ost Staat* 1838; 26:39-77.
3. Nahum GG. Uterine anomalies. How common are they, and what is their distribution among subtypes? *J Reprod Med.* 1998 Oct;43(10):877-87
4. Ludwig KS. The Mayer-Rokitansky-Kuster syndrome. An analysis of its morphology and embryology. Part I: Morphology. *Arch Gynecol Obstet.* 1998; 262(1-2):1-26.
5. Küster H: Uterus bipartitus solidus rudimentarius cum vagina solida. *Z Geb Gyn* 1910; 67:692.
6. Hauser GA, Schreiner WE: Mayer-Rokitansky-Küster syndrome: rudimentary solid bipartite uterus with solid vagina. *Schweiz Med Wocenschr* 1961; 91:381-384
7. JR Pletcher et al. Menstrual disorders: Amenorrhea. *Pediatr Clin North Am.* 46(3): 505-18, 1999.
8. Rock JA: Surgery for anomalies of the mullerian ducts. In: *Te Linde's Operative Gynecology* (8th ed.). Edited by J Rock, J. Thompson. Philadelphia, Lippincott-Raven, 1997.
9. Spence JE. Vaginal and uterine anomalies in the pediatric and adolescent patient. *J Pediatr Adolesc Gynecol.* 1998;11(1):3-11.
10. L Fedele et al. Magnetic resonance imaging in Mayer-Rokitansky-Kuster-Hauser syndrome. *Obstet Gynecol.* 76(4): 593-6, 1990.
11. Cali RW, Pratt JH. Congenital absence of the vagina: Long term results of vaginal reconstruction in 175 cases. *Am J Obstet Gynecol* 1968; 100: 752.
12. Edmonds DK. Congenital malformations of the genital tract and their management. *Best Pract Res Clin Obstet Gynaecol.* 2003 Feb;17(1):19-40.
13. Patankar SP, Kalrao V, Patankar SS. Mayer - Rokitansky

syndrome and anorectal malformation. Indian J Pediatr

2004;71:1133-1135

Author Information

John Essien, M.D.

Obstetrician/Gynecologist, Attending Gynecologist, Alexandra Hospital

Jessica Bardales, M.D.

Obstetrician/Gynecologist, Alexandra Hospital