Inflammatory Pseudo-Tumor Of Ovary - A Case Report

S Bharatnur, V Ramkumar, K Natrajan

Citation

S Bharatnur, V Ramkumar, K Natrajan. *Inflammatory Pseudo-Tumor Of Ovary - A Case Report*. The Internet Journal of Gynecology and Obstetrics. 2012 Volume 16 Number 1.

Abstract

Inflammatory pseudo tumor is a rare soft tissue tumor. We present a case of inflammatory pseudo tumor in a young girl which was mistaken for ovarian malignancy. A final diagnosis was made on histopathological examination as inflammatory pseudo-tumor or myofibroblastoma. This case is reported due to its rarity. Inflammatory pseudo tumor has a high recurrence but rarely metastasis. It usually requires surgical intervention and the final diagnosis is made by histopathology examination.

INTRODUCTION

Inflammatory pseudo tumor (IPT) also known as myofibroblastic tumor or plasma cell granuloma is a neoplasm of intermediate biologic potential. The lung is most commonly involved and extra pulmonary lesions are considered uncommon.[1]

This distinctive neoplasm is composed of myofibroblastic mesenchymal spindle cells accompanied by an inflammatory infiltrate of plasma cells, lymphocytes, and eosinophils. Although it occurs primarily in the lungs, soft tissues and viscera of children and young adults, in recent years its occurrence in a wider age group has been documented.[2] In this study we report the case of a young girl who presented with abdominal mass close to the external iliac vessels, suggestive of para ganglioma. After laparotomy, histopathology examination revealed findings suggestive of inflammatory pseudo-tumor.

CASE REPORT

A 17 year unmarried girl presented to the out-patient department with fever. The patient gave history suggestive fever with evening rise of temperature, loss of weight and generalized weakness since 2 months. Her menstrual cycles were regular. No history of exposure to tuberculosis in the past and no family history suggestive of tuberculosis.

On examination she had pallor which was mild. Her BMI was 15 kg/M^2. Abdominal examination showed a mass in the right iliac fossa measuring about 6 X 6 cm. Lower border however was ill defined. The mass was tender, firm and mobile. A provisional diagnosis of tuberculosis or ovarian tumor was made based on history and physical examination.

Investigation done showed the following results, hemoglobin (Hb%)- 6.8g/dL; Total Count (TC)–8,400 cells/cubic-millimeter; lymphocytes- 85%; ESR- 140mm at the end of 1 st hour. Peripheral smear showed normocytic, normochromic anemia. Renal and liver function tests were within normal limits. Tumor markers CA-125 was 45.4 U/dL. Mantoux test was negative.

Trans-abdominal sonography showed a right-sided well defined oval, lobulated mixed echogenic lesion of 6.6 x 6.6 cm seen in the lower abdomen insinuating into the pelvis. Uterus and ovaries were both normal. Kidneys were normal in size and there was no hydronephrosis. Doppler ultrasound showed increased Doppler indices with multiple vessels (both arteries and veins) passing through this mass which was highly vascular.

Computed tomography (CT-scan) of abdomen and pelvis showed well circumscribed, lobulated, heterogeneous mass in right lower pelvis of approximately 6.2 x 6.6 cm. The contents showed severe enhancement in the arterial phase, not involving the right ovary which was suggestive of paraganglioma/paraovarian cyst/Nerve sheath tumor/dysgerminoma. As there was no clear diagnosis of the condition, exploratory laparotomy was performed.

At laparotomy, there was a retroperitoneal 12 x 10 cm hard mass which was free from iliac vessels, uterus, fallopian tube and ovaries with dilated veins over the surface which was adherent to the omentum.

Figure 1

Fig-1: Picture showing tumour with ovary, and caecum

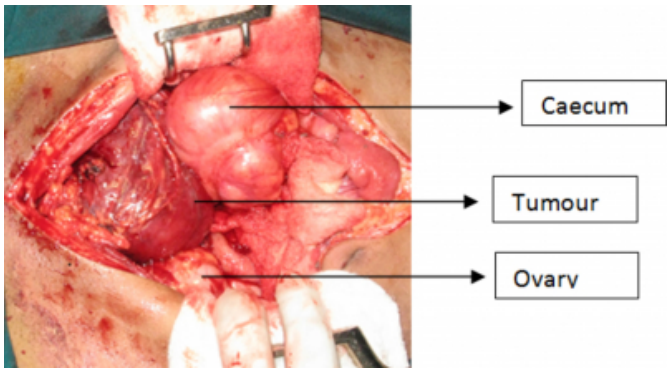

The mass was infiltrating into the caecum for which sharp dissection was made and was excised with the wall of caecum. 3-0 absorbable sutures were used to close the caecum (Fig- 1 & 2). The post operative period was uneventful. There was no recurrences after one year follow up.

Figure 2

Fig-2: Picture showing normal uterus and right ovary

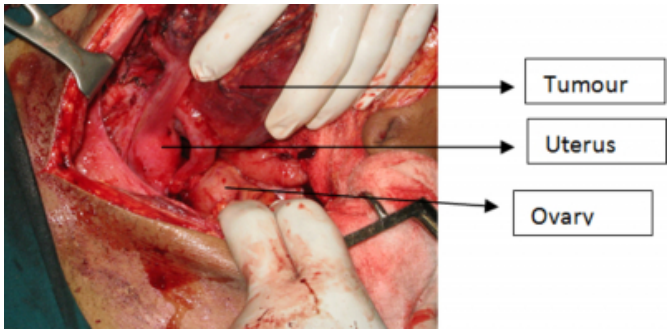

Histopathology examination revealed predominantly spindle shaped cells arranged in hyaline and myxoid stroma with infiltration of lymphoplasmacytic cells. There was no cellular anaplasia, suggestive of inflammatory myofibroblastic tumor or inflammatory pseudo-tumor (Fig-3 & 4).

Figure 3

Fig-3: Histopathology of tumor, predominantly spindle shaped cells with infiltration of lymphoplasmacytic cells (10 X)

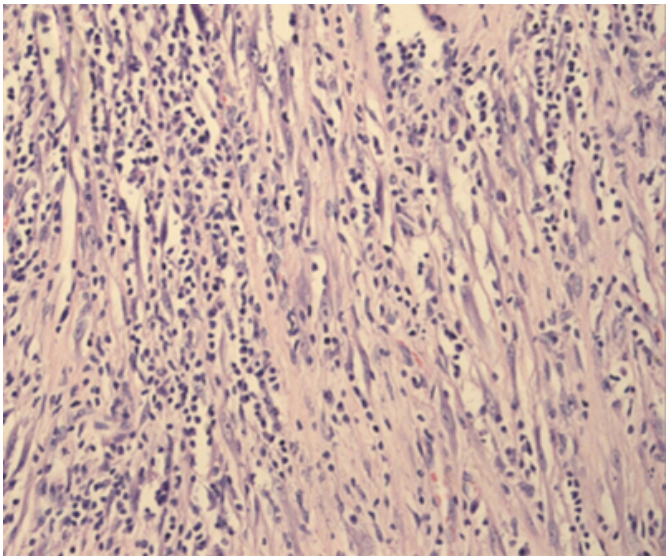

Figure 4

Fig 4: Histopathology of tumor (40 X)

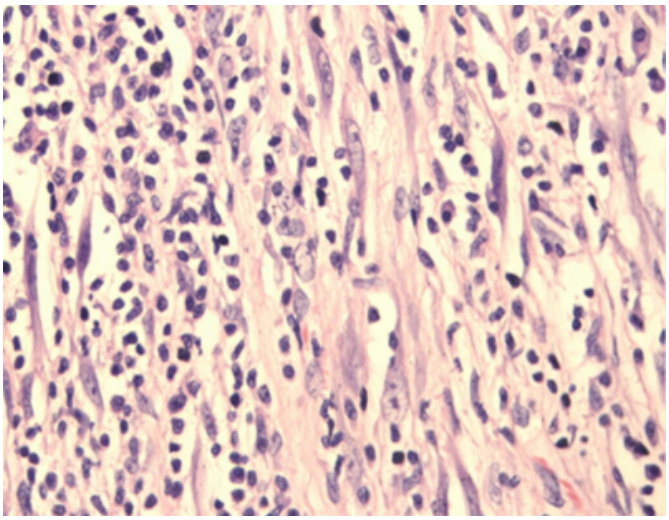

DISCUSSION

Inflammatory pseudo tumor is a non-neoplastic process characterized by unregulated growth of inflammatory cells. The cause of this inflammatory response remains unknown and various theories have attributed it to metabolic disturbance[3]. Uncertainty about the nature of this disease has caused it to be known by several names, including inflammatory pseudo-tumor, fibroxanthoma, or plasma cell-fibrohistiocytoma complex[4].

Umiker and Iverson prefers to include all these tumours under the designation of inflammatory pseudo-tumour since

morphologically these simulate a tumour and histologically these are composed of inflammatory cells and show complete maturity of fibroblastic component with striking lack of mitosis[3].

The etiology is unknown but likely explanation includes prior inflammatory or infectious etiology and possibly foreign body reactions. No causative agents evident in most cases as in our case[5].

The disease is most common in men in 4-5 decade of life. Most patient's presents with vague abdominal symptoms like dull or poorly localized flank pain, palpable mass/abdominal pain/weight loss and fever which initially suggest as a case of genital tuberculosis. A small proportion of patients have a syndrome of fever, weight loss, growth failure, malaise, anemia.[1]

Laboratory abnormalities are not of much help in making the diagnosis of inflammatory pseudo-tumor. Anemia, thrombocytosis, elevated erythrocyte sedimentation rate may be seen in some patients[6].

There is a considerable diversity in appearance of these tumors on CT scan. Most common is heterogeneous/peripheral enhancement. Variable calcification pattern have been described on CT-scan including punctate, dense, flocculent and curvilinear[7].

Our case was a 17 year old girl who presented with chief complaints of fever (evening rise of temperature), generalized weakness & loss of weight. This type of history and presentation is suggestive of tuberculosis which is very common in India. Ultrasound showed a mass arising from retroperitoneal region, both ovaries was normal. CT-scan findings were suggestive of paraganglioma/paraovarian cyst/Nerve sheath tumor/dysgerminoma. In view of these findings further management of the case was challenging. FNAC of the tumor was thought of, but because of its proximity to the vessels, exploratory laparotomy was performed with complete resection of the tumor. Part of the caecum was also excised along with the mass.

SUMMARY

Inflammatory pseudo-tumor is a rare entity in children. Proper pre-operative diagnosis in such cases is difficult to differentiate clinically as well as radiologically from other soft tissue tumors. Proper management can be achieved by adequate resection of the tumor along with the involved structures as it is known for its recurrence. Histopathological examination of the mass helps in diagnosing such conditions.

References

1. Asim Qureshi, Rafay Azhar, Qasim Ahmed. Intraabdominal mass: A diagnostic delimma. Indian J Pathology and Microbiology: 2009; 52(4): 582-583.
2. CoffinC M, Hornick JL, Flecher CD. Inflammatory myofibroblastic tumor: Comparison of clinicopathologic, histologic, and immunohistochemical features including ALK expression in atypical and aggressive cases. The Am J Surg Pathol: 2007; 31(4): 509-520
3. Patel SB, Shah DM, Goswami KG, Shah SR, Shah PM. Inflammatory pseudotumor of lung, a case report and review of literature. Indian J Radiol Imaging 2006; 16:117-120
4. Hiroshi Yokoyama, Haruki Kume, Aya Niimi, Kyoichi Tomota, Tadaichi Kitamura. Plasma cell granuloma of urethra in a young woman. American Journal of Obstetrics & Gynecology: 2007: e9-e10
5. Yagen Pratap A, Tiwari A, Agarwal B, Pandey SR, Paudel G, Kumar A. Inflammatory myofibroblastic tumor of the abdominal wall simulating rhabdomyosarcoma: report of a case. Surg Today 2007; 37(4):352-5
6. RS Singh, RS Dhaliwal, D Puri, D Behera, A Das. Inflammatory pseudotumor of the lung: Report of a case and review of literature. Indian J Chest Dis Allied Sci 2001; 43: 231-234
7. Coffin CM, Humphrey PA, Dehner LP. Extrapulmonary inflammatory myofibroblastic tumor: A clinical and pathological survey. Semin Diagn Pathol 1998; 15:85-101

Author Information

Sunanda Bharatnur
Assistant Professor, Department of OBGYN, KMC

Vani Ramkumar
Professor, Department of OBGYN, KMC

K. Natrajan
Professor, Department of Urology, KMC