

Glomangiomas: Are They Rare Tumours Or Rarely Diagnosed?

A Mathew

Citation

A Mathew. *Glomangiomas: Are They Rare Tumours Or Rarely Diagnosed?*. The Internet Journal of Hand Surgery. 2012 Volume 3 Number 2.

Abstract

Glomangiomas are rare tumours occurring mainly in the subungual region of the finger. The duration from time of onset of symptoms to surgery often extends to years. The condition is excruciatingly painful in this location and the patient would have consulted numerous physicians and surgeons prior to surgery. Evaluation of 7 patients with glomus tumours revealed an average duration of symptoms was 4.28 years (2 to 8 yrs). An average of 3.2 physicians and 1.6 surgeons had seen these patients. 2 patients were evaluated for cardiac disease due to radiation of pain from the finger tip to the chest. 2 patients were evaluated for cervical spine disease. The lack of obvious clinical signs and the absence of definitive findings in basic imaging studies make diagnosis difficult. A greater awareness among physicians, neurologists and cardiologists; and inclusion of the same in undergraduate-medicine teaching curriculum will go a long way in reducing the average time to diagnosis in this acutely painful condition.

INTRODUCTION

Glomangiomas also called glomus tumours, are hamartomas occurring in the stratum reticularis of the dermis. In the hand they account for one to five percent of all tumours[1]. The commonest location is the subungual area of the finger. This location and the rich network of sensory nerves within the tumour makes it excruciatingly painful. The classic triad of symptoms include paroxysmal pain, cold hypersensitivity, and pinpoint tenderness[2]. A bluish-red nodule or discolouration of the nail bed may be visualized under the nail plate. Some patients may present with nail plate abnormalities like ridging, deformity, splitting and some cases partial or total absence of the same. Often however no obvious abnormality is seen on inspection over the distal end of the digit especially if the tumour is located proximal to the nail fold, under the germinal matrix of the nail-bed or in the pulp of the digit. Careful palpation with a blunt tipped probe (pin-head or paper clip) will elicit pinpoint tenderness[3] in most cases (The Love's test). Cold hypersensitivity can be elicited in almost all cases of the patients when the finger is dipped in cold water. High resolution MRI will show a lesion with high signal intensity in T2-weighted spin-echo sequences with further enhancement with gadolinium [3]. Though a sensitive diagnostic modality, it is not specific. Radiographs may show scalloping of the involved phalanx under the nail

bed[4].

One of the characteristics of this tumour is the long duration of symptoms[3] at presentation. This may extend for years. Most patients would have visited numerous physicians and surgeons only to be treated symptomatically. Some of the patients present with an atypical radicular pain, radiating to the shoulder or chest from the digit following accidental contact of the involved area. Few of the patients are even evaluated for cardiac or neurologic disease prior to presentation to a hand surgeon.

MATERIALS AND METHODS

All patients who had presented with histology proven, glomangiomas over a four year period at the hospital were included in a cohort study. At admission all patients were questioned in detail regarding duration and type of symptoms, the number and type of practitioners visited in the past and any special tests undergone for the same. The patients were also asked about other medical illnesses, and regarding any long term medications prescribed for the same condition. All patients were requested to follow up after 6 months and one year after suture removal.

In the clinical evaluation of all patients the classic triad of symptoms including, paroxysmal pain, pin-point tenderness and cold hypersensitivity were elicited at admission. Details

of any atypical symptoms were also noted. Post operatively patients were specifically evaluated for any complications like recurrence, nail plate deformities, infection.

All procedures were done after standard written consent and the patients were warned about a ten to twenty percent of chance of recurrence prior to surgery. All patients received one dose of prophylactic antibiotic prior to surgery. The surgeries were done under digital block and tourniquet the next day after presentation Surgery was done through a trans-ungual approach in all cases of subungual tumours and direct incision over the pulp for volar tumours (figures 1,2).

Figure 1

Figure:1 A glomus tumour being surgically excised from a volar locations

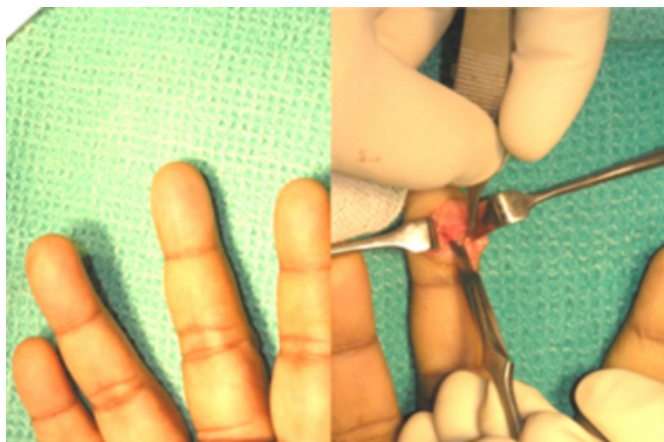
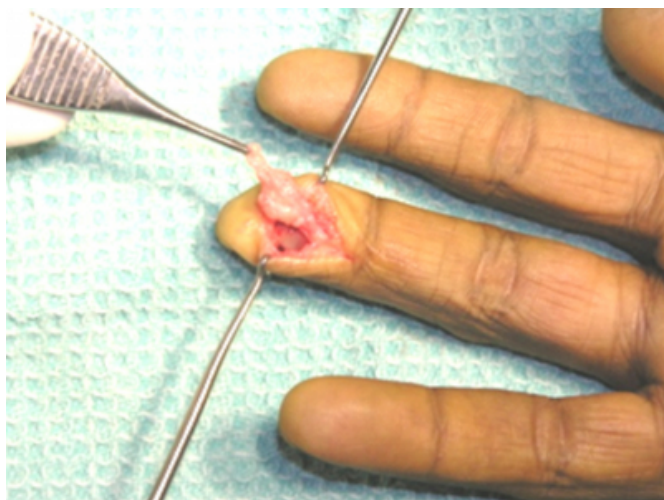


Figure 2

Figure:2 Another glomus tumour in the pulp of the left ring finger

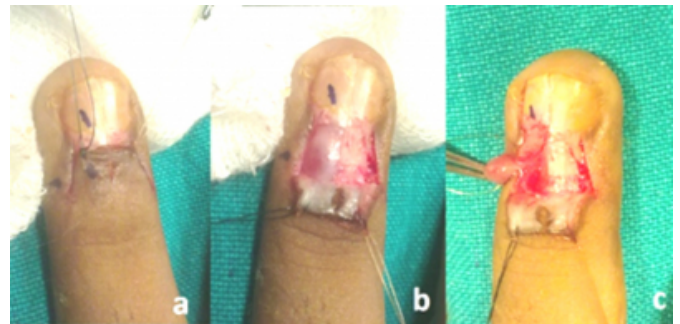


In sub-ungual tumours the nail plate was partially or totally removed and the dorsal nail fold reflected to reveal the

bluish-red discolouration of the tumour under the nail bed (Figure:3).

Figure 3

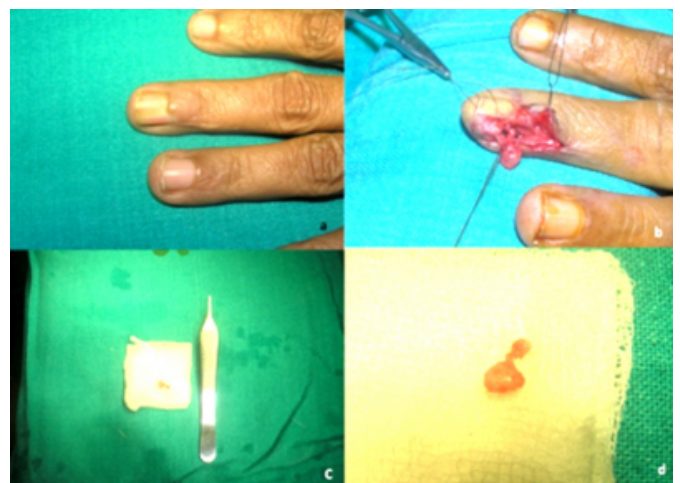
Figure: 3 a) Dorsal nail fold incisions, b) dorsal nail fold reflected and proximal nail plate excision revealing the bluish-red glomus tumour under the nail bed, c) the nail bed incised and the tumour excised with the pedicle.



The nail bed was then carefully incised and reflected to reveal the tumour. The tumour was carefully dissected to the pedicle containing the nerve and afferent vessel. The lesion was removed by cauterizing the pedicle and separating it from the bed in all cases (figure: 4).

Figure 4

Figure: 4 a) nail plate ridging noted preoperatively, b) partial nail plate removal, nail bed incision and dissection of the tumour to the pedicle, c) excised specimen palpated on a 6cm square gauze and against a 12.5 cm Adson's forceps, d) close up of the specimen



All patients requiring the trans-ungual approach had their nail beds repaired with 5-0 vicryl. The nail-plate was re-inserted into the nail fold after washing and scrapping of any remnant soft-tissue on its deep surface or a nail spacer was used to prevent adhesions between the dorsal and ventral nail folds. The spacer was removed after one week and any

nail fold or skin sutures if present were removed on the tenth post operative day. All tissue biopsy samples were sent for histo-pathology examination. The biopsy reports were available within three days of the surgery.

RESULTS

7 patients with glomangiomas in the finger tip presented to the hand unit of the hospital over the last four years. 5 patients were females, average age 43.4 yrs (37 to 50yrs); and two males (35, 59 yrs). The average duration of symptoms were 4.28yrs (2 to 8 years). All patients had sought medical advice prior to presentation having met a median of 5 practitioners not including the numerous visits to each one prior to definitive surgery. Details of visits to specialists and practitioners are summarised in table 1.

Figure 5

Table:1 Patient profiles with duration of symptoms of glomangioma and the number of specialists consulted prior to presentation. Approximate number of visits are mentioned in brackets. * denotes the referring doctor. This is excluding the number of alternate medicine practitioners seen by the patients.

Patient	Age	Sex	Duration of symptoms	Type & number of doctors visited by the patient, Approximate number of visits (in brackets)					
				Physician	Gen. surgeon	Cardiologist	Neurologist	Orthopaed c surgeon	Total
1	37	F	3yrs	3(4)	1(3)			1(1)*	5 (8)
2	50	F	5yrs	4(8)	2(4)			1(1)	7 (13)
3	47	F	8yrs	6(10)	2(2)*		1(3)		9 (12)
4	41	F	7yrs	4(9)	1(3)		1(2)*	1(1)	7 (15)
5	35	M	2yrs	2(4)	2(3)	1(2)*			5 (9)
6	42	F	3yrs	2(3)		1(3)*		1(2)	4 (8)
7	59	M	2yrs	1(2)*					1 (2)

Symptom profiles of all patients are summarized in table: 2. Two patients were evaluated by cardiologists for atypical chest or shoulder pain. Both of these patients had Holter and treadmill tests done which were found to be normal. Two patients were evaluated by neurologists for cervical spine disease for atypical radicular pain. Five patients in addition were seen by general surgeons prior to surgery. Two patients were on tri-cyclic antidepressants for pain modification and one on gabapentine. Only two patients in the group were diabetic, both had good sugar control while three patients were hypertensives on treatment. The male patients included a manual labourer and a retired line-man. Among the women, four patients were professionals and one a home maker. Four patients felt that the symptoms hampered their activities at work and daily living.

Figure 6

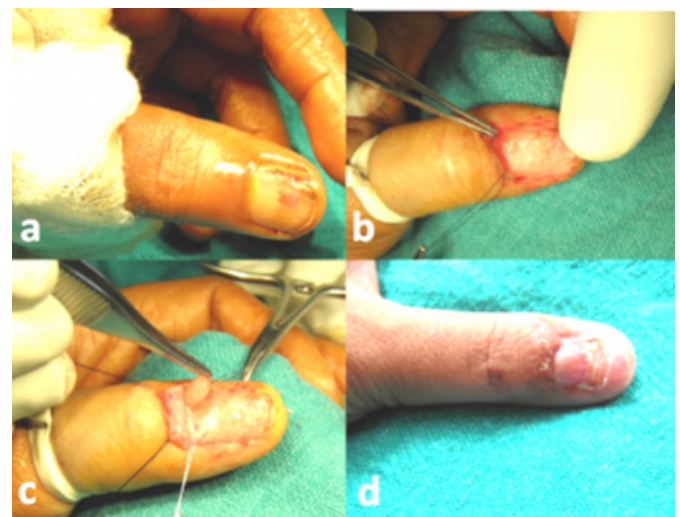
Table:2 Symptom profile of all patients. (* S- radiation to shoulder; C- radiation to chest)

Patient	Clinical features in each patient, (*+ = present, *+ = absent)				
	Episodic pain	Cold hypersensitivity	Local tenderness	Radiation of pain (- /S/C)*	Sleep deprivation
1	+	+	+	-	-
2	+	+	+	-	-
3	-	+	+	S	-
4	+	+	+	S	-
5	+	+	+	C	-
6	+	-	+	C	+
7	-	+	+	-	-

Two tumours were located in the pulp while the rest were sub-ungual in location. One patient presented with a nail plate ridging (figure: 4), while another had a split nail (figure: 5). All other subungual tumours had no nail-plate abnormality at presentation. All tumours were confirmed glomangiomas after histo-pathological examination. One of them was of the mucoid variety. All others were of the solid type[1]. No angiomatous type of glomangiomas was seen in this series.

Figure 7

Figure: 5 a) Split nail presentation of a glomus tumour in the thumb, b) nail plate removal, c) surgical excision of the tumour, d) 4 month follow up of the same patient revealing normal nail formation.



All patients had complete relief of symptoms post operatively. One patient developed minor superficial infection under the sutured nail fold which was treated with suture removal and a short course of antibiotics. One patients had persistent ridging of the nail 4 months after surgery. No patient required any long term pain or pain modifying medication after the surgery.

DISCUSSION

The dramatic relief offered by surgery in this condition is heart warming. The unfortunate duration of symptoms till definitive diagnosis, is the most anguishing aspect for most patients. In this series only five out of forty practitioners or specialists were able to diagnose this condition and refer the patients for surgical management. Each patient had made an average of 10.5 visits to medical centres before definitive surgical treatment. Although the pain is severe diagnosis is not readily made[5,6]. In the authors' practice over four years at a hand centre the last two cases presented over the last one year after a presentation of the problem was made at local doctor's association. Both the cases were correctly diagnosed by the next physician or specialist who saw those patients and referred them to the hand centre for further treatment. Most patients had the classic triad of episodic pain, cold hypersensitivity and pin point tenderness. These seven cases accounted for eleven percent of all hand tumours done at this hand centre, although other studies at large

volume hand centres put the same as 1 to 5%[1,6]. The inclusion of this tumour in the under-graduate teaching curriculum and awareness of this problem among physicians, cardiologists and neurologists alike will go a long way in shortening the time to diagnosis and offering an early cure for this excruciatingly painful and rarely diagnosed condition.

References

1. Tuncali D, Yilmaz AC, Terzioğlu A, Aslan G. Multiple occurrences of different histological type of the glomus tumor. *J Hand Surg*; 2005;30A:161-4
2. Gandhi J, Yang SS, Hurd J. The anatomical location of digital glomus tumor recurrences. *J Hand Surg*; 2010;35A:986-9
3. McDermott EM, Weiss AC. Glomus tumors. *J Hand Surg*; 2006;31A:1397-1400
4. Noor MA, Masbah O. Synchronous glomus tumors in a distal digit a case report. *J Hand Surg*; 1997; 22A:508-10
5. Posch JL. Tumors of the Hand. *J Bone Joint Surg Am*; 1956;38:517-62.
6. Carroll RE, Berman AT. Glomus tumors of the hand: review of the literature and report on twenty-eight cases. *J Bone Joint Surg Am*; 1972;54:691-703

Author Information

Anil Mathew

Hand And Orthopaedic Surgeon, Medical Mission Hospital