

# Recent Development Of Five Column Paddle Spinal Cord Electrode Used For Intractable Pain After Traumatic Lumbar Spine Injury.

T Szmuda, W Olijewski, P Sloniewski, J Dzierzanowski

---

## Citation

T Szmuda, W Olijewski, P Sloniewski, J Dzierzanowski. *Recent Development Of Five Column Paddle Spinal Cord Electrode Used For Intractable Pain After Traumatic Lumbar Spine Injury.*. The Internet Journal of Neurosurgery. 2012 Volume 8 Number 1.

## Abstract

Treatment of chronic low back pain (LBP) after lumbar spine trauma is challenging. Despite fixation of the fractured spine, chronic pain afflicts most of these patients. Spinal cord stimulation (SCS) is a treatment option with an unsatisfactory success rate for low back pain [1], which is attributed to inadequate coverage of painful area [2]. The configuration of the transverse tri-polar lead might have resulted with deeper penetration of the dorsal columns stimulation, resulting in improvement of low back paresthesia coverage [3]. Struijk [4] illustrated that transverse system might be effective in a theoretical model, which results of clinical study have confirmed [5]. However, the innovation of five column electrode, that has the broadest lateral electrode span of stimulation, may provide better pain reduction control.

In this paper, the authors present the first report on five-column, paddle electrode (St. Jude Medical Neuromodulation Division, Plano, TX) implanted via thoracic foraminotomy, to achieve paresthesia of the lower back region, in a patient after lumbar spine injury.

## INTRODUCTION

Treatment of chronic low back pain (LBP) after lumbar spine trauma is challenging. Despite fixation of the fractured spine, chronic pain afflicts most of these patients. Spinal cord stimulation (SCS) is a treatment option with an unsatisfactory success rate for low back pain [1], which is attributed to inadequate coverage of painful area [2]. The configuration of the transverse tri-polar lead might have resulted with deeper penetration of the dorsal columns stimulation, resulting in improvement of low back paresthesia coverage [3]. Struijk [4] illustrated that transverse system might be effective in a theoretical model, which results of clinical study have confirmed [5]. However, the innovation of five column electrode, that has the broadest lateral electrode span of stimulation, may provide better pain reduction control.

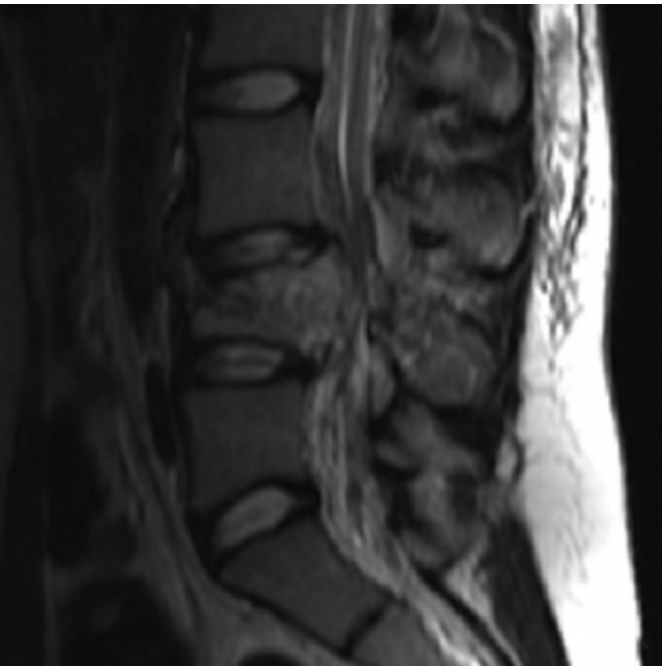In this paper, the authors present the first report on five-column, paddle electrode (St. Jude Medical Neuromodulation Division, Plano, TX) implanted via thoracic foraminotomy, to achieve paresthesia of the lower back region, in a patient after lumbar spine injury.

## CASE REPORT

A 23-year-old woman was referred to our Neurosurgery Outpatient Department due to LBP and neuropathic radical pain in both legs. In 2007 year the patient sustained a car accident injury of lumbar spine region, resulting in "burst fracture" of L4 vertebral body. (Figure 1)

**Figure 1**

Figure 1: T2 MRI sagittal projection of lumbosacral spine. “Burst fracture” of L4 vertebral body.

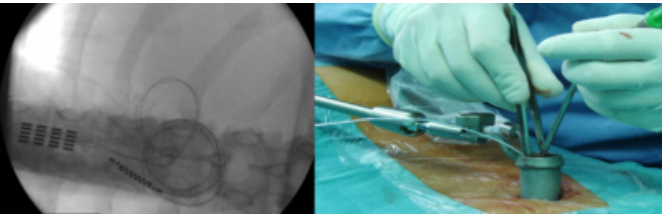


Right foot flexion and incontinence was the only neurological deficit preoperatively. Decompressive L4 laminectomy with L3-L5 fixation was performed on the day of injury. However, four years after rehabilitation neurological deficits were not recovered, the main problem for the patient was intractable LBP (VAS 7/10) and in both lower extremities, burning neuropathic pain (VAS 8/10). The quality of life (QOL) was remarkably decreased (SF-36=11), especially with regards to the patients physical health (PCS=9). The psychological examination revealed the patient’s positive expectations for SCS with no signs of depression.

The epidural implantation of Penta® lead (St. Jude Medical Neuromodulation Division, Plano, TX) was performed in general anesthesia through Th9/Th10 left fenestration in minimal invasive surgery (MIS) via Spotlight™ tubular retractor (DePuy Spine, Raynham, MA, USA). (Figure 2)

**Figure 2**

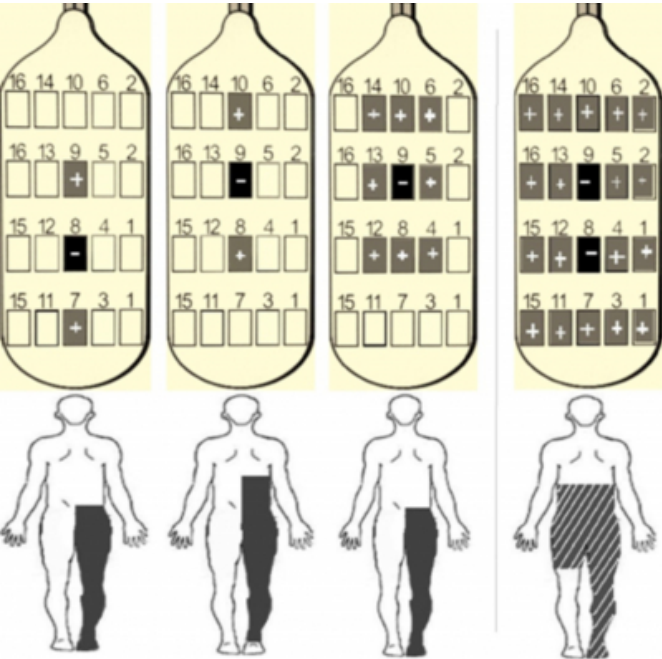
Figure 2: Intraoperative radiogram of implanted Penta® lead (left) and its placement via Spotlight™ tubular retractor (right).



During the same operation, a subcutaneous pocket in the left subabdominal area was prepared for pulse generator (IPG) and the electrode was connected with an implanted IPG. There were no intraoperative and postoperative complications related to procedure. Different contact combination was tested with standard settings of SCS: pulse width (PW) = 350µs, rate = 320Hz and amplitude ranged from 3.7 to 6.1 mA. A single central cathode placement or use of tripolar stimulation did not cover lower back area at all. Stimulating all of five columns’ electrodes, with central cathodes location, achieved an approximately 85% paresthesia coverage. However low back region was covered, left lower leg was not included. (Figure 3)

**Figure 3**

Figure 3: Stimulation patterns (stimsets) and regions of paresthesia with five-column electrode. The right pattern covered targeted low back area and right lower extremity.

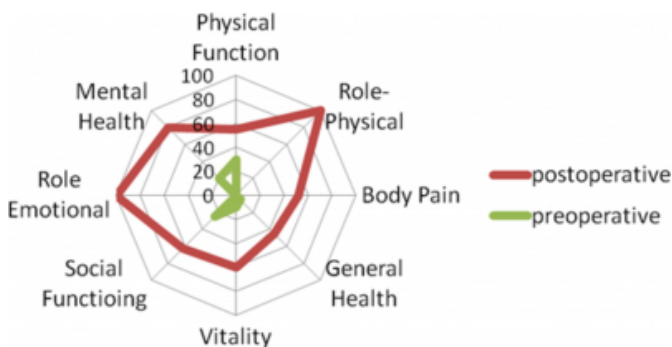

Short term (one month) follow-up was assessed. Comparing

with the baseline, 28.6% pain reduction in low back region and 37.5% in lower extremities was recorded. For all QOL scales an improvement has been recorded. PCS score changed from 9 preoperatively to 62 postoperatively and MCS score from 12 to 70. (Figure 4)

**Figure 4**

Figure 4: Radar plot comparing preoperative with postoperative QOL component scores (SF-36 scale).



## DISCUSSION

The use of neuromodulation in pain treatment is one of the fastest growing areas of medicine [6]. Greater efficacy of SCS in reducing neuropathic radical pain than axial pain is known [1,5]. The main drawback of this treatment is poor coverage of axial region [7], which is the key in successful neuromodulation [8]. The use of transverse tripolar stimulation [4,5], or addition of peripheral nerve field stimulation to SCS [7] provide better pain relief. However, remarkable technical advances were described, SCS is still not considered effective treatment in LBP. Moreover, covering large painful areas, like the lumbar region and both legs, is challenging for single electrode stimulation [1,7]. The use of the innovative five-column lead, with greater paresthesia coverage, is aimed to improve the results [8] so far confirmed by Marquez's initial and unpublished report of twelve cases [9]. He achieved 100% of successful axial coverage, unfortunately patient outcome was not provided. In our case study pain reduction as well as QOL improved remarkably after five-column lead stimulation. The results are preliminary, but promising. The future objective is to investigate whether new surgical leads supply more steerable paresthesias and better pain relief [9]. Moreover, technical and theoretical advantages of five-column leads should be investigated in larger group of patients.

Another favourable feature of Penta® lead is its relatively small size, 46 mm length and 11 mm width. These dimensions allow the implantation of surgical lead by MIS,

which was presented herein. Assuming that the MIS technique not only shortens the incision length, but causes less soft tissue and bone injury, applying MIS in SCS has solid justification [10]. Beems [11] described the use of tubular retractor (METRx®, Medtronic Sofamor Danek, Minneapolis, MN) to approach the thoracic spine for surgical lead placement. He considers this method in case of epidural adhesions, previous lead migrations and failure to cover the painful area adequately via a single, percutaneous lead. Herein we used Spotlight™ tubular retractor that has a great advantage over METRx®. Integrated light source at the distal end eliminates shadows in the working space. Presented novel application of Spotlight™ Access System in surgical SCS lead placement has not been reported yet.

There is no consensus about efficacy of trial stimulation before permanent implantation of pulse generator [12]. However, trials are commonly used in most reports, at least two authors performed one-step procedure [13]. We share the opinion that patients are unable to make a decision about efficacy of SCS in accordance with such short trial periods. Moreover, two-step procedure is related to higher risk of surgical site infection [12,13].

However, the first preliminary European multicenter experience [9] are promising, prospective randomized trial comparing Penta® with standard lead should be performed.

## CONCLUSION

In patients with intractable LBP and radicular pain the use of SCS with the five-column electrode has the potential to develop into a treatment of choice method. Widespread paresthesia coverage, analgesic effect and improvement of QOL are encouraging. Presented cases and unpublished data indicate that long-term follow-up need verification by further randomized analyses.

## References

1. Buvanendran A, Lubenow TJ: Efficacy of transverse tripolar spinal cord stimulator for the relief of chronic low back pain from failed back surgery. *Pain Physician*; 2008; 11:333-338.
2. Barolat G, Massaro F, He J, Zeme S, Ketcik B. Mapping of sensory response to epidural stimulation of the intraspinal neural structures in man. *J Neurosurg*; 1993; 78:233-239.
3. Holsheimer J. Effectiveness of spinal cord stimulation in the management of chronic pain: analysis of technical drawbacks and solutions. *Neurosurgery*; 1997; 40:990-999.
4. Struijk JJ, Holsheimer J. Transverse tripolar spinal cord stimulation: Theoretical performance of a dual channel system. *Med Biol Eng Comput*; 1996; 34:273-279.
5. Oakley, J.C., Espinosa, F., Bothe, H., McKean, J., Allen, P., Burchiel, K., Quartey, G., Holsheimer, J. Transverse

tripolar spinal cord stimulation: Results of an international multicenter study. *Neuromodulation*; 2006; 93:192-203.

6. Mathew R. Five column paddle leads – early clinical experience in the UK. 10th World Congress of the International Neuromodulation Society; 2011; London.

7. Mironer YE, Hutcheson JK, Satterthwaite JR, LaTourette PC. Prospective, two-part study of the interaction between spinal cord stimulation and peripheral nerve field stimulation in patients with low back pain: Development of a new spinal-peripheral neurostimulation method. *Neuromodulation*; 2011; 14:151-154.

8. van Havenbergh T, Marquez J, Wahlstedt A, Lenders M, Blond S, Schu S, Sulkko K, Vonnhogen L, Timothy J, Riethmann T. Paresthesia coverage with a five column paddle lead – first European multicenter experience. 10th World Congress of the International Neuromodulation Society; 2011; London.

9. Marquez J, Wahlstedt A, Lenders M, Blond S, Schu S, Sulkko K, van Havenbergh T, Vonnhogen LH, Timothy J.

Capture of the physiological midline with a five column paddle lead – first European multicenter experience. 10th World Congress of the International Neuromodulation Society; 2011; London.

10. Johnson MR, Tomes DJ, Treves JS, Leibrock LG. Minimally invasive implantation of epidural spinal cord neurostimulator electrodes by using a tubular retractor system. Technical note. *J Neurosurg*; 2004; 100:1119-1121.

11. Beems T, van Dongen RT. Use of a tubular retractor system as a minimally invasive technique for epidural plate electrode placement under local anesthesia for spinal cord stimulation: technical note. *Neurosurgery*; 2006; 58(1 Suppl):ONS-E177.

12. Gofeld M, Cohen E, Niv D. New approach for spinal cord stimulation trial. *Pain Pract*; 2005; 5:324-326.

13. Kumar K, Toth C, Nath RK, Laing P. Epidural spinal cord stimulation for treatment of chronic pain - some predictors of success. A 15-year experience. *Surg Neurol*; 1998; 50:110-120.

**Author Information**

**Tomasz Szmuda**

Neurosurgery Department, Medical University of Gdansk

**Wiktor Olijewski**

Neurosurgery Department, Medical University of Gdansk

**Pawel Sloniewski**

Neurosurgery Department, Medical University of Gdansk

**Jaroslawn Dzierzanowski**

Neurosurgery Department, Medical University of Gdansk