

Adenocarcinoma Of The Rete Testis With Secondaries In The Skin – Review Of Literature And Case Report

A Pai, H Ram, T Sarkar, S Bhat, A Mohammed

Citation

A Pai, H Ram, T Sarkar, S Bhat, A Mohammed. *Adenocarcinoma Of The Rete Testis With Secondaries In The Skin – Review Of Literature And Case Report*. The Internet Journal of Oncology. 2012 Volume 8 Number 2.

Abstract

Adenocarcinoma of the rete testis is a rare tumour with a varied presentation. A total of 44 cases have been reported [1]. Of these testicular tumours, primary non germ cell tumours account for a minority of cases. Among this, adenocarcinoma originating in the rete testis is still rarer. It is a highly malignant tumour with poor prognosis. It is generally diagnosed clinically as a solid or cystic swelling. However, confirmation is made only on histological diagnosis.

INTRODUCTION

It is a highly malignant tumour with poor prognosis. It is generally diagnosed clinically as a solid or cystic swelling. However, confirmation is made only on

histological diagnosis.

The diagnostic criteria of Noehomovitz for adenocarcinoma rete testis include:-

CASE REPORT

A 75 year old man presented with painless swelling in the left side of the scrotum of 20 days duration. There was history of blunt trauma during a fall. It was hard, proximal to the left testis of 5X5 cm in size, non fluctuant, and

non transilluminant. The overlying skin was free. A diagnosis of chronic haematocoele was made.

Ultrasound of the abdomen was normal. Blood parameters were normal. The patient was taken up for surgery and the left sided scrotum was explored. Blood mixed fluid with necrotic material was found. Left sided orchidectomy was done. A drain was placed and wound was closed.

Histology revealed features of adenocarcinoma of rete testis.

The patient was advised with further treatment which he refused. After one month the patient presented with multiple cutaneous swellings which were hard, nontender over the forearm and abdominal wall.

Biopsy of forearm cutaneous secondaries was done –

histology confirmed cutaneous adenocarcinoma secondaries.

Figure 1

Figure 1 Pre operative picture of the Scrotum

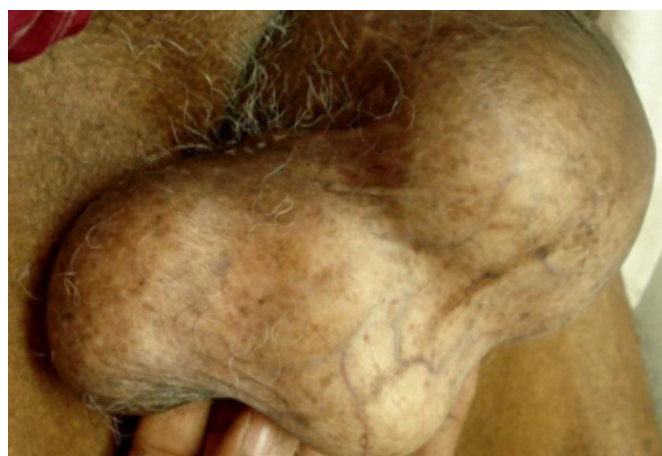

Figure 2

Figure 2 Incision

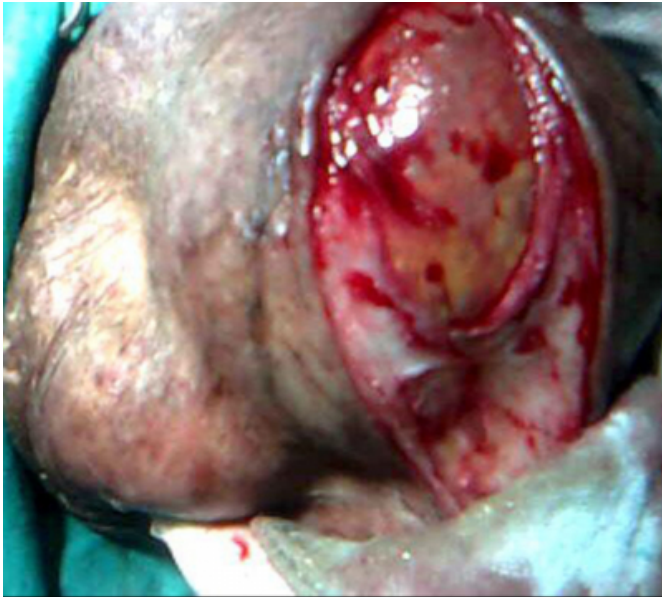

Figure 3

Figure 3 Intraoperative picture of the tumor

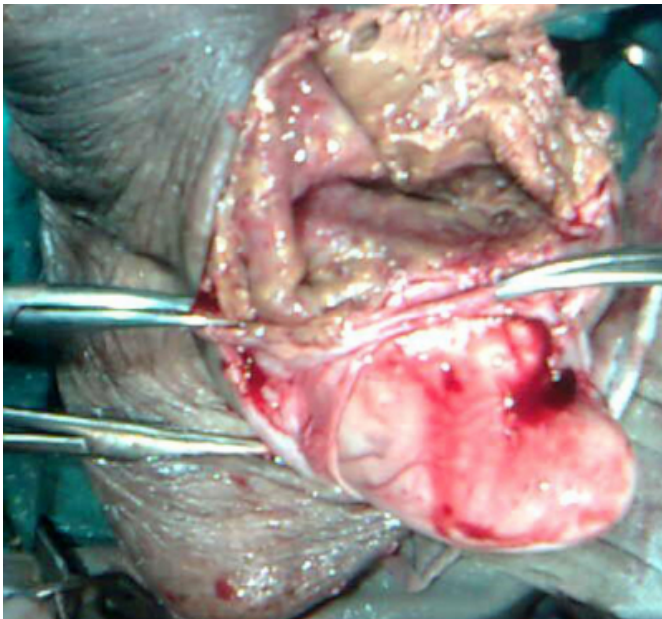


Figure 4

Figure 4 Microscopy of adenocarcinoma of rete testis

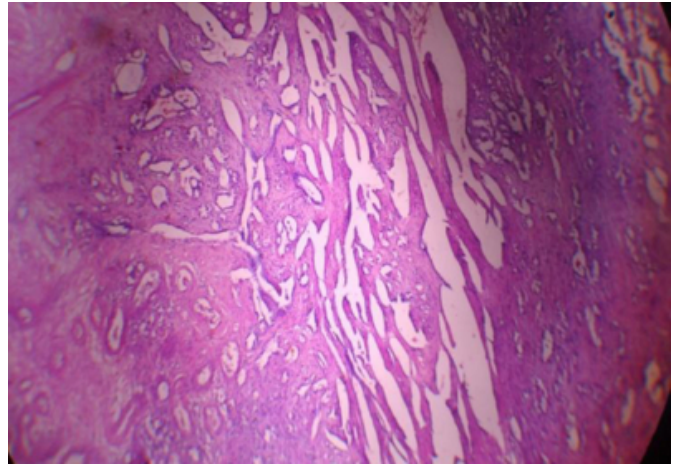
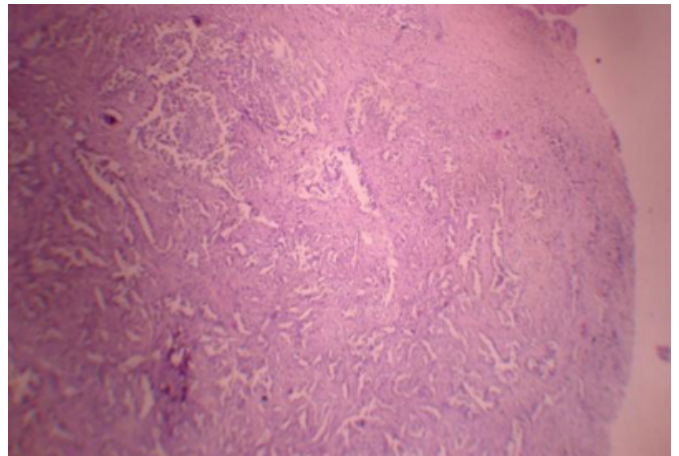


Figure 5

Figure 5 Microscopy of the Skin Metastasis



DISCUSSION

Carcinoma of the rete testis is a rare tumour, occurring most commonly in the fourth and fifth decades of life.

However, patients may range from 20 to 80 years of age. A total of 44 cases have been reported, three of the ,youngest cases (ages 20 yrs, 21 yrs, and 34 yrs) had a prior history of undescended testis[4-6]. The carcinoma can affect either side, and occasionally may be bilateral. All races are equally affected. Carcinoma of the rete testis has usual association with hydrocele,epididymitis, inguinal hernia and occasionally, with undescended testis.

The tumour is confirmed only on histological diagnosis, which is governed by the Noehomovitz criteria. This includes:

On gross examination, the tumour may show a solid, nodular or cystic surface.

Microscopically, there are three patterns. The papillary pattern, which is commonest, represents glomeruli with numerous microvilli projecting into cystic spaces. The rete epithelium shows deep narrow nuclear invaginations, apparent nuclear lobulations, and small pleomorphic electron-dense membrane-bound granules in the basal cytoplasm, and lipid droplets in the apical cytoplasm and bulbous cytoplasmic projections along the apical surface cells. The glandular pattern consists of moderately- to poorly-differentiated glands. Solid pattern shows irregular arrangement of cells along with greater cellular and nuclear pleomorphism.

The differential diagnoses include malignant mesothelioma of the tunica, serous Mullerian tumours of the testis, and Sertoli cell tumours [7].

Adenocarcinoma of the rete testis is an aggressive malignant neoplasm.

The treatment is primarily surgery (high inguinal orchidectomy) [8]. Radical orchidectomy, retroperitoneal lymph node dissection, radiotherapy and chemotherapy have been tried alone or in combination, with no fruitful results.

The stage at diagnosis or any form of therapy has no influence on final outcome, and prognosis remains poor. Patients seldom survive longer than one year, although survival rates up to five years without metastasis have been reported.

Careful follow-up is advisable.

References

1. Menon PK, Vasudevarao, Sabhiki A, et al. (2002) A case of carcinoma rete testis. *Indian J Cancer*; 39:106-11.
2. Nochomovitz LE, Orenstein JM. (1984) Adenocarcinoma of the rete testis. Case report, ultrastructural observations, and clinicopathologic correlates. *Am J Surg Pathol*; 8:625-34.
3. Young RH, Scully RE. (1986) Miscellaneous neoplasm and nonneoplastic lesions. In: Talerman A, Roth LM, eds. *Pathology of the testis and its adenexa*. New York: Churchill Livingstone: 93-129.
4. Dundon C. (1952) Carcinoma of the rete testis occurring ten years after orchidopexy. *Br J Urol*; 24:58-63.
5. Shillitoe AJ. (1952) Carcinoma of the rete testis. *J Pathol Bacteriol*; 64:650-1.
6. Jacobetlis U, Ricco R, Ruotolo G. (1981) Adenocarcinoma of the rete testis 21 years after orchiopexy: case report and review of literature. *J Urol*; 125:429-31.
7. Young RH, Scully RE. (1986) Testicular and paratesticular tumors and tumor-like lesions of ovarian common epithelial and müllerian types. A report of four cases and review of the literature. *Am J Clin Pathol*; 86:146-52.
8. Fukunaga M, Aizawa S, Furusato M, Akasaka Y, Machida T. (1982) Papillary adenocarcinoma of the rete testis: a case report. *Cancer*; 50:134-8

Author Information

Ashwin Pai, MS(Sur) MRCS (Edin) FAGE

Asst Prof of Surgery, Manipal University

Hs Shankar Ram, MBBS

Post Graduate Student Of Surgery, Manipal University

T Sarkar, Mch

Assoc Prof Of Plastic Surgery, IPGMER

Sriram Bhat, MS (Surg)

Professor of Surgery, Manipal University

Ashfaque Mohammed, DNB (Surg)

Associate Professor of Surgery, Manipal University