

Extranasopharyngeal Angiofibroma Of The Cartilaginous Nasal Septum: Possible Origin From Ectopic Tissue Trapped During Septal Development

J Madana, D Yolmo, S Gopalakrishnan, S Saxena

Citation

J Madana, D Yolmo, S Gopalakrishnan, S Saxena. *Extranasopharyngeal Angiofibroma Of The Cartilaginous Nasal Septum: Possible Origin From Ectopic Tissue Trapped During Septal Development*. The Internet Journal of Otorhinolaryngology. 2012 Volume 14 Number 1.

Abstract

Angiofibroma of the head and neck are benign non-encapsulated lesions occurring predominantly in nasopharynx in adolescent males, accounting for 0.5% of all head and neck neoplasms. The usual site of origin of this neoplasm is in the region of the sphenopalatine foramen. They may occur outside the nasopharynx (termed extranasopharyngeal angiofibroma) and can often be misdiagnosed. This lesion differs from that of the classical nasopharyngeal variety in being more common in females, older individuals, with early presentation, poor vascularity and infrequent recurrence. Even though maxillary sinus is the most common site for the origin of this lesion, angiofibroma arising from the nasal septum is extremely rare. It may be mistaken for bleeding polypus septum and the lesion poses a great diagnostic challenge requiring a high index of suspicion. We report a case of 37-year old female with four months history of a bleeding right nasal mass originating from antero-inferior septum. The patient was misdiagnosed as a case of bleeding polypus septum clinically and surgical excision was performed. Histopathological examination and immunohistochemistry of the specimen established the diagnosis of angiofibroma. Thus, extranasopharyngeal angiofibroma should be considered in the differential diagnosis of bleeding anterior nasal masses in females and older individuals and the likely theory of origin is discussed.

INTRODUCTION

An angiofibroma is a benign, aggressive and highly vascular tumour commonly arising from nasopharynx (NA) in adolescent males; however it has also been reported in females.^{1,2} Angiofibroma outside nasopharynx behave differently from that of nasopharyngeal type in its clinical behavior and pathologic characteristics and hence it should be regarded as separate entity.¹ Extranasopharyngeal angiofibroma (ENA) arising from nasal septum is extremely rare.^{1,3} In comparison to NA, the ENA lesion is diagnosed earlier and is less vascularised. The patients are usually older and more female adults are affected.⁴ Herein a case is reported of angiofibroma in 37 year old female, originating from antero-inferior part of cartilaginous nasal septum mimicking bleeding polypus septum and the likely theory of origin is discussed.

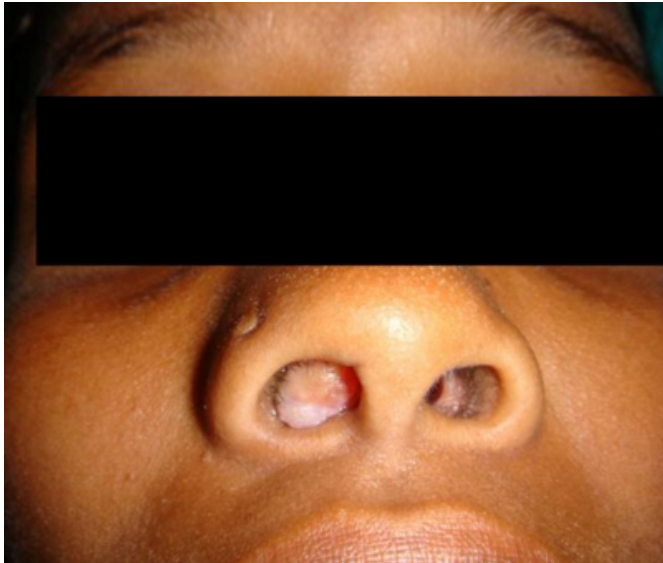bleeding diathesis, trauma, or infection. Anterior rhinoscopy revealed a smooth pinkish, pedunculated, mass originating from the antero-inferior part of cartilaginous septum filling the right nasal cavity (Figure 1), while posterior rhinoscopy showed no mass.

CASE REPORT

A 37 year old female patient presented with a bleeding mass and slowly progressive nasal obstruction in the right nasal cavity of 4 months duration. There was no history of

Figure 1

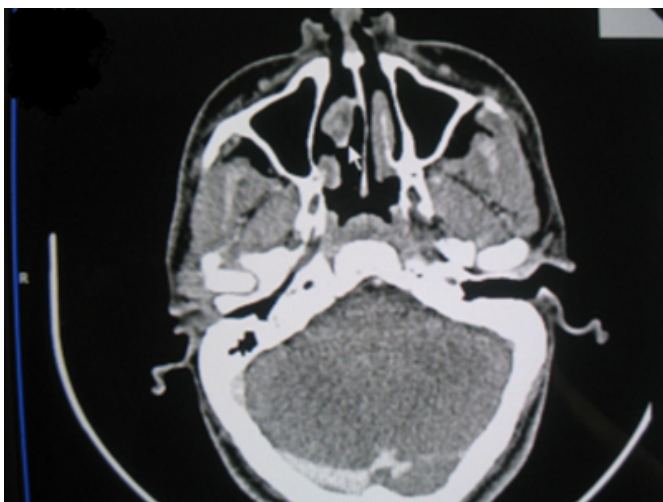Figure 1: Clinical photograph showing pinkish pedunculated mass in right nasal cavity



There was no cervical adenopathy. Computerized tomography of the nose and paranasal sinuses revealed a contrast enhancing homogenous soft tissue opacity involving the anterior one third of right nasal cavity arising from the cartilaginous septum (Figure 2) without any extension to paranasal sinuses or nasopharynx.

Figure 2

Figure 2: Computerized tomography of the nose and paranasal sinuses reveals a homogenous soft tissue opacity involving the anterior one third of right nasal cavity.



A provisional clinical diagnosis of bleeding polypus septum was made. The mass was excised via the nasal cavity under general anesthesia. It was found to be attached to the anteroinferior part of the cartilaginous septum.

Intraoperative blood loss was about 25 ml, and diathermy was used judiciously. The mass was pale pinkish in color and firm in consistency. Anterior nasal packing was done with acriflavin and liquid paraffin soaked gauze, which was removed after 24 hours. The excised mass measured 4x 3 x 2 cm (Figure 3) was sent for histopathological examination which revealed large, thin walled sinusoidal vessels lined by flattened epithelium, unsupported by the muscular coat abounding in a stroma of fibrous tissue (Figure 4).

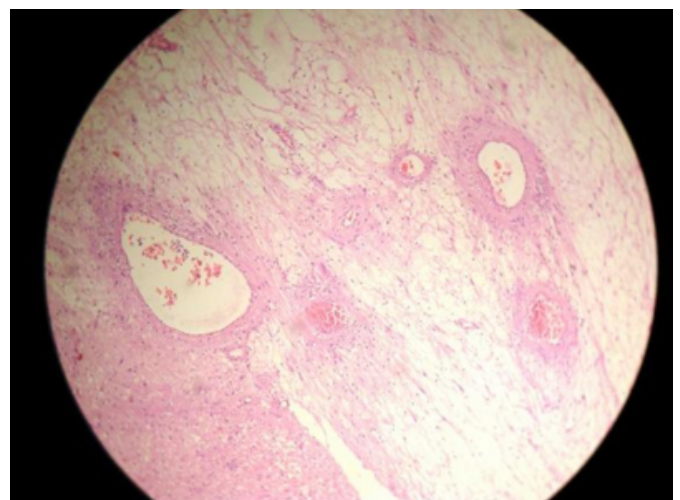
Figure 3

Figure 3: Post-operative septal angiofibroma specimen showing a pedicle

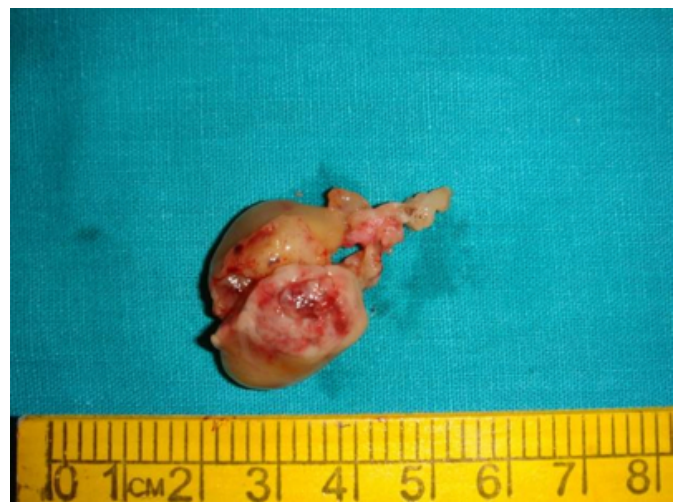

Figure 4

Figure 4: Histopathologic section shows abundant connective tissue stroma with interspersed endothelial lined vascular channels (Haemotoxylin and Eosin stain, 40x).



Immunohistochemical analysis was performed in which the stromal and vascular cells appeared to be strongly

immunoreactive to Vimentin and CD34 respectively, while staining for smooth muscle actin was occasionally positive. Staining for desmin was negative. Few cells were also immunoreactive to Ki-67 which indicated a lower rate of cellular proliferation. These features confirmed the diagnosis of angiofibroma. Postoperative follow up of the patient for 22 months revealed no recurrence.

DISCUSSION

Nasopharyngeal angiofibromas (NAs) have been reported since ancient times when Hippocrates (470-410 BC) excised the “hard nasal polyp” via a midline nasal-splitting incision. In 1841, Liston at the University College Hospital in London is to be credited for the first successful surgical treatment (total maxillectomy) for NAs. The term “juvenile NA” was first coined by Chauveau in 1906.⁴ Angiofibroma of nasopharynx usually conforms to the specific clinical characteristics with respect to age, sex and site.^{1,5} The average age of presentation is estimated to be 14-17 years. The recent literature indicates that NAs originate at the sphenopalatine

foramen, at the junction of the sphenoid process of the palatine bone and the horizontal ala of the vomer and at the root of the pterygoid process of the sphenoid at the posterolateral wall of the nasal cavity, near the superior margin of the sphenopalatine foramen. Clinical symptoms include nasal obstruction; recurrent nasal bleeding; purulent rhinorrhea; progressive deformity of the nasal septum, sinuses, palate and/or face and nasal speech. A pinkish or bluish nodular mass bulging into the nasopharynx is the typing finding on examination. In most cases, radiographic studies will demonstrate a widening of the pterygopalatine fossa and anterior bowing of the posterior wall of maxilla. De Vincentiis and Pinelli (1980) reviewed 704 cases of angiofibroma, of which 13 cases occurred outside the nasopharynx, indicating that extranasopharyngeal angiofibromas (ENAs) have to be considered as an extremely rare finding.⁴

ENAs do not follow clinical and pathological characteristics of NAs.^{2,5} The term ENA refers to the mass containing vascular and fibrous tissue elements occurring outside nasopharynx.¹ ENAs differ from that of the nasopharyngeal variety in being more common in females and in older individuals.^{1,2} They also originate from the more exposed head and neck sites than the nasopharyngeal entity.

²Maxillary sinus is the commonest extranasopharyngeal site

in 25.8% of cases.^{1,2,4} Other uncommon sites include ethmoidal sinus, nasal cavity, cheek, larynx, sphenoid sinus, conjunctiva, oropharynx, tonsil, retromolar area, middle turbinate, inferior turbinate and infratemporal fossa.^{2,6} In contrast to nasopharyngeal angiofibroma which may be diagnosed at extremely advanced stages, ENAs frequently present at their initial stages by the early onset of symptoms like nasal obstruction and epistaxis if lesions arise from nasal cavity, though the bleeding episodes are less severe.^{1,4} In NA patients aged 15-18 years, 1-2 years elapse before diagnosis is established, which contrasts sharply with the ENAs which were correctly diagnosed within several months. Moreover, a “general march of progression”, as considered for NAs by Schiff in the order nasal obstruction, epistaxis and skeletal deformities, does not exist for ENAs. By the nature of their location, the presenting symptoms of ENAs are much more variable. The stalk of a septal ENA may be located at the junction of the perpendicular plate with the quadrangular cartilage. It had been speculated that the tissue of origin is probably the periosteum of the perpendicular plate of the ethmoid bone as an abnormal presentation of the fascia basalis.⁴ Involvement of septum may mimic bleeding polypus septum and the latter was the provisional diagnosis in our case which turned out to be angiofibroma on histology. In our case, septal angiofibroma was not considered initially owing to its extreme rarity and the common occurrence of bleeding polypus septum in the anterior septum in middle aged females. Since the site of origin in our case was the antero-inferior septum where there is no fascia basalis, we propose that it could have arisen from the ectopic tissue trapped during the growth of nasal septum. It is possible that turbinate like vascular soft tissue could have persisted as an ectopic nidus in developing periosteum during growth of the nasal septum.

Computerized tomography (CT) scan and magnetic resonance imaging (MRI) can be used to define the site of origin and extent of these lesions with regard to skull base and intracranial involvement and its relationship with neural and vascular structures.³ Nasopharyngeal angiofibroma has a contrast enhancing homogenous appearance in CT scan and MRI T1 sequences, while ENA may have inhomogeneous appearance and may not show much enhancement owing to its poor vascular supply.^{1,7,8} CT scan is considered to be sufficient for the diagnosis as it delineates the origin and extent clearly.¹ Isherwood et al. considered arteriography to be essential for angiofibroma diagnosis. Moreover, the exclusion of hypervascularity with arteriography does not

exclude ENA.⁴ Preoperative arteriography and embolization may be required if the lesion shows hypervascularity in CTscan.^{1,2} Endoscopic examination is warranted, but biopsy is ill-advised without adequate precautions for hemorrhage and airway management.⁴

NAs are characterized by the predominance of the vascular component in a fibrous stroma which contributes to excessive bleeding following biopsies. It had been found out for NAs and few patients with ENA that surface biopsies can be misleading as the typical histologic appearance can only be seen internally.⁴ Angiofibromas are histologically composed of a proliferating vascular component set in a fibrous stroma. The vascular element is characterized by blood vessels of different size and smooth muscle content. The stroma consists of plump spindle, angular or stellate shaped cells and a varying amount of collagen fibers.⁷ ENA has interstitial stromal tissue predominance with less vascular elements on histopathological examination, like that of longstanding nasopharyngeal angiofibroma.¹

²Immunohistochemical analyses may show that stromal cells have strong cytoplasmic reactivity for vimentin and are generally immunonegative for smooth muscle actin and desmin. Vascular component shows positivity for CD34 and factor VIII.⁷ Histopathology coupled with immunohistochemistry usually confirms the diagnosis of extranasopharyngeal angiofibroma.^{6,7}

Surgery for limited NAs and radiotherapy for extensive and inoperable NAs is a generally accepted protocol. Reliable open and transnasal approaches have been established but have the potential for extensive morbidity and mortality and may result in excessive hemorrhage. An 80-85% local control rate for radiotherapy has been reported, which is comparable to that for surgical procedures. A dose of 30-35 Gy is recommended, but may be increased to 40-45 Gy for extensive lesions. Other treatment modalities include cryotherapy, embolization, hormonal therapy, chemotherapy, arterial ligation, use of sclerosing agents and observation with the hope of spontaneous regression.⁴ Surgical excision is the treatment of choice for ENA.^{2,3} Preoperative embolization may be helpful when the tumor is extensive.⁷ Radiotherapy of ENAs does not play a role comparable to that for NAs. Kitano et al. reported a maxillary angiofibroma which was treated with radiotherapy (20 Gy) after biopsy in order to shrink the tumor and manage profuse bleeding.

⁴Watchful waiting is inadvisable because of the potential for

extension into the intracranial cavity.⁸

Generally the prognosis for NA is good, although recurrences rates of 10-61% have been reported. Most recurrences are symptomatic within the first year after treatment; beyond 2 years, recurrence is uncommon. Vascularity, age at onset, duration of symptoms and the site and extension of NAs may influence recurrence. In contrast to this finding, recurrence was not reported for patients with an ENA.⁴

CONCLUSION

Angiofibroma arising from the nasal septum is extremely rare. Since the site of origin in our case was the antero-inferior septum where there is no fascia basalis, we propose that it could have arisen from the ectopic tissue trapped during the growth of nasal septum. It may be mistaken for bleeding polypus septum (as in our case) or other bleeding anterior nasal masses. As described in this case, ENA differs from its nasopharyngeal counterpart in being more common in females and in older individuals with an early presentation, poor vascularity and infrequent recurrence. Thus ENAs pose a great diagnostic challenge and must be regarded as a separate clinical entity owing to its clinicopathological characteristics and should be treated surgically.

References

1. Tasca I, Compadretti GC. Extranasopharyngeal angiofibroma of nasal septum. A controversial entity. *Acta Otorhinolaryngol Ital.* 2008;28:312-4.
2. Castillo MP, Timmons CF, McClay JE. Autoamputation of an extranasopharyngeal angiofibroma of the nasal septum. *Int. J. Pediatr. Otorhinolaryngol Extra* 2000; Suppl 1: 267-70.
3. Akbas Y, Anadolu Y. Extranasopharyngeal angiofibroma of the head and neck in women. *Am J Otolaryngol.* 2003;24:413-6.
4. Hersh SP, Grimes CD Jr, Harrison WG, Iwamoto T. Angiomyofibroma of the nasal cavity: a clinical and electron micrographic study. *Otolaryngol Head Neck Surg.* 1995;112:603-6.
5. Szymańska A, Szymański M, Skomra D, Szczerbo-Trojanowska M. Extranasopharyngeal angiofibroma of the infratemporal fossa. *Otolaryngol Head Neck Surg.* 2009;140:433-4.
6. Patrocínio JA, Patrocínio LG, Borba BH, Bonatti Bde S, Guimarães AH. Nasopharyngeal angiofibroma in an elderly woman. *Am J Otolaryngol.* 2005;26:198-200.
7. Windfuhr JP, Remmert S. Extranasopharyngeal angiofibroma: etiology, incidence and management. *Acta Otolaryngol.* 2004;124:880-9.
8. Mohindra S, Grover G, Bal AK. Extranasopharyngeal angiofibroma of the nasal septum: a case report. *Ear Nose Throat J.* 2009;88:E17-9.

Author Information

J. Madana, MS.

Senior Resident, Department of Otorhinolaryngology, Jawaharlal Institute of Postgraduate Medical Education and Research (JIPMER)

Deeke Yolmo, MS.

Senior Resident, Department of Otorhinolaryngology, Jawaharlal Institute of Postgraduate Medical Education and Research (JIPMER)

S. Gopalakrishnan, MS.

Director, Department of Otorhinolaryngology, Jawaharlal Institute of Postgraduate Medical Education and Research (JIPMER)

Sunil Kumar Saxena, MS.

Professor, Department of Otorhinolaryngology, Jawaharlal Institute of Postgraduate Medical Education and Research (JIPMER)