

# Necrotizing Fasciitis Of Lower Limb In 4 Patients

M Lawson, E Lawson, A Akué, F Atadokpede

## Citation

M Lawson, E Lawson, A Akué, F Atadokpede. *Necrotizing Fasciitis Of Lower Limb In 4 Patients*. The Internet Journal of Orthopedic Surgery. 2012 Volume 19 Number 2.

## Abstract

The necrotizing fasciitis of limbs is a toxic severe infection who can compromise functional and vital prognosis. We report 4 cases of the lower limb. It was about 2 men and 2 women with an average age of 65,25 years. We have found a skin injury for all the patients but the germs were isolated for only two of them. The medical treatment consisted in antibiotics and analgesics administration. The surgical one consisted in the wide ablation of necrotic tissues for three patients and an amputation in the thigh for the fourth. Two patients have got a good evolution and received a skin graft. For the last patient, the extension of necrosis have obliged to amputate in the thigh. The necrotizing fasciitis of the lower limb is uncommon and necessitates an emergency medical and surgical treatment.

## INTRODUCTION

The necrotizing fasciitis of limbs is a toxic severe infection. It's an uncommon affection. Its precocious diagnosis is difficult. Confusions have been made since the first terminology of streptococcus gangrene [1] and necrotizing fasciitis [2] until the consensus conference on the subject [3]. We report 4 cases of necrotizing fasciitis of lower limb to specify the clinic aspects, to draw on the interest of precocious diagnosis, on the difficulty to isolate the B-haemolytic streptococcus and on the emergency of the medical and surgical treatment.

## CASES REPORTS

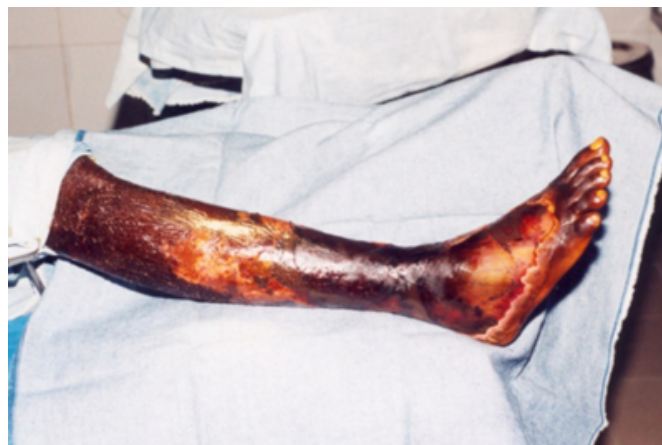
### CASE 1

A 44 years old man presented with a right painful swollen ankle as a result of a scratch 2 weeks earlier with a temperature estimated at 38°C with headaches and vomiting. We eliminated fracture and malaria. The antibiotic treatment (Penicillin M 1g\* twice in a day associated with Aminoside 80mg\* twice in a day, relieved 5 days after with Cephalosporine third generation 1g\* twice in a day associated with Imidazole 500mg\* twice in a day) associated with the raise of the lower limb lead to worsening with extensive bruise and phlyctenas. A lower limbs echography eliminated an arterial thrombosis. We have found a blood-leucocytose with 91% of neutrophils polynuclears. An orthopaedic and traumatologic surgeon seen after 9 days put an end to the antibiotic treatment, begins treatment with Penicillin G 10 millions in drip three times in a day and

decided a wide removal of the skin injuries (Fig. 1). The operation took place 3 days after and we have noted absence of purulent collection. The extensive necrosis from the foot to the knee interests the subcutaneous tissues, the superficial aponeurosis of the leg and intermuscular expansions (Fig. 2).

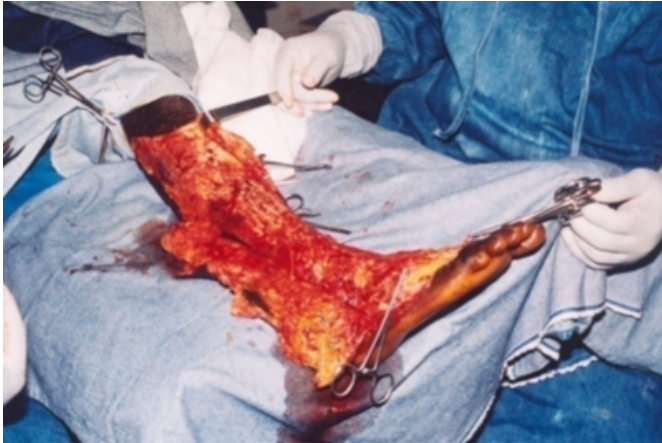### Figure 1

Figure 1



**Figure 2**

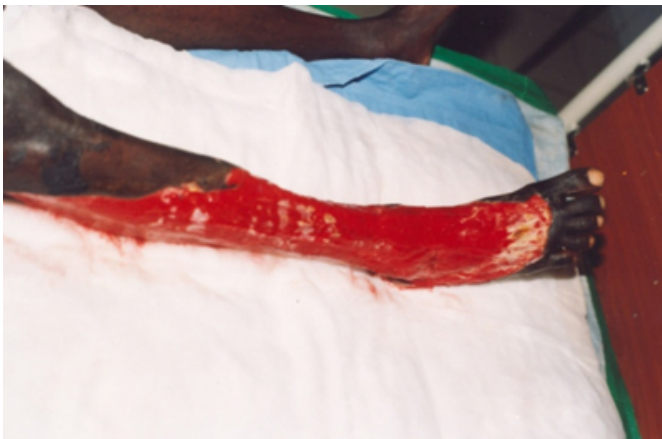
Figure 2



The superficial vessels were thromboses. The necrotic tissues formed fluffy thick buds of dark green to yellowish brown color. No germ has been isolated. With rigorous local treatment and antibiotic treatment (Cephalosporine second generation 750 mg\* twice in a day by venous way while 7 days relieved by oral form 500 mg\* twice in a day while 14 days again), the condition of the patient improves spectacularly (Fig. 3.). The patient received a cutaneous graft 19 days after the first surgical operation and leaved the hospital after having been hospitalized for 2 months and 18 days. He resumed his work after a five months leave of absence (Fig. 4).

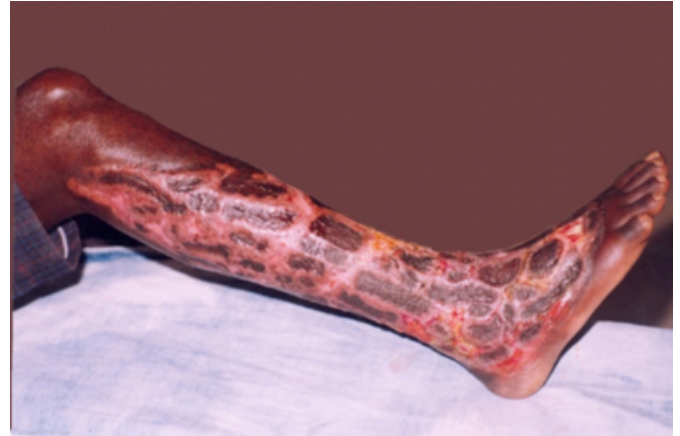
**Figure 3**

Figure 3



**Figure 4**

Figure 4



### CASE 2

A 70 years old man was seen with a left painful swollen leg. It began one week ago with fever, shiver followed by pains and a swollen of the left leg. There was no risk factor of thromboembolism disease. The clinical and complementary examinations allowed us to note down an ipsilateral inguinal adenopathy, a cutaneous wound, a biological inflammatory syndrome. The diagnosis of erysipelas of left leg was done. A medical treatment with Nonsteroidal anti-inflammatory drugs, antibiotics (quinolone, penicillin and imidazole) and analgesics by venous way lead to apparition of phlyctenular injuries extent from the leg to the ankle. Doagnosis of a necrotizing fasciitis of left leg and ankle was made. A wide removal of necrotical tissues of the left ankle and the leg was done. A cutaneous graft was done complementary and the patient left the hospital.

### CASE 3

A 62 years olds diabetic woman presented at the reanimation department of the army hospital for a left painful swollen leg and deterioration of consciousness. A dog had bitten her at the left leg 5 weeks ago. A traditional treatment should have been applied to the wound. Locally, the physical examination noted a left swollen leg with Inflammatory placards extent from the foot to the third lower of the thigh, the point of the bite at the medial part of the ankle with yellowish and smelly matter and an open skin injury in front of Achille's tendon. The blood sugar at admission was 5.5 grams by liter. The diagnosis of necrotizing fasciitis of the left leg was done. Two germs have been isolated at the cytobacteriological exam: the Streptococcus B hemolytic and Escherichia coli. The specific antibiotic treatment associated with hydroelectrolytic treatment and diabetic treatment was started. 2 days after the admission at hospital,

a wide surgical removal of necrotical tissues of the posterior side of the leg was done. The post operative evolution was unfavourable with extension of the necrosis at all the leg and the third lower of the thigh leading to an amputation.

### CASE 4

A 80 years old woman was seen for an inflammation extent from the dorsal part of the right foot to the knee with a skin injury and that since 8 days. The clinical examination noted an oedema of the right lower limb, the presence of wide phlyctena with cloudy liquid at the anterior side of the leg and around the ankle, a skin wound with matter. The diagnosis of cellulites of the right lower limb was done. The evolution after a local treatment (removal of necrotizing tissues) associated with antibiotic treatment (cephalosporin with lincocin) was unfavourable with the extension of the necrosis in depth from the lateral side of the right foot to the ankle. The *Pseudomonas aeruginosa* was isolated at the cytbacteriological exam with sensitivity to colistine, imipeneme and aztreonam. An orthopaedic surgeon seen after 1 week of hospitalization evoked a pyodermitis of streptococcus origin in front of the extension of the malleolar injury toward the knee with a skin still healthy. But the existence of pustules and no simples vesicles and the relative general good condition of the patient make throw back the streptococcus origin. The local evolution of the injuries and the relative condition of the patient (age, pulmonary embolism) lead to an amputation at the thigh. During the operation, we have noted the extensive necrosis to the muscular aponeurosis with infiltration between the muscles.

### DISCUSSION

The necrotizing fasciitis is a toxic severe infection. Several terminology have been used in the literature until the consensus conference on the subject [3] with the appearance of the terms of dermohypodermatitis and necrotizing fasciitis, based respectively on the respect or the attack of the superficialis aponeurosis. The general effect of the infection is severe (fever, deterioration of consciousness, toxemia, anaemia, hypoprotidemia, hypocalcemia, inadequacy of kidney). The physical signs are near to bacterial hypodermatitis. Oedema, phlyctenae, cyanic tasks and the cutaneous necrosis are marked. The oedema extends to root of the lower limb. The erythema, signing the streptococcic origin of the infection, is more diffuse and also interests all the member. The evolution is very fast in a few days bringing into play the vital prognosis with the extension of the local and general signs. The diagnosis passes by 3 stages:

it is necessary to affirm the streptococcic origin of the infection, to recognize the surgical indication and to differentiate other streptococcic pathologies. Clinically, the streptococcic origin of the infection is recognized by the discovery of the erythema. It is badly limited, diffuse and goes up to the root of the member. The therapeutic penicillin test makes it possible to pose the surgical indication [2, 4]. The duration of waiting before operational indication is variable according to the case. The differential diagnosis must eliminate the other streptococcic affections: Erysipelas or bacterial dermohypodermatitis, the érysipélateoïde reaction. Unfortunately, bacteriology is little of assistance in these affections. Indeed, these lesions occur after wounds soiled by a polymicrobial population. Such an infection is usually benign, responsible at worst for a purulent infection with abscess of the soft parts. Within this microbial population, only the streptococcus one is likely to cause this evolution necrosis [1, 3, 4, 5]. Its identification in this medium is a challenge. In practice, it will be very often masked either by the contaminants or by the antibiotic treatment founded rightly in front of the gravity of the general state. But other germs were highlighted: the staphylococcus aureus, enterobacteries, bacteroïdes, bacteria anaerobic and the *Pseudomonas*, *Aeromonas sobria*, Community-Acquired Methicillin-resistant *Staphylococcus aureus* (CA-MRSA), *Streptococcus pneumoniae* [2, 6, 7, 8, 9]. Sometimes, no germ is found in spite of multiple taking away. The treatment of the necrotizing fasciitis is medical and surgical. The medical care is based on the analgesics and antibiotic administration. The antibiotic treatment was evoked during the therapeutic test to penicillin. The bacteriological proof seldom being only made directly, it is the indirect evidence by the effectiveness of the penicillin which made it possible to retain its higher clinical effectiveness. Other molecules are considered active on the *Streptococcus beta-haemolytic* one. There are the amoxicilline or the clindamycine. They have their place only after having made a therapeutic test with penicillin. The daily amount ranges between 18 and 24 million by 12 midnight. Many authors insisted on the danger of the use of Nonsteroidal Anti-Inflammatory Drugs in the assumption of responsibility of the streptococcic toxidermies [3, 9] before even the conference of consensus. The surgical excision for all the authors constitutes principal therapeutic time. It must carry the skin with pathological cellular fabrics. The evolution after excision is generally favorable with secondary cicatrization after cutaneous graft. The indications of amputation are rare. They occur only in the event of wide lesions of the soft parts generally associated with a

deterioration with the general state, generally at old patients. Ek Chee and al. [10] revealed that higher mortality rate is seen among those patients with advanced age and those presented with initial high pre-operative creatinine levels.

### CONCLUSION

The necrotizing fasciitis is a rare toxic infection. Its diagnosis must be precocious to avoid regional and general complications. The treatment is based on administration of analgesics antibiotics and the removal of the necrosed tissues.

### References

1. Meleney FL. Hemolytic Streptococcus gangrene. Arch Surg. 1924 ; 9 :317-64.
2. Wilson B. Necrotizing fasciitis. Ann Surgeon 1952 ; 18 :416-31.
3. Société de Pathologie Infectieuse de Langue française et Société Française de Dermatologie. Conférence de consensus. Erysipèle et fasciite nécrosante : prise en charge. Med Mal Infect. 2000 ; 30 :241-5.
4. Lortat-Jacob A. Hypodermes et fasciites nécrosantes des membres chez l'adulte. Conférence d'enseignement. 2005 :195-204.
5. Société française de dermatologie. Conférence de consensus. Erysipèle et fasciite nécrosante : prise en charge. Texte long. Ann Dermatol Venereol. 2001 ; 128 :463-82.
6. Menard R., Pierre A., Pierrard G., Burdin G., Hulet C., Vielpeau C. Dermohypodermes et fasciites nécrosantes des membres inférieurs. A propos de 7 cas consécutifs survenus de mai à novembre 2002. Ann Orth. Ouest 2004 -36 – 167 à 172.
7. Tsai Y.-H., Huang K.-C., Huang T.-J., Hsu R. W.-W. Fatal Necrotizing Fasciitis Caused by *Aeromonas sobria* in Two Diabetic Patients. Clin Orthop Relat Res (2009) 467:846–849.
8. Chan CK., Merican AM., Nawar AM., Hanifah YA., Thong KL. Necrotising Fasciitis of the Lower Limb caused by Community-Acquired Methicillin-Resistant *Staphylococcus aureus*. Malaysian Orthopaedic Journal 2010 Vol 4 No 3 : 36-38.
9. Frick S., Cerny A. Necrotizing Fasciitis Due to *Streptococcus pneumoniae* after Intramuscular Injection of Nonsteroidal Anti-Inflammatory Drugs: Report of 2 Cases and Review. Clinical Infectious Diseases 2001; 33:740–4.
10. Chee EK, Kwan MK, Khoo EH. Necrotizing Fasciitis of the Lower Limb – A Prospective Study of Prognostic Factors Affecting Mortality. Malaysian Orthopaedic Journal. 2009 Vol 3 No 1: 32-35.

**Author Information**

**Michel Lawson, MD**

staff orthopaedic surgeon, Department of Orthopaedic and Traumatologic Surgery, Hubert K Maga Teaching Hospital

**Eric Lawson, MD**

Resident, Department of Orthopaedic and Traumatologic Surgery, Hubert K Maga Teaching Hospital

**Aristote Hans-Moevi Akué, MD, PhD**

Orthopaedic surgeon, Department of Orthopaedic and Traumatologic Surgery, Hubert K Maga Teaching Hospital

**Felix Atadokpede, MD**

dermatologic physician, Department of Dermatology, Hubert K Maga Teaching Hospital