

Non-Union Of Fractured Distal Radius Treated With A Volar Locking Plate: A Case Report

R TB, K AJ

Citation

R TB, K AJ. *Non-Union Of Fractured Distal Radius Treated With A Volar Locking Plate: A Case Report*. The Internet Journal of Orthopedic Surgery. 2012 Volume 19 Number 2.

Abstract

Non-union following volar plate fixation for distal radius fractures is a rare complication. Diabetes and obesity are known risk factors. We have described a case of non union of a distal radius following open reduction internal fixation and uniting after revision with a combination of non-autologous and autologous bone graft. In patients with known risk factors for non union of distal radius fractures we recommend considering the use of bone graft in the primary setting.

BACKGROUND

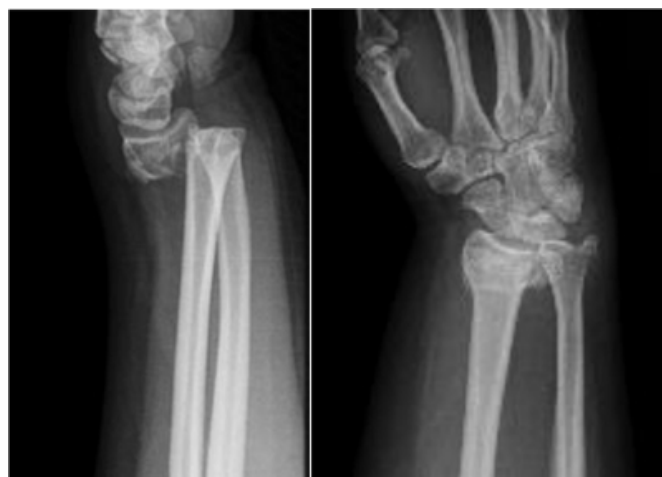Volar locking plates have revolutionised the treatment of complex distal radius fractures. Benefits of volar locking plates include maintenance of fracture reduction and early mobilisation and physiotherapy 1 2. However, they are not without risks, including tendon rupture from prominent hardware on the volar or dorsal aspect of the distal radius, superficial and deep infection 3. Non-union is a rare complication, with few cases described in the literature 4 5 6 7. Because of its rarity, there is little consensus on the optimum method of operative treatment 8 9. We report a case of a non-union of a distal radius fracture treated with a volar locking plate, subsequently uniting post revision with bone grafting.

CASE REPORT

A 31 year-old female who suffered a fall onto an outstretched right hand while bush walking. She presented to the emergency department of a Sydney metropolitan hospital with right wrist pain and deformity. She had a background of polycystic ovarian syndrome, type 2 diabetes and obesity. She was a non-smoker. Examination findings included an obvious deformity to the right wrist, with no neurovascular compromise or open injury. X-Ray examination revealed dorsally displaced off-ended right distal radius fracture.

Figure 1

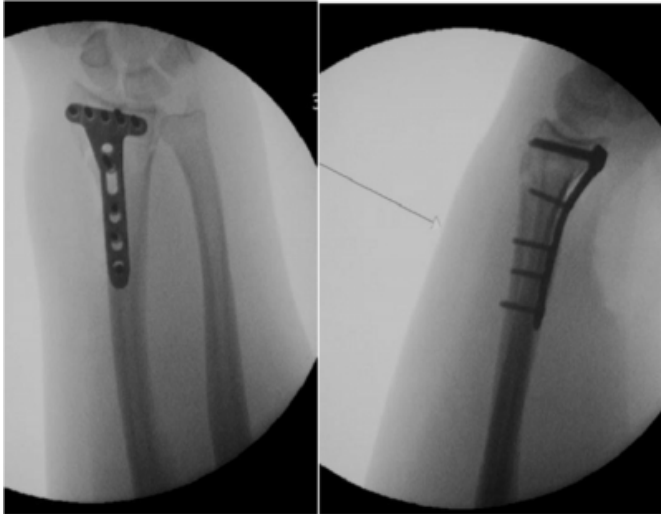
Figure 1 initial radiographs of the right wrist showing displaced off-ended distal radius fracture



A closed reduction in the emergency department was undertaken, with a satisfactory position on post-reduction x-rays. The patient underwent an open reduction and internal fixation 2 days later with a Synthes fixed-angle volar locking plate. The procedure and her recovery were uncomplicated.

Figure 2

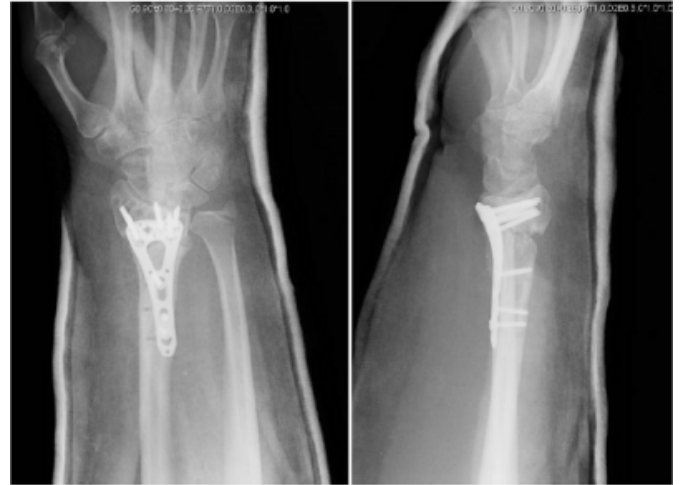Figure 2 radiographs of the right wrist following initial fixation with a volar locking plate



After nine months the patient returned for unplanned follow up, complaining of persisting pain. Examination revealed tenderness over the distal radius and x-rays revealed a non-union. At this point the plate was removed, the fracture site debrided and packed with autologous iliac crest bone graft and the original plate was re-inserted. The revision procedure was unsuccessful in promoting union of the fracture and a second revision procedure was undertaken 12 months later. This involved removal of the existing hardware, debridement of the fracture site, insertion of autologous iliac crest bone graft mixed with OP-1/BMP-7 (Olympus Biotech), and insertion of a Synthes variable-angle locked plate. The second attempt at revision was successful and the fracture went on to unite 5 months after the last procedure.

Figure 3

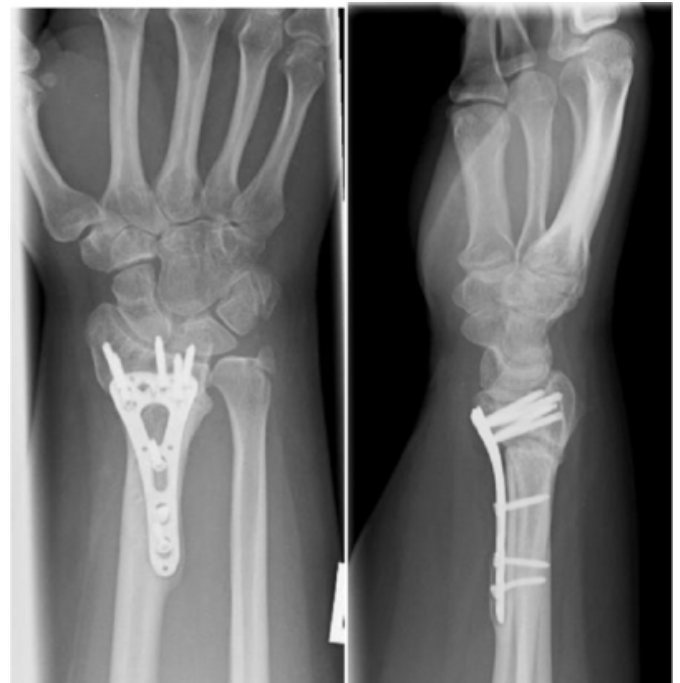Figure 3 radiographs of the right wrist 5 months following revision with volar locking plate and bone grafting



The patient was again followed up 10 months after the revision surgery. Examination revealed no further tenderness over the fracture site and 40 degrees of wrist flexion and 20 degrees of extension.

Figure 4

Figure 4 shows radiographs of the right wrist 10 months following revision with volar locking plate and bone grafting



DISCUSSION

In general, union rates of distal radius fractures and time to healing have been satisfactory following open reduction internal fixation with a volar locking plate 2. Non-union is a

rare complication. Several factors may have contributed to the non union in the patient described in our case study. Obesity and diabetes are known risk factors associated with non union in the distal radius 7.

The design of the plate may have also contributed to the non-union. Locking plates may cause non union as they provide too much stability at the fracture site. Several biomechanical studies suggest that locked-plate constructs are too stiff and suppresses the interfragmentary motion which promotes secondary fracture healing by callus formation 10 11.

This has yet to be specifically related to non-union of distal radius fractures, however recent studies regarding periarticular locked plates for the distal femur have increased the concern of the inherently high stiffness of locked-plate constructs suppressing callus and contributing to non-union 12 13. Bottlang et al. Introduced the concept of 'far-cortical-locking' screws in order to reduce the stiffness of a locked plate construct to that of an external fixator, providing parallel interfragmentary motion, while retaining construct strength 14.

Interestingly, the plate itself did not fail during the initial 9 months of non union or during the further 12 months in which the same plate was used following revision with iliac bone graft. Hardware failure has been described in patients with delayed or non union, possibly due to prolonged stresses on the plate when race against fatigue failure is lost. 15 16 17. One case by De Bere et al reported hardware breakage and fracture displacement 14 weeks following open reduction internal fixation with volar locking plate 5. Correct placement of the plate on bone has been shown to significantly affect axial stiffness and tensional rigidity 18 and may have contributed to the plate withstanding the prolonged forces during the non union period.

No bone graft was used in our case at time of the initial operation. Bone grafting in the acute setting has been shown to provide structural support promoting bony healing 19 20. Volar locking plates however, provide stability at the fracture site and have largely reduced the need for bone grafting in the initial setting 4. Situations remain where bone grafting at the initial operation may be indicated, such as where major bone defects remain following reduction or in patients that are at risk of non union 21 16 22 23.

Several cases of using iliac bone graft for non union have been described in the literature with excellent results 6 24 9.

In our case however, following the failure of the iliac bone graft in promoting union, we chose to use an osteoinductive bone substitute mixed with iliac bone graft. We used osteogenic protein-1 (OP-1) also known as recombinant BMP-7. OP-1 is a bone morphogenic protein (BMP) with osteoinductive properties. Use of OP-1 has been demonstrated in spinal fusion, tibial non-union, fibula defects and pelvic girdle non-union 24. Ekrol explored the use of OP-1 in healing metaphyseal defects following corrective osteotomies for mal-union in distal radial fractures. They found slower and less complete bone healing with the use of OP-1 compared to iliac bone graft 24. They did note however that a reason for this was because the lack of structural support OP-1 paste offered compared with iliac bone graft. In our case, the use of OP-1 with the structural support offered by the iliac bone graft and volar locking plate was successful with the fracture uniting after 5 months.

CONCLUSION

Non-union following volar plate fixation for distal radius fractures is a rare complication, however obesity and diabetes are known risk factors. We have described a case of non union in such a situation and the use of a combination non-autologous and autologous bone graft in promoting union. In patients with known risk factors for non union of distal radius fractures we recommend considering the use of bone graft in the primary setting.

References

1. Henry M. Distal Radius Fractures: Current Concepts. *J Hand Surg.* 2008;33A:1215-1227.
2. Haidukewych G, Ricci W. Locked plating in orthopaedic trauma: a clinical update. *J Am Acad Orthop Surg.* 2008;16:347-55.
3. Orbay J. Volar plate fixation of distal radius fractures. *Hand Clin.* 2005;Aug;21(3):347-54.
4. Cao J, Ozer K. Failure of volar locking plate fixation of an extraarticular distal radius fracture: A case report. *Patient Saf Surg.* 2010;4: 19.
5. DeBaere T, Lecouvet F, Barbier O. *Acta Orthopaedica Belgica.* Breakage of a Volar Locking Plate after Delayed Union of a distal radius fracture. 2007;73:785-790.
6. Smith V, Wright T. Nonunion of the Distal Radius. *J Hand Surg Eur Vol.* 1997;24B(5):601-603.
7. Segalman K, Clark G. Un-united Fracture of the Distal Radius: A report of 12 Cases. *J Hand Surg Am.* 1998;23:914-919.
8. Prommersberger K, Fernandez D. Nonunion of distal radius fractures. *Clin Orthop Relat Res.* 2004;419:51-6.
9. Fernandez D, Ring, D, Jupiter J. Surgical management of delayed union and non-union of distal radius fractures. *J Hand Surg.* 2001;26-A : 201-209.
10. Egol K, Kubiak E, Fulkerson E, Kummer F, Koval K. Biomechanics of locked plates and screws. *J Orthop Trauma.* 2004;18:488-93.
11. Perren S. Backgrounds of the technology of internal fixators. *Injury.* 2003;34 Suppl 2:B1-3.

12. Henderson C, Bottlang M, Marsh J, Fitzpatrick D, Madey S. Does locked plating of periprosthetic supracondylar femur fractures promote bone healing by callus formation? Two cases with opposite outcomes. *Iowa Orthop J*. 2008;28:73-6.
13. Lujan T, Henderson C, Madey S, Fitzpatrick D, Marsh J, Bottlang M. Locked plating of distal femur fractures leads to inconsistent and asymmetric callus formation. *J Orthop Trauma*. 2010;24:156-62.
14. Bottlang M, Doornink J, Lujan T, et al. Effects of Construct Stiffness on Healing of Fractures Stabilized with Locking Plates. *J Bone Joint Surg Am*. 2010;92 Suppl 2:12-22.
15. Sommer C, Babst R, Muller M, Hanson B. Locking compression plate loosening and plate breakage : a report of four cases. *J Orthop Trauma*. 2004;18 : 571-577.
16. Berglund L, Messer T. Complications of Volar Plate Fixation for Managing Distal Radius Fractures. *J Am Acad Orthop Surg*. 2009;17(6):369-377.
17. Orbay J, Touhami A. Current concepts in volar fixed-angle fixation of unstable distal radius fractures. *Clin Orthop Relat Res*. 2006;445:58-67.
18. Ahmad M, Nanda R, AS B, Candal-Couto J, Green S, Hui A. Biomechanical Testing of Locking Compression Plates: When does the distance between bone and implant significantly reduce construct stability? *Injury*. 2007;38:358-364.
19. Ladd A, Pliam N. Use of bone-graft substitutes in distal radius fractures. *J Am Acad Orthop Surg*. 1999;7(5):279-90.
20. McBirnie J, Court-Brown C, McQueen M. Early open reduction and bone grafting for unstable fractures of the distal radius. *J Bone Joint Surg Br*. 1995;Jul;77(4):571-5.
21. Freeland A, Lubner K. Biomechanics and Biology of Plate Fixation of Distal Radius Fractures. *Hand Clin*. 2005;21:329-339.
22. Tosti R, Ilyas A. The role of bone grafting in distal radius fractures. *J Hand Surg Am*. 2010;Dec;35(12):2082-4.
23. Goto A, Murase T, Oka K, Yoshikawa H. Use of the volar fixed angle plate for comminuted distal radius fractures and augmentation with a hydroxyapatite bone graft substitute. *J Hand Surg*. 2011;16(1):29-37.
24. Ekrol I, Hajducka C, Court-Brown C, McQueen M. A comparison of RhBMP-7 (OP-1) and autogenous graft for metaphyseal defects after osteotomy of the distal radius. *Injury*. 2008;Sep;39 Suppl 2:S73-82.

Author Information

Rappo TB, MBBS Syd

Orthopaedic Senior Resident, Blacktown Hospital

Kanawati AJ, MBBS UNSW

Orthopaedic Registrar, Westmead Hospital