

The Different Clinical Expressions of the Aspergillus/Host Interactions in Humans

A Huaringa, S Malek

Citation

A Huaringa, S Malek. *The Different Clinical Expressions of the Aspergillus/Host Interactions in Humans*. The Internet Journal of Pulmonary Medicine. 2012 Volume 13 Number 1.

Abstract

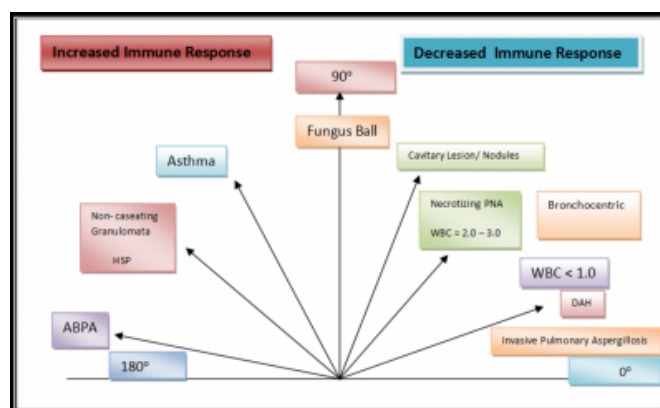
Aspergillus is very ubiquitous. It is a highly aerobic fungus and found as mold on surfaces. It spreads most commonly through spores in the air that are not detected with the naked eye. These spores get into the respiratory tract where they colonize and often cause different kinds of reactions. Human beings respond to these inhalations in several ways depending upon the status of one's immune system. In fact some of these responses are diametrically opposed from each other to the point that we decided to report our experience of the different expressions of the Aspergillus/human interaction in a spectral fashion. We have represented these findings in a parabola pictured below where to the right of the parabola from 0° to 90°, we included the interactions of Aspergillus with an immune deficient host, and to the left of the parabola from 90° to 180°, we considered the interactions of Aspergillus with a host of a hyperergic immune system.

INTRODUCTION

Aspergillus is very ubiquitous. It is a highly aerobic fungus and found as mold on surfaces. It spreads most commonly through spores in the air that are not detected with the naked eye. These spores get into the respiratory tract where they colonize and often cause different kinds of reactions. Human beings respond to these inhalations in several ways depending upon the status of one's immune system. In fact some of these responses are diametrically opposed from each other to the point that we decided to report our experience of the different expressions of the Aspergillus/human interaction in a spectral fashion. We have represented these findings in a parabola pictured below where to the right of the parabola from 0° to 90°, we included the interactions of Aspergillus with an immune deficient host, and to the left of the parabola from 90° to 180°, we considered the interactions of Aspergillus with a host of a hyperergic immune system.

Parabola:

Figure 1



COMMENTARY

Starting at the 0° line, patients who are severely neutropenic develop invasive pulmonary aspergillosis sometimes expressed as diffuse alveolar hemorrhage (DAH) and causing widespread hematogenous dissemination involving the heart valves, brain, and kidneys (1). These patients are usually neutropenic with an absolute neutrophilic count of 100 or less. A patient who remains neutropenic at this level for one week, has a 50% chance to develop aspergillosis (2,5,6,9). Once the immune system is partially reconstituted and the absolute neutrophil count is around 1,000, we tend to see necrotizing pneumonias (PNA) and/or bronchocentric implantations as reactions to the inhalation of aspergillus (7). By the time the absolute neutrophil count is around 2-3,000

we see cavitating nodules as a result of better confinement of the infection but with preservation of destructive properties of the aspergillus causing these lesions. In this side of the spectrum, we also find the patients who had undergone bone marrow transplantation, more so if they have graft vs. host disease and require immunosuppressant therapy. The therapeutic options include intravenous voriconazole 6mg/kg every 12 hours for 1 day, followed by 4 mg/kg every 12 hours until improvement, followed by oral voriconazole 200 mg every 12 hours or oral itraconazole 400-600 mg/day until resolution or stabilization of all clinical and radiographic manifestations or intravenous liposomal amphotericin B 3-5 mg/kg/day until improvement, followed by oral voriconazole 200 mg every 12 hours or itraconazole 400-600 mg/day until resolution or stabilization of all clinical and radiographic manifestation (7).

At the straight 90 ° angle is where we see the classic fungus ball pattern of Aspergillois or Aspergilloma trying to live in a symbiotic environment not causing further destruction but living in previously formed cavities. However aspergillus occasionally may cause erosions and bleeding in these cavitary lesions. Consequently, patients then present with hemoptysis which might be massive in which case bronchial artery embolization and even surgical resection may be considered. The cavities usually result from preexisting tuberculosis, bronchiectasis, old infarcts or abscesses (5).

Moving counterclockwise to the left from 90 ° we enter the zone of increased immune response to the Aspergillois inhalation. When the host is immunocompetent, the inhalation of Aspergillus could cause bronchitis with consequent bronchospasm and eventually leading to the development of asthma. Patients develop an allergic or hypersensitivity reaction to the spores of Aspergillus due to the antibodies producing a type I acute hypersensitivity reaction with the release of immunoglobulin E (IgE). Immune complexes and inflammatory cells are then deposited within the bronchial mucosa. This deposition produces tissue necrosis and eosinophilic infiltrate, a type III reaction, and results in damage to the bronchial wall (3). The body's reaction to this is to mount an immune response towards the Aspergillus species. The following inhalations provoke an asthmatic response with bronchospasm and airway inflammation.

When the inhalation is chronic and in small loads, the lymphocytic response that it triggers will eventually chemoattract macrophages that will lead to the formation of non-caseating granulomata, a phenomena which is the

pathological expression of hypersensitivity pneumonitis (HSP), also called extrinsic allergic alveolitis. This may be treated with simple avoidance of exposure and there is no need of antifungal therapy.

The most exaggerated response is seen when the inhalation of aspergillus triggers a major eosinophilic response with the development of bronchoconstriction, mucus plugging, severe inflammation that leads to bronchitis and bronchiectasis. This is known as Allergic Bronchopulmonary Aspergillois (ABPA) in whom there is significant peripheral eosinophilia and elevated IgE and only responds to high dose corticosteroids (4).

In addition to all aforementioned, it is possible to find a combination of these different clinical expressions, such as a Bronchocentric Aspergillois in the immunosuppressed side of the spectrum having an asthmatic response, and the reverse case, an ABPA patient in the hyperergic immune response side of the spectrum having a Necrotizing pneumonia or Bronchocentric Aspergillois.

CONCLUSIONS

In order to understand what is happening in an aspergillus/human being interaction, it is imperative to know the absolute neutrophil count and the bone marrow function, the preexisting structural and functional abnormalities of the lung, the status of the immunoreactivity before the interaction (bronchial hyperreactivity, eosinophilia, Ig E levels) and during the interaction: B-cell immunity (antibodies, other gammaglobulin levels, corticosteroid use, etc.) and T-cell immunity (HIV status, CD4 count, skin tests, etc.), and the history and stage of the bone marrow transplantation.

Finally, another important message is that aspergillus is very difficult to retrieve from sputum, tracheal aspirates, bronchial washings, bronchial washings, bronchial biopsies, or bronchoalveolar lavage (5,6), consequently it is of utmost important to keep a high index suspicion and use all the technology (11) you have available to identify its presence as early as possible because when advanced it is very difficult to eradicate.

References

1. Abigail R. L., and Marvin I. S., MD. May 2010. Diffuse Alveolar Hemorrhage. *Chest* 137(5): 1164-1171.
2. Am. J. September 1998. Lung Resection for Invasive Pulmonary Aspergillois in Neutropenic Patients with Hematologic Diseases. *Respiratory and Critical Care Medicine* 158(3): 885-890.
3. Bromley I.M., Donaldson K. 1996. Binding of Aspergillus

fumigatus spores to lung epithelial cells and basement membrane proteins: relevance to the asthmatic lung. *Thorax* 51: 1203-1209.

4. Greenberger P, M.D. and Patterson R., M.P., F.C.C.P. June 1987. Allergic Bronchopulmonary Aspergillosis: Model of Bronchopulmonary Disease with Defined Serologic, Radiologic, Pathologic and Clinical Findings from Asthma to Fatal Destructive Lung Disease. *Chest* 91(6):165S-171S

5. Huaranga, A.J., Signes-Costa, J. and Morice, R.C.: Role of Bronchoscopy for the Diagnosis of Pulmonary Complications Following Bone Marrow Transplantation. *American Journal of Respiratory and Critical Care Medicine* 149, #4, A843, 1994.

6. Huaranga A., Leyva F., Signes-Costa J., Darwish A., Morice R., Raad I., and Champlin R.: Bronchoalveolar Lavage in the Diagnosis of Pulmonary Complications of Bone Marrow Transplant Patients. *Bone Marrow Transplantation*, 25: 975-979, 2000.

7. Huaranga A., Leyva F., Giralt S., Velarde H., Signes-Costa, J., Blanco J., and Champlin R.: Outcome of Bone Marrow Transplant Recipients Requiring

Mechanical Ventilation. *Critical Care Medicine* 28 (4), April 2000: 1014-1017.

8. Kang Y., Kim H., Woo O.H., Choi A., Y. Oh and Kim C. H. 2002. Pulmonary Aspergillosis in Immunocompetent Hosts without Underlying Lesions of the Lung: Radiologic and Pathologic Findings. *American Journal of Roentgenology* 178:1395-1399.

9. Mühlemann K., Wenger C., Zenhäusern R., and Täuber M G. February 2005. *Leukemia* 19: 545-550

10. Limper A.H., Knox K.S., Sarosi G.A., Ampel N.M., Bennett J.E., Catanzaro A., Davies S.F., Dismukes W.E., Hage C.A., Marr K.A., Mody C.H., Perfect J.R., Stevens D.A. May 2010. An Official American Thoracic Society Statement: Treatment of Fungal Infections in Adult Pulmonary and Critical Care Patients. *American Thoracic Society Documents*. Volume 183: 96-128.

11. Raad I., Hanna H., Huaranga A., Sumoza D., Hachem R., and Albitar M. Diagnosis of Invasive Pulmonary Aspergillosis using Polymerase Chain Reaction Based Detection of Aspergillus in Bronchoalveolar Lavage. *CHEST* 2002, April; 121(4): 1171-76.

Author Information

Armando J. Huaranga, M.D

Department of Medicine, White Memorial Medical Center and Loma Linda University School of Medicine

Sanaz Malek, M.D

Department of Medicine, White Memorial Medical Center and Loma Linda University School of Medicine