

Imaging Features Of Pelvic Gossypiboma

A K Reddy, P M Lakshmanan, R Govindarajalou, A Jayamohan

Citation

A K Reddy, P M Lakshmanan, R Govindarajalou, A Jayamohan. *Imaging Features Of Pelvic Gossypiboma*. The Internet Journal of Radiology. 2013 Volume 16 Number 1.

Abstract

Gossypiboma is the complication of a post-surgical retained surgical sponge. Here we discuss a case of pelvic gossypiboma that presented as a mass in the pelvis associated with per rectal and per vaginal discharge. The diagnosis was made after sonography, contrast radiography, computed tomography and supported by MRI. The diagnosis was confirmed on surgery, the gossypiboma was retrieved successfully and the perforation was closed.

INTRODUCTION

Gossypiboma refers to the surgical complications resulting from surgical sponge accidentally left inside a patient's body. Frequently it presents as a mass within a patient's body comprising a cotton matrix surrounded by a foreign body granuloma¹. The incidence is found to be one in 3000 to 5000 abdominal operations.

The origin of "Gossypiboma" is from the Latin word – Gossypium (Cotton) and Swahili word boma (place of Concealment). Likewise "Textiloma" is derived from textile (surgical sponges made of cloth) and the suffix "-oma", meaning a tumor or growth. The first case of gossypiboma was reported by Wilson in 1884², 3.

CASE REPORT

A 37 year old woman was admitted with complaints of pus discharge per vagina and per rectum for a period of 20 days and fever with chills and rigors for 10 days. A mass was noted in the pelvis during the third lower segment caesarian section 70 days prior to admission to this hospital.

On examination her general condition was fair and vitals stable. The abdomen was soft and the previous lower segment caesarian section scar was indurated. A firm tender mass was felt in the pouch of Douglas and both fornices per vaginally. Per speculum examination revealed fullness in the pouch of Douglas with mucoid discharge through cervical os. The uterus was found to be anteverted and pushed to the left side.

Per rectally a large indurated mass was felt 6 cms from anal verge and the finger stained with pus. With a clinical differential diagnosis of pelvic abscess/tumour the patient

was evaluated sonographically.

Sonographic findings: ultrasound was performed after admission which showed linear hyper echoic lesion located posterior to the uterus throwing strong posterior acoustic shadow. In order to rule out loaded bowel ultrasound was repeated after laxatives the next day. The same sonographic findings persisted. With the history of repeated surgery the possibility of retained foreign body was suspected and hence a rectal contrast radiography was done.

Figure 1a

On the transverse section the linear hyperechoic lesion (arrowhead) lies posterior to the uterus (UT) displacing the rectum (R) towards the right

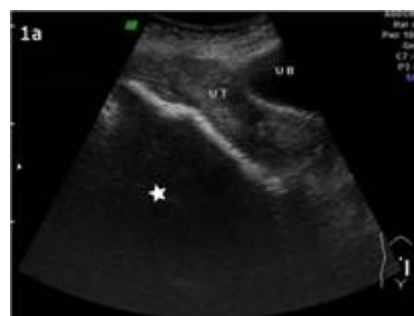

Figure 1b

Repeat ultrasound after laxative shows persisting linear hyper echoic lesion posterior to the uterus (UT) throwing strong after shadowing (star).

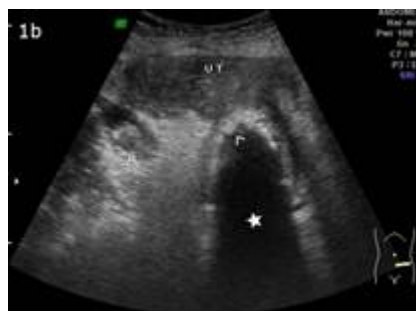
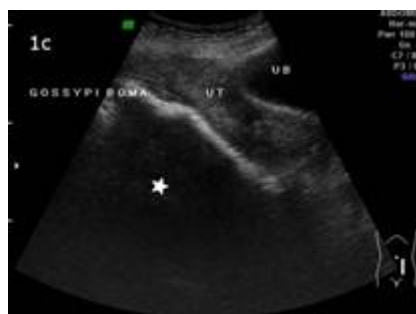
Figure 1c

Rectal contrast radiography anteroposterior view with diluted iohexol shows normal filling of the narrowed rectum with minimal distension of the distal sigmoid colon. There is a filling defect (star) at the junction of the descending colon and sigmoid colon.



Rectal contrast radiography: showed normal filling of the rectum with no filling defect however a filling defect was noted at the descending colon – sigmoid colon junction. The patient was then subjected to CT scan.

Figure 1d

Rectal contrast radiography lateral view shows the filling defect (star) at the junction of the descending and sigmoid colon

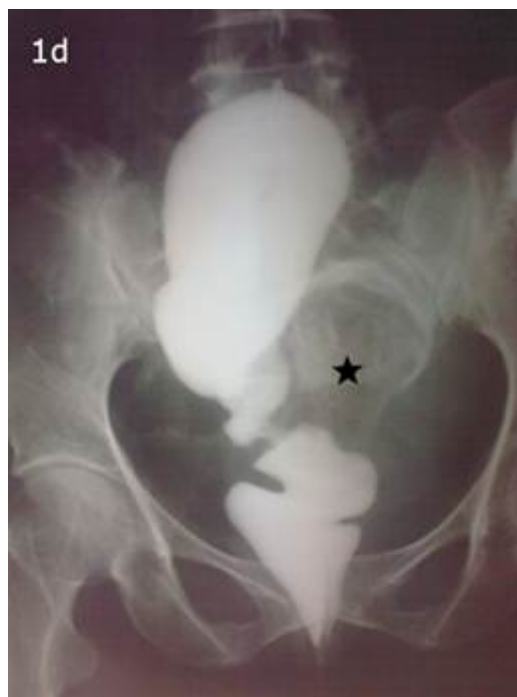
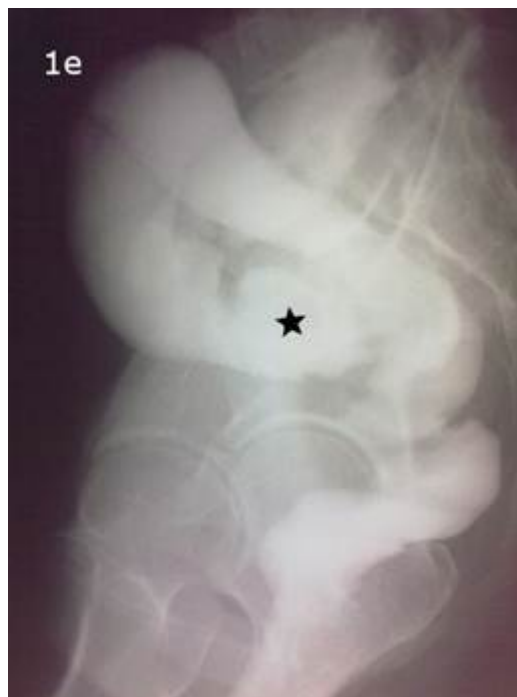
Figure 1e

CT scan axial section shows spongiform appearance of the gossypiboma (star). It is seen encroaching (arrowhead) the sigmoid colon causing filling defects.



CT scan findings: Contrast enhanced CT was performed

with per rectal instillation of diluted contrast (Iohexol). The axial section showed a heterogeneous lesion with both hypo and isodense foci giving a spongiform appearance with encroachment of the adjoining sigmoid colon causing filling defects. The lesion showed very close proximity to the small bowel giving rise to suspicion of bowel perforation. The entire spongiform appearing lesion measuring 10 x 2.5 cm with Hounsfield unit -156 was surrounded by isodense areas, probably due to granulation tissue. Parasagittal reformat image showed a hypo dense filling defect in the proximal sigmoid colon with areas of irregularity of lumen. With the possibility of Gossypiboma in mind an MRI scan was done.

Figure 1f

CT scan axial section shows the spongiform appearance of gossypiboma (star). It is seen encroaching (arrowhead) the sigmoid colon causing filling defects.

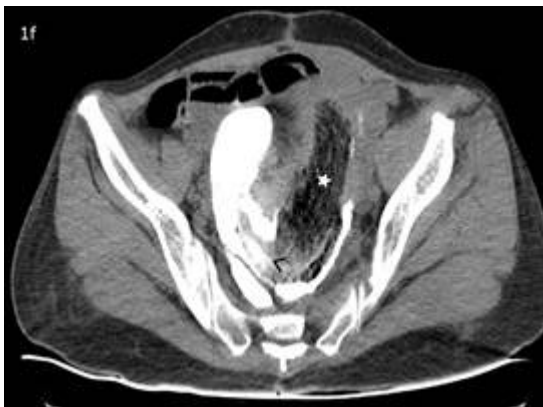

Figure 1g

CT scan coronal reformat shows the relationship of the Gossypiboma (star) with adjacent organs. The rectum is seen displaced to the right (arrowhead).

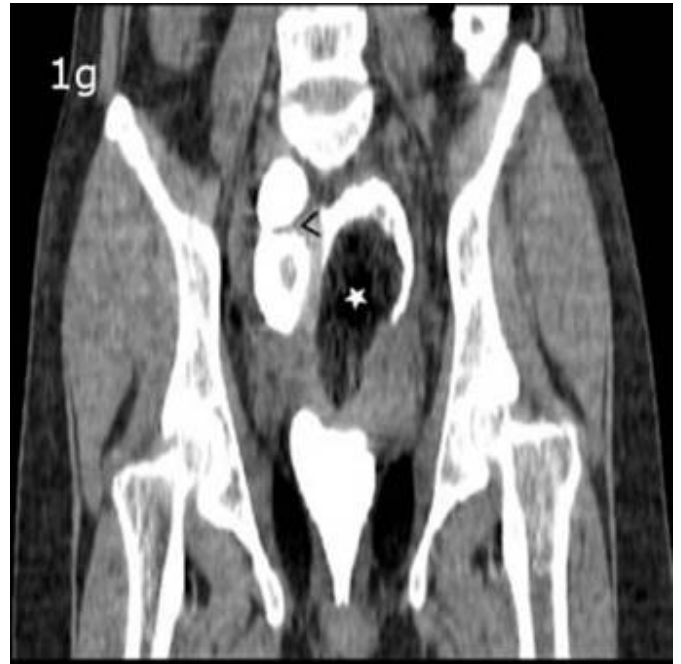

Figure 1h

CT parasagittal section shows large filling defect (star) in the proximal sigmoid colon with areas of irregularity in the wall (arrowhead).

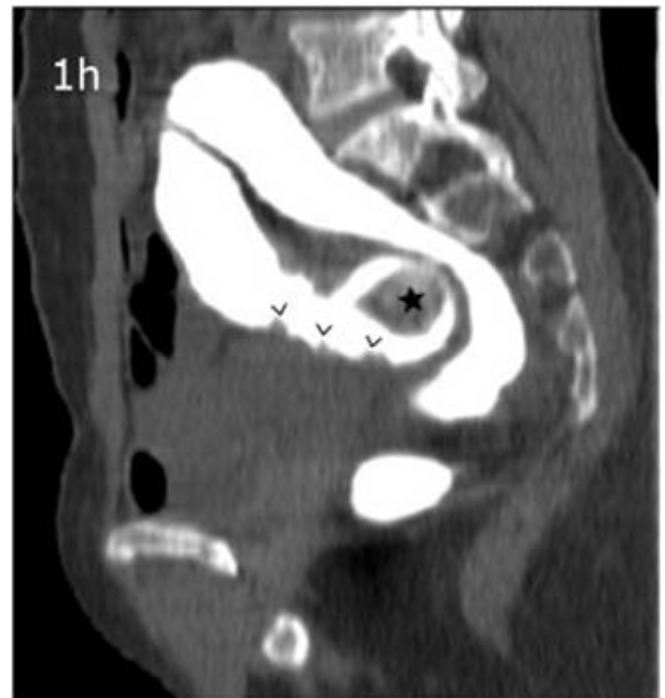
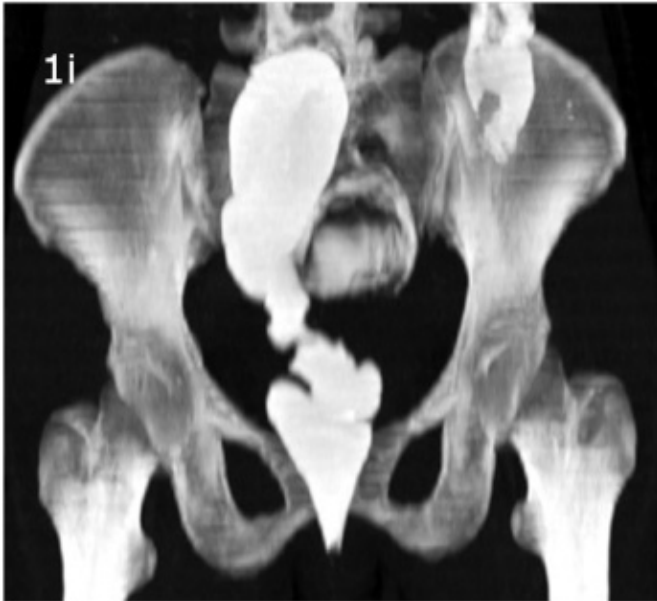
Figure 1i

3D reformat shows similar features as Rectal contrast Radiography.



MRI findings: Axial section - T2 weighted sequence showed the heterogeneous lesion encroaching the sigmoid colon surrounded by signal void due to air in the sigmoid colon. Axial section – T1 weighted showed the heterogeneous lesion which was predominately hypointense in signal intensity surrounded by an isointense area due to granulation formation. The lesion was seen displacing the rectum towards the right. Spair sagittal sequence showed lesion lying posterior to the uterus in pouch of Douglas surrounded by sigmoid air (signal void).

Figure 1j

MRI Axial section - T2WI. The gossypiboma (star) is seen encroaching the sigmoid colon surrounded by signal void due to air in the sigmoid colon.

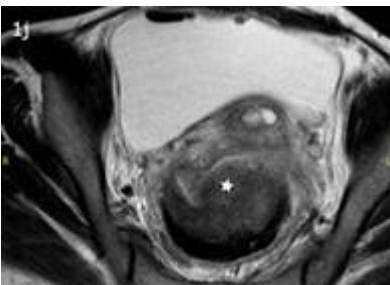
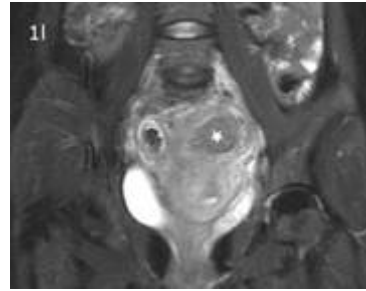


Figure 1k

MRI Axial section - T2WI. Gossypiboma (star) is seen encroaching the sigmoid colon surrounded by signal void due to air in the sigmoid colon

Figure 1l

MRI spair coronal shows relationship of the gossypiboma (star) with adjacent organs



Operative findings:

A mass was seen in the cul de sac with adjoining perforated ileum. The mass was also seen eroding the wall of the sigmoid colon encroaching the lumen. The adhesion was released and the gossypiboma was retrieved. Closure of bowel perforation with loop colostomy was done.

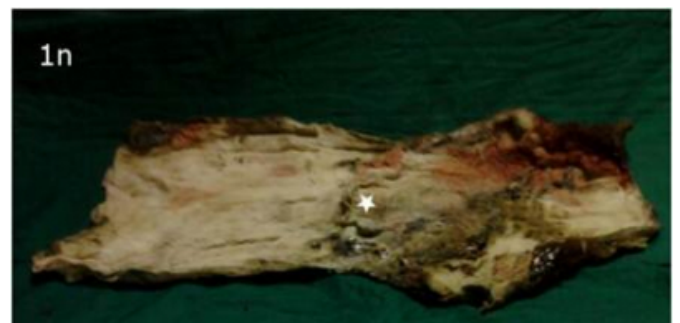
Figure 1m

Peroperatively a mass is seen in the cul de sac perforating and encroaching the lumen of the sigmoid colon with a small rent in the adjoining ileal segment.

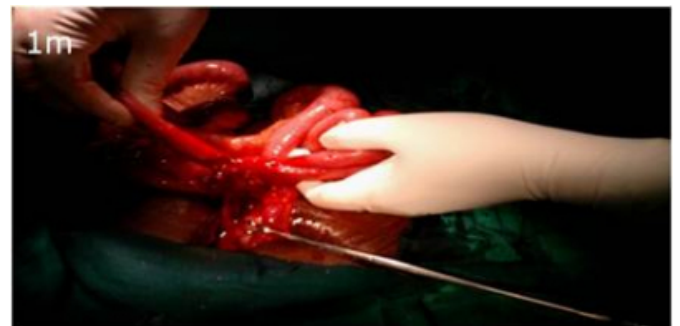

Figure 1n

Retrieved gossypiboma (star).



DISCUSSION

Gossypiboma is known to cause two major types of reactions. The acute inflammatory reaction presents as

abscess with or without secondary bacterial infection.

Chronic foreign body granulomatous type may present as an aseptic fibrinous response followed by tissue adhesion and encapsulation 4, 6. Finally a foreign body granuloma develops which may be asymptomatic for years. Clinically the patient may present with lower abdominal pain, discharging sinus, bowel obstruction, pseudotumour or sepsis 5, 6. At times they progressively enlarge over many years secondary to an indolent foreign body reaction with repetitive trauma and hemorrhage.

Other Imaging Appearances

PLAIN FILM: May often be normal or show a soft tissue mass. Radio opaque markers if present may be seen 5. A whorl-like appearance is also described which is secondary to gas trapped in fibers of sponge

ULTRASOUND: May show a complex mass or a cystic mass with irregular internal echoes. Usually a well-delineated mass containing a wavy internal echo with a hypoechoic ring and strong posterior acoustic shadowing may be seen 5.

CT: Low density, round, thick-walled mass or complex mass with areas of both low and medium density. Calcification may be occasionally seen. Spongiform gas is specific finding 6, 7, 8.

MRI: T2-weighted images- characteristic "folded fabric" internal structure of gauze granuloma 9.

CONCLUSION

A gossypiboma bears resemblance with a tumour and abscess. Clinical, as well as radiological presentations may vary and can be misleading. High degree of suspicion is required during imaging of post operative patients to make a diagnosis of gossypiboma as a delay in diagnosis can be

problematic.

ACKNOWLEDGEMENT:

I would like to express my gratitude towards the faculty of Department of Radiodiagnosis for their kind co-operation and encouragement which help me in completion of this project. I would like to convey my special gratitude and thanks to my parents, my wife and family members for giving me such attention and time. My thanks and appreciations also go to my colleague in completing the project.

References

1. Zbar AP, Agrawal A, Saeedi IT, et al. Gossypiboma revisited: a case report and review of the literature. *R Coll Surg Edinb* 1998; 43:417–418.
2. Kim HS, Chung TS, Suh SH, Kim SY (April 2007). "MR imaging findings of paravertebral gossypiboma". *AJNR Am J Neuroradiol* 28 (4): 709–13. PMID 17416826.
3. Kiernan F, Joyce M, Byrnes CK, O'Grady H, Keane FB, Neary P (December 2008). "Gossypiboma: a case report and review of the literature". *Ir J Med Sci* 177 (4): 389–91. doi:10.1007/s11845-008-0197-0
4. Bani-Hani KE, Gharaibeh KA, Yaghan RJ: Retained surgical sponges (gossypiboma). *Asian J Surg* 2005; 28:109-115.
5. Adonis Manzella1, Paulo Borba Filho, Eolo Albuquerque, Fabiana Farias, João Kaercher: Imaging of Gossypibomas: Pictorial Review. *AJR* 2009;193:S94–S101 0361–803X/09/1936–S94.
6. John R. Haaga, Vikram S. Dogra, MD, Michael Forsting, MD, PhD, Robert C. Gilkeson, Hyun Kwon Ha, MD. *CT and MR Imaging of the Whole Body*, 5th ed. United States: Mosby, An Imprint of Elsevier: 2008:2020-21.
7. Kalovidouris A, Kehagias D, Mouloupoulos L, et al: Abdominal retained surgical sponges: CT appearance. *Eur Radiol* 1999; 9:1407-1410.
8. Kokubo T, Itai Y, Ohtomo K, et al: Retained surgical sponges: CT and US appearance. *Radiology* 1987; 165:415-418.
9. H. Selim Karabekir, MD, Ahmet Yildizhan, MD, Elmas K. Atar, MD. Neurosurgical gossypiboma radiologically mimicking a lumbar abscess. *Neurosciences* 2007; Vol. 12 (2): 163-165.

Author Information

Ajit Kumar Reddy, Dr

Department of Radiology, Mahatma Gandhi Medical College and Research Institute Pondicherry
Pondicherry, INDIA
drajitreddy@gmail.com

Prakash Manikka Lakshmanan, Dr, MD, DMRD

Department of Radiology, Mahatma Gandhi Medical College and Research Institute Pondicherry
Pondicherry, INDIA
dr_praka_rad@yahoo.co.in

Ramkumar Govindarajalou, Dr, DMRD, DNB; MD

Department of Radiology, Mahatma Gandhi Medical College and Research Institute Pondicherry
Pondicherry, INDIA
gramk80@gmail.com

Annitha Jayamohan, Dr, MD

Department of Radiology, Mahatma Gandhi Medical College and Research Institute Pondicherry
Pondicherry, INDIA
anithaela@gmail.com