

Atypical Appendicitis: Schistosomal Infection Causing Perforated Appendicitis.

V Gundlapalli, M Shah, A Baskara, J Fobia

Citation

V Gundlapalli, M Shah, A Baskara, J Fobia. *Atypical Appendicitis: Schistosomal Infection Causing Perforated Appendicitis.* The Internet Journal of Surgery. 2012 Volume 28 Number 2.

Abstract

Appendicitis is the most common cause of surgical abdomen, with various unusual presentations. We present a case report of acute appendicitis secondary to Schistosomal infestation. We have reviewed the literature to comprehend the microbiology and the specific interventions needed for the management of this condition. Schistosomal infestation is a common tropical disease, but in view of extensive emigration and globalization, the incidence is increasing in the US and other western countries. Even though rare, it is still important to understand the natural history and know how to treat this disease. The patient was a 24-year-old female patient who emigrated from Liberia. She presented to the emergency room with abdominal pain. The clinical examination and imaging demonstrated acute perforated appendicitis. Emergency appendectomy was performed. The patient recovered uneventfully and was discharged the next day. The pathology report revealed acute suppurative appendicitis with numerous calcified parasites, consistent with Schistosomiasis. The patient was seen in the clinic the following week and appropriate treatment with Schistosomal antimicrobials was recommended. In this case report we reviewed the literature to give a synopsis of pathogenesis, microbiology and the management of Schistosomal appendicitis. We recommend having Schistosomal infection in the differential diagnosis of appendicitis, especially in patients from endemic areas or travelers from endemic areas.

INTRODUCTION

Schistosomiasis is a parasitic infestation caused by trematodes or flukes, such as *Schistosoma hematobium* (blood fluke), *Schistosoma mansoni*, *Schistosoma japonicum*. Schistosomiasis affects approximately 200 million people in 74 countries. Most affected people reside in sub-Saharan Africa where *Schistosoma mansoni*, *Schistosoma haematobium*, and *Schistosoma intercalatum* are endemic. *Schistosoma mansoni* is endemic in parts of South America and the Caribbean. *Schistosoma japonicum* is endemic in China, the Philippines, and Indonesia.¹ Turner first described Schistosomal appendicitis in 1909.² The incidence has been reported to be from 0.175% to 2%.^{2-4,7} Appendiceal Schistosomiasis is also described and can be a precursor lesion of Schistosomal appendicitis.^{4,6} In our case, the patient had Schistosomal obstructive acute appendicitis.

CASE REPORT

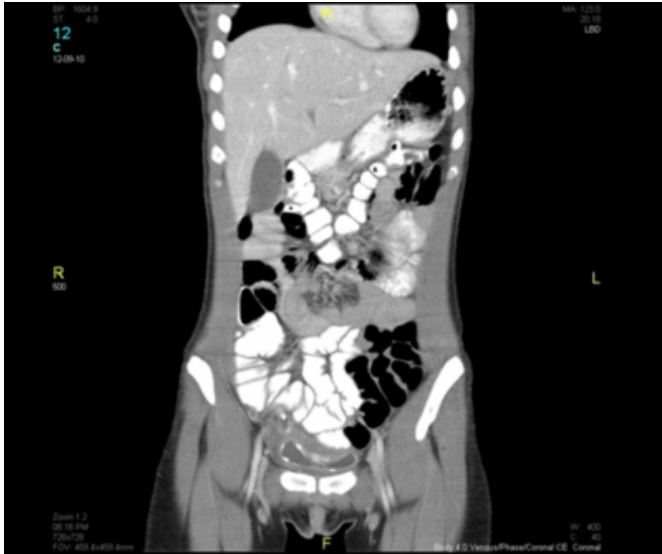The patient was a 24-year-old female who emigrated from Liberia. She presented to the emergency department of our institution, a community teaching hospital in Philadelphia, with abdominal pain going on for 7 days, which worsened over the last 24 hours prior to presentation. The pain,

primarily in the right lower quadrant, worsened with movement. Over the counter pain medications did not relieve the pain. She had episodes of low-grade fever and anorexia. She did have nausea, but no vomiting. She denied any changes in her bowel or bladder habits. She had her regular menstrual period 2 weeks ago. She claimed to be sexually active with one partner, with the use of contraception. She denied any significant past medical or surgical history. She was a teacher by profession, and denied the use of tobacco, alcohol or drugs.

On clinical examination she was afebrile, mildly tachycardic with a stable blood pressure. She had marked tenderness in her right lower quadrant, with a positive Rovsing's sign, and localized peritonitis. Blood work and urine analysis revealed no abnormal values. Urine pregnancy test was negative. She had a CT scan done in the emergency department, which demonstrated an inflamed and dilated appendix measuring 11mm in diameter, with surrounding fluid. There was free contrast around the urinary bladder, with findings consistent with perforation at the tip of the appendix. [Fig. 1]

Figure 1

Figure 1. CT scan showing perforated appendix with extraluminal contrast in the pelvis.



Our surgical team reviewed the patient, and after resuscitation the patient was taken to the Operating Room. An emergency open appendectomy was performed. Intraoperatively, an inflamed appendix with a perforation at its tip was noted. The abdomen was thoroughly irrigated with copious amount of warm saline solution. The wound was closed in layers. The skin was closed in a sparse interrupted fashion, and packed with gauze.

The patient's pain significantly improved a few hours after surgery. She was started on a liquid diet on the first postoperative day. Her pain was well controlled with oral pain medications. She was ambulating and was safely discharged on postoperative day one, with home care arranged for daily dressing changes. She was advised to follow up in the Surgery clinic within a week.

The course of events described above is a routine case of appendicitis. The case got interesting when the pathologist informed the attending surgeon of the following findings: acute suppurative appendicitis with numerous calcified parasites, consistent with Schistosomiasis. [Fig. 2 and 3]

Figure 2

Figure 2. Acute suppurative appendicitis with numerous calcified parasites.

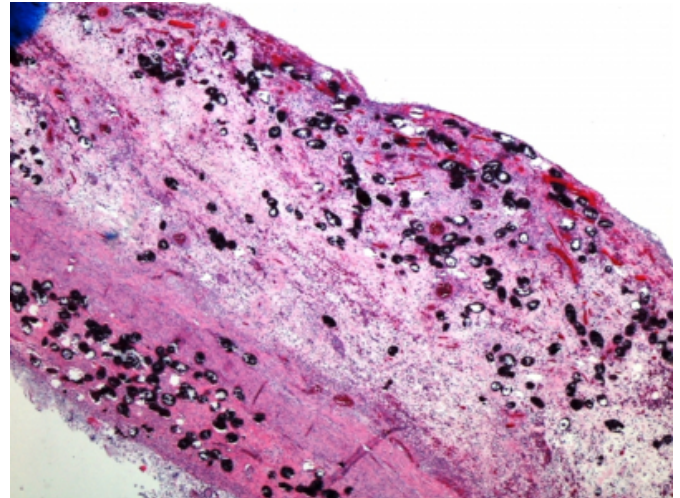
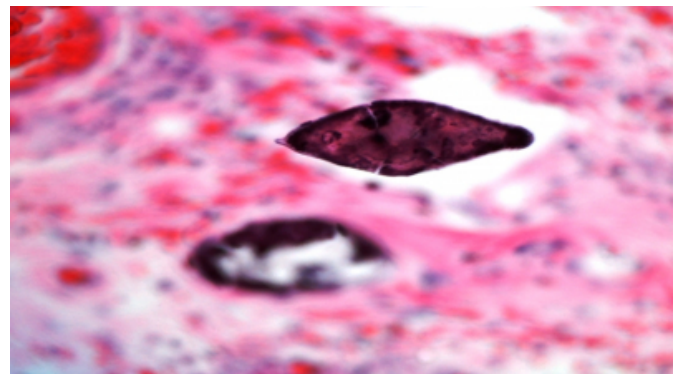


Figure 3

Figure 3: Magnified view showing a calcified parasite.



One week later, the patient was seen in the clinic. She had completely recovered from the operation, and was comfortably performing her daily activities. Her wound looked healthy. She was made aware of the pathology report, and appropriate antimicrobials were recommended for eradication of the infestation.

DISCUSSION

Schistosomiasis or Bilharzia is a tropical parasitic disease caused by blood-dwelling fluke worms of the genus *Schistosoma*. The main schistosomes infecting human beings are: *S. haematobium*, *S. japonicum*, *S. mansoni*, *S. intercalatum*, and *S. mekongi*.²³ In the USA, the incidence of Schistosomal appendicitis is 0.2% (3/1690) of surgically resected cases. All the three cases occurred in African Americans.⁷ Hence, it is preferentially found in travelers or population from an endemic area. In a retrospective study from Nigeria, Schistosome eggs were seen in histological

sections of 27 (2.3%) from more than thousand cases of appendicitis.²² About 56% of these cases were caused by *S. mansoni*, 26% by *S. haematobium*, and 19% by *S. mansoni*/*S. haematobium* coinfection.⁸

The pathogenesis of Schistosomal appendicitis has been described as from 1 of 2 mechanisms. The first mechanism is Schistosomal obstructive acute appendicitis, believed to be a result of fibrosis around eggs leading to obstruction followed by bacterial infection. This mechanism presents pathologically with no tissue eosinophils or granulomas. This is seen more often in the late stages of infection. The second mechanism is Schistosomal granulomatous acute appendicitis, believed to be a result of immunological granulomatous reactions to newly deposited eggs. This mechanism presents pathologically with tissue necrosis leading to perforation. These patients have tissue granulomas and eosinophilia. This mechanism is seen more often in the early stages of infection.⁴

A critical appraisal of the association between Schistosomiasis and acute appendicitis is reported from the histological findings, characterized by infiltrations of the submucosal and the muscular layer by polymorphonuclear leukocytes, in addition to the presence of Schistosome eggs.⁹ In the case of *Schistosoma mansoni*, intramuscular oviposition may cause an obstructive type of appendicitis with a greater risk of perforation.¹⁰ Serosal involvement causes inflammation and the formation of adhesions.¹⁰ It has recently been shown that intestinal Schistosomiasis in an animal model results in structural, functional and immunological changes in the affected colon, most notably decreased GI transit and increased colonic contractility¹¹.

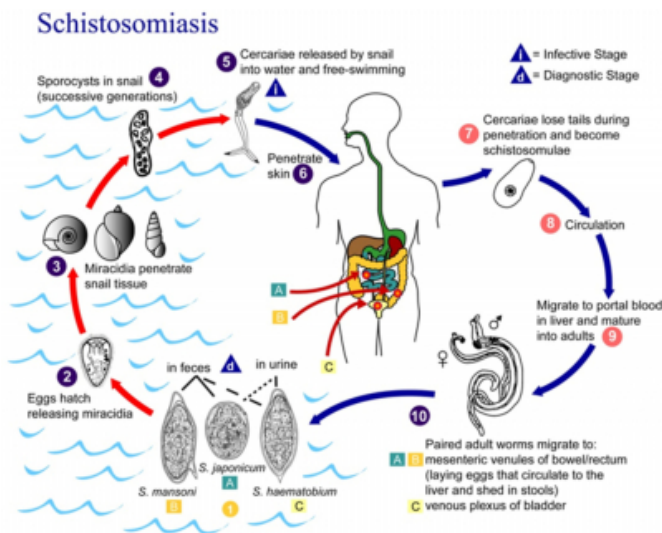
The life cycle of Schistosomal appendicitis is as follows [Fig. 4]: People come into contact with the parasite during normal everyday activities such as washing clothes, bathing or swimming (especially carrying out these activities in running fresh water in developing countries). The parasites enter the body through the skin and take about 3 days to reach the blood capillaries under the skin. Over the next 7 days or so, the parasites migrate in the blood system from the skin to the lungs, the heart and eventually the liver. Once in the liver, they mature into adult worms and form male:female pairs. This process takes about 45 days. The adult worm pairs then migrate to their final resting site. Of the two main types of blood fluke which infect humans, one preferentially migrates to the veins surrounding the bladder and the other migrates to the veins surrounding the small and

large intestines. The average life-span of an adult worm inside the human body is 5 years, but can be up to 20 years. Throughout this period a single female worm will release approximately 300 eggs per day into the blood stream. The eggs released from worms located near the bladder penetrate the bladder wall and are voided in urine. The eggs released from worms located in the intestinal blood supply penetrate the intestine walls and exit in the feces. However, about 50% of the eggs become trapped in the body and are responsible for the damage done to the intestines, the bladder and other organs. Note that it is the eggs and not the adult worms that are responsible for the symptoms of Schistosomiasis. Eggs that are eliminated from the body have the potential to develop into mature blood flukes and continue the cycle of infection. Those eggs that reach suitable fresh water conditions hatch to release an intermediate life cycle stage, miracidia which actively search for a suitable snail host to infect. The miracidium enters the snail through the head and/or foot, and undergoes a process of multiplication and development in the digestive gland of the snail. The resulting final forms of the parasite, the cercariae, migrate to the mantle from where they escape into fresh water. This stage of the lifecycle inside the snail host takes between 4-6 weeks. One snail can release up to three thousand mature cercariae per day. Each of these is capable of infecting a single person. The cercariae remain viable for up to 48 hours in fresh water. To continue the cycle of infection, the cercariae must successfully penetrate the human skin exposed in the water within this time. And the cycle continues.

Figure 4

Figure 4: Schistosomiasis Life Cycle (This image is a work of the United States Department of Health and Human Services, taken or made during the course of an employee's official duties. As a work of the U.S. federal government, the image is in the public domain.

File:Schistosomiasis_Life_Cycle.jpeg licensed with PD-USGov-HHS)



We strongly believe that once the histological confirmation is obtained as Schistosomiasis appendicitis, the patient should be treated for Schistosomiasis, owing to the long life span of a Schistosome in the human body, in order to prevent other organ damage by the parasite.

TREATMENT

Schistosomal infections can be treated easily with economical drugs. The mainstay of treatment is Praziquantel (PZQ). Praziquantel, an acylated quinoline-pyrazine that is active against all Schistosome species, is now the most widely used. It is typically marketed as 600mg tablets, with a recommended standard regimen of 40mg/kg bodyweight in a single dose.¹² The drug acts within 1 hour of ingestion, by paralyzing the worms and damaging the integument. This leads to loss of the worm's attachment to the endothelium of the vessel wall. They are swept to the liver, where they are attached by the phagocytes, granulocytes and cell-mediated immune cells. Thus, the host's immune response appears strongly implicated in the mode of action of PZQ.¹⁹ PZQ has very low toxicity in animals, and no significant long-term safety difficulties have been documented in people so far.¹⁰ It is judged safe for treatment of young children and pregnant women.¹⁶ After a single dose of 40 mg/kg, 70–100% of patients cease to excrete eggs. In most of those not cured, egg counts and antigen concentrations are reduced by more

than 95%.¹⁵⁻¹⁷ PZQ has little or no effect on eggs and immature worms. Tissue-dwelling eggs can be excreted for several weeks after treatment, and during the same period immature worms or newly acquired infections can become productive. The preferred timing of follow-up is therefore 4–6 weeks after treatment.¹⁸ A repeat dose 6-12 weeks later can be useful to cure resurgent infections, particularly if there is eosinophilia, high antibody titers, or if symptoms persist.

The other anti-Schistosomal drugs include Metrifonate (for *S. haematobium*), Oxamniquine (for *S. mansoni*)^{13, 14}: both of these drugs are not used as extensively as PZQ due to their lower cure rate, need for frequent dosing, side effects, as well as higher costs. Artemisinin derivatives are effective against the immature stages of *S. japonicum*, *S. mansoni*, and possibly *S. haematobium*.²⁰ Their use in cure or prophylaxis for acute Schistosomiasis, possibly in combination with PZQ, is being investigated.²¹ There is an ongoing research for newer anti-Schistosomal medications, as drug resistance to the one main drug has been documented and can be a problem in the future. Much effort has been devoted to the development of vaccines against Schistosomiasis. Several antigens are judged to be potential vaccine candidates and have been tested in animals with varying results.^{24, 25} The recombinant rShGST-28 (Bilhvax; Eurogentec, Herstal, Belgium) has already undergone phase I and II clinical trials.²⁶

CONCLUSION

Schistosomal appendicitis is very rare in the United States and the western world. We strongly recommend that physicians in the US and western hemisphere should be aware of the condition and have high index of suspicion, especially in patients emigrated from the endemic areas or travelers from endemic areas.

References

1. Chitsulo L, Loverde P, Engels D: Schistosomiasis. *Nat Rev Microbiol*; 2004; 2: 12-13.
2. Hodasi WM: Schistosoma appendicitis. *Trop Doct*; 1988; 18: 105-106.
3. Chan KW, Fu KH, Ling J: The pathology of the appendix in Hong Kong. *Br J Clin Pract*; 1988; 42: 241-244.
4. Satti MB, Tamimi DM, Al Sohaibani MO, Al Quorain A: Appendicular schistosomiasis: a cause of clinical acute appendicitis? *J Clin Pathol*; 1987; 40: 424-428.
5. Adebamowo CA, Akang EE, Ladipo JK, Ajao OG: Schistosomiasis of the appendix. *Br J Surg*; 1991; 78: 1219-1221.
6. Marks C: Schistosomiasis and its surgical sequelae. *Am J Surg*; 1966; 111: 805-812.
7. Nandipati K, Parithivel V, Niazi M: Schistosomiasis: a rare cause of acute appendicitis in the African American

- population in the United States. *Am Surg*; 2008; 74: 221-223.
8. Gali BM, Nggada HA, Eni EU: Schistosomiasis of the appendix in Maiduguri. *Trop Doctor*; 2006; 36: 162-3.
9. Badmos KB, Komolafe AO, Akintola L, Rotimi O: Schistosomiasis presenting as acute appendicitis. *East Afr Med J*; 2006; 83: 528-32.
10. Adebamowo CA, Akang EEU, Ladipo JK, Ajao OG: Schistosomiasis of the appendix. *Br J Surg*; 1991; 78: 1219-12.
11. El Zawawy LA: Effect of *Schistosoma mansoni* infection on physiological gastrointestinal transit and contractility. *J Egypt Soc Parasitol*; 2006; 36(3): 1057-70.
12. WHO Expert Committee: Prevention and control of schistosomiasis and soil-transmitted helminthiasis. Technical report series. Geneva: World Health Organisation, 2002.
13. Shekhar KC: Schistosomiasis drug therapy and treatment considerations. *Drugs*; 1991; 42(3): 379-405.
14. Cioli D: Chemotherapy of schistosomiasis: an update. *Parasitol Today*; 1998; 14(10): 418-22.
15. Stelma FF, Talla I, Sow S, et al.: Efficacy and side effects of praziquantel in an epidemic focus of *Schistosoma mansoni*. *Am J Trop Med Hyg*; 1995; 53: 167-70.
16. WHO: Report of the WHO informal consultation on the use of praziquantel during pregnancy/lactation and albendazole/mebendazole in children under 24 months (WHO/CDS).
17. Utzinger J, N'Goran EK, N'Dri A, Lengeler C, Tanner M: Efficacy of praziquantel against *Schistosoma mansoni* with particular consideration for intensity of infection. *Trop Med Int Health*; 2000; 5: 771-78.
18. Renganathan E, Cioli D: An international initiative on praziquantel use. *Parasitol Today*; 1998; 14: 390-91.
19. Doenhoff MJ, Cioli D, Utzinger J: Praziquantel: mechanisms of action, resistance and new derivatives for schistosomiasis. *Curr Opin Infect Dis*; 2008; 21(6): 659-67.
20. Xiao SH, Tanner M, N'Goran EK, et al.: Recent investigations of artemether, a novel agent for the prevention of schistosomiasis japonica, mansoni and haematobia. *Acta Trop*; 2002; 82: 175-81.
21. Utzinger J, Keiser J, Shuhua X, Tanner M, Singer BH: Combination chemotherapy of schistosomiasis in laboratory studies and clinical trials. *Antimicrob Agents Chemother*; 2003; 47: 1487-95.
22. Mazigo HD, Giiti GC, Zinga M, Heukelback J, Rambau P: Schistosomal peritonitis secondary to perforated appendicitis. *Braz J Infec Dis*; 2010; 14(6): 628-630.
23. Gryseels B, Polman K, Clerinx J, Kestens L: Human schistosomiasis. *Lancet* 2006; 368: 1106-18.
24. Bergquist RN, Colley DG: Schistosomiasis vaccine: research to development. *Parasitol Today* 1998; 14: 99-104.
25. Hewitson JP, Hamblin PA, Mountford AP: Immunity induced by the radiation-attenuated schistosome vaccine. *Parasite Immunol*; 2005; 27: 271-80.
26. Capron A, Riveau G, Capron M, Trottein F. Schistosomes: the road from host-parasite interactions to vaccines in clinical trials. *Trends Parasitol* 2005; 21: 143-49.

Author Information

Vinay S Gundlapalli, M.R.C.S., M.D.

Surgical Resident, Mercy Fitzgerald Hospital, Mercy Catholic Medical Center

Mihir M Shah, M.D.

Surgical Resident, Mercy Fitzgerald Hospital, Mercy Catholic Medical Center

Arun Baskara, M.R.C.S., M.D

Surgical Resident, Mercy Fitzgerald Hospital, Mercy Catholic Medical Center

John B Fobia, M.D., F.A.C.S.