

# Primary Splenic Hydatidosis: A Case Report

M Mir, R Mir, M Manzoor, B Bali

## Citation

M Mir, R Mir, M Manzoor, B Bali. *Primary Splenic Hydatidosis: A Case Report*. The Internet Journal of Tropical Medicine. 2012 Volume 8 Number 1.

## Abstract

Hydatid disease is a zoonotic parasitic infection caused mainly by *Echinococcus granulosus* and is a common disease in this part of the world. However, primary splenic hydatidosis is rare. A case is described in a 45 year old female who presented with left upper quadrant swelling and pain. Ultrasonography revealed a hydatid cyst towards upper pole of spleen. A Computed Tomography confirmed the primary splenic hydatid cyst of 7.5cm × 7cm without internal septations and calcification. Serological tests were positive for hydatid disease. An elective splenectomy was performed successfully.

## INTRODUCTION

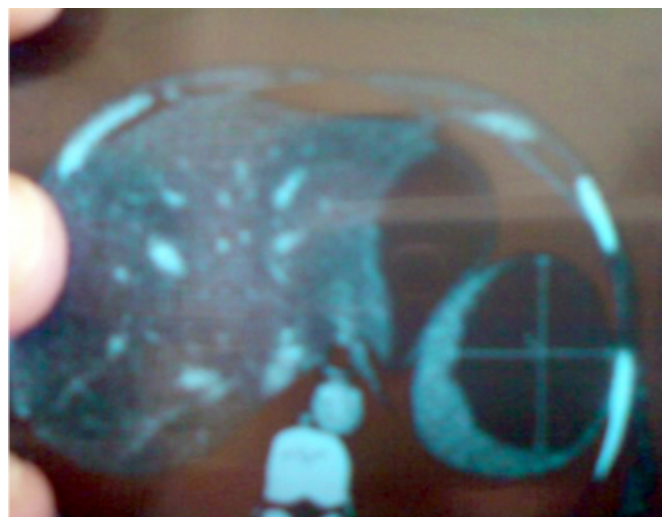
Hydatid disease is common in sheep rearing areas. A hydatid disease is a zoonotic illness and a significant problem in endemic areas. Hydatid cyst, is caused by *Echinococcus* infestation. Humans are the accidental intermediate hosts. After ingestion, the eggs hatch and oncospheres penetrate the intestinal mucosa and enter the circulation. The embryos are carried to the liver to be arrested in the sinusoidal capillaries (first filter). Some of the embryos may pass through the hepatic capillaries and enter the pulmonary circulation and filter out in the lungs (second filter). Rarely a few embryos may pass through the pulmonary capillaries, and enter the general blood stream and lodge in the various organs. Wherever the embryo settles, it forms a hydatid cyst. The life span of larval worm is considerable and it may continue to develop for many years<sup>1</sup>. Liver and lungs are the organs most commonly affected. Primary infestation of the spleen by the parasite is rare.

## CASE REPORT

A 45 year old rural married female from north Kashmir, with no significant past medical history presented with 12 weeks history of progressively increasing upper abdominal swelling and pain. General physical examination of patient was normal. Abdominal examination revealed splenomegaly. Ultrasonography revealed a hydatid cyst towards upper pole of spleen. A Computed Tomography confirmed the primary splenic hydatid cyst of 7.5cm × 7cm without internal septations and calcification and computed tomography also confirmed the absence of cysts in the liver, lungs or kidney [Fig 1].

## Figure 1

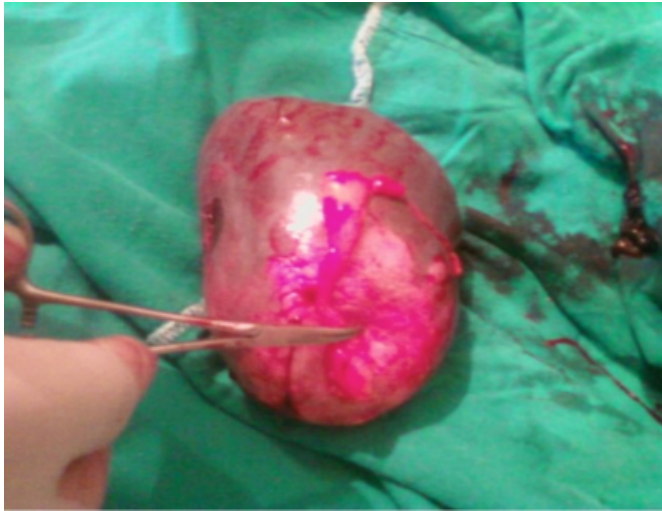
Fig 1: primary hydatidosis of spleen upper pole



Serological tests were positive for hydatid disease. Splenectomy was performed by left upper transverse incision. There were omental adhesions over spleen. After careful adhesiolysis splenectomy was performed successfully. Splenectomy specimen also confirmed the hydatid cyst towards the upper pole [Fig 2].

### Figure 2

Fig 2: splenectomy specimen showing hydatid cyst upper pole



Postoperative stay in the hospital was uneventful and the patient was discharged on 7<sup>th</sup> postoperative day. The patient was in good health at 1, 2 and 3 months of follow up.

### DISCUSSION

Primary involvement of spleen is rare. Berlott (1790) was the first to describe splenic hydatidosis as an autopsy finding<sup>2</sup>. It is endemic in sheep rearing areas of Mediterranean, Eastern Europe, Australia, South America and Middle East. Most common organs involved are liver and lungs. Involvement of the spleen is a rarity. The incidence varies widely in sheep rearing countries with maximum reported from Iran (4%)<sup>3</sup>. In India maximum incidence of splenic hydatidosis has been reported from Nagpur<sup>2</sup>. In various series on Splenic hydatidosis from our state an incidence of 3.5 % and 4.1% has been reported<sup>4,5</sup>. Parasitic cysts of the spleen are almost exclusively hydatid cysts. In endemic areas, 50%-80% of splenic cysts are echinococcal<sup>6</sup>. Splenic hydatid cysts are generally asymptomatic and they are diagnosed incidentally while evaluating such patients for other reasons. When the cyst attains a considerable size the patient becomes symptomatic and mostly presents with painful left upper abdominal mass<sup>7,8</sup> as was the presentation with our patient. If the cyst gets infected patient may present with fever and leucocytosis<sup>9</sup>. Sometimes the patient may also present with fatal anaphylactic reaction due to the free intra peritoneal rupture of the cyst<sup>10</sup>. Due to the constant risk of this dreadful complication, there is an absolute indication of splenic hydatid cysts, especially large ones to be treated surgically<sup>10,11</sup>. The standard treatment option is total or

partial splenectomy<sup>6</sup>. In our case we preferred open total splenectomy. The literature also favors such treatment modality<sup>12</sup>. Complications of splenectomy such as hemorrhage, pancreatic or gastric injuries, thromboembolic phenomena and overwhelming post splenectomy infections (OPSI) are reviewed in literature<sup>13,14</sup>. None of such complications occurred in our patient. Due to the risk of OPSI (approx 10%) some authors advocate conservative approach to be adopted in splenic surgery. However it is suggested that spleen sparing surgery can be done if there is adequate amount of splenic parenchyma remaining<sup>12</sup>. With the advance in laparoscopic surgery, laparoscopic splenectomy is being increasingly performed at advanced laparoscopic centers. Though some authors find it safe and effective alternative to open splenectomy, while as others believe that it is unsafe to approach splenic hydatid laparoscopically due to the risk of anaphylactic shock and intraperitoneal dissemination, which can occur subsequent to uncontrolled puncturing of the cyst<sup>7,13,15,16</sup>.

### CONCLUSION

We conclude that Splenic Hydatidosis although rare should always be kept in mind while dealing with cystic lesions of the spleen especially in endemic areas. Splenectomy remains the favored surgical procedure.

### References

1. Chatterjee KD. Parasitology, protozoology & Helminthology. 12th Ed. Chatterjee Medical Publishers. 1980. Pg 122.
2. Muro J et al. demonstration angiographica del quiste hidatidico de bazo. Rev Clin Esp 1969;115:433-438.
3. Torbati M. Hydatid disease of spleen. Report of an unusual case. Br J Surg 1972;59:489-91.
4. Dar MA et al. Surgical management of splenic hydatidosis. Surgery today. 32:(3): March 2002 page 224-229.
5. Wani NA. Hydatid disease of spleen. Ind J Surg 1993;55(3):155-160.
6. Gharaibeh KI. Laparoscopic excision of splenic hydatid cyst. Postgrad Med J 2001;77:195-196.
7. Ratych RE et al. Tumours, cysts and abscesses of spleen. In Cameroon JL (ed): Current Surgical Therapy, 4th Ed. St Louis Mosby. 1992;518-521.
8. Uriarte C: Splenic hydatidosis. Am J Trop Med Hyg 1991;44:4209-4239.
9. Franquet T et al. Abscessed splenic hydatid cyst: Sonographic & CT findings. Clin Imag 1991;15:118-120.
10. Gunay K et al. Traumatic rupture of hydatid cysts. A 12 year experience from an endemic region. Trauma 1999;46:164-167.
11. Wolf O et al. Cystische Echinokokkose der milz. Chirurg 1998;69: 208-211.
12. Durgan V et al. Primary splenic hydatidosis. Dig Surg 2003;20: 38-41.
13. Beauchamp RD et al. Spleen. Sabiston Textbook of Surgery. 16 Ed. WB Saunders. 2001. Pg 1144-1165.
14. Ellison EC. Complications of Splenectomy: Etiology, prevention & management. Surg Clin North Am

1983;63:1313.

15. Ammann RW et al. Cestodes. Echinococcus. Gastro

Clin North Am 1996;25:655 - 689.

16. Khoury G et al. Laproscopic treatment of hydatid cysts of liver and spleen. Surg Endosc 2000; 14: 243-245.

**Author Information**

**Mohd Altaf Mir, MS**

Registrar, Govt. Medical College

**Reyaz A Mir, MD**

Registrar, Govt. Medical College

**Mohsin Manzoor, MS**

Registrar, Govt. Medical College

**Biant Singh Bali, MS**

Associate Professor, Govt. Medical College