

Adult Nigerian With Untreated Tetralogy Of Fallot- A Case Report

U D.I., J D. E.

Citation

U D.I., J D. E.. *Adult Nigerian With Untreated Tetralogy Of Fallot- A Case Report* . The Internet Journal of Cardiology. 2012 Volume 10 Number 2.

Abstract

Background: Tetralogy of Fallot (TOF) is the most common form of cyanotic congenital heart .. Unlike in the western world where adult TOF is a rarity, in the developing countries without cardiac surgical centers and inadequate medical treatment, patients die early so adult untreated TOF is worth reporting.

A 23 year old man presented with chest pains of 18 months, exertional dyspnea, palpitations and a history of squatting since childhood. Examination revealed central cyanosis, grade 4 digital clubbing, with pansystolic and ejection systolic murmurs over tricuspid and pulmonary areas.

RESULTS : Chest radiograph, Electrocardiogram (ECG) and Echocardiograms confirmed Tetralogy of Fallot

INTRODUCTION

Tetralogy of Fallot (TOF), first described in 1888, comprises a ventricular septal defect (VSD), right ventricular outflow tract obstruction, an overriding aorta, and right ventricular hypertrophy (RVH).¹ It is the most common form of cyanotic congenital heart disease. Since the first surgical procedures for repair of TOF in the 1950s, advances in the diagnosis, perioperative and surgical treatment, and postoperative care have been such that almost all those born with tetralogy of Fallot can now expect to survive to adulthood.² Some patients do survive into adulthood without surgical treatment and these patients develop complications and require unique management based on their individual anatomy and physiology.³ We report a 23 year old university student with untreated TOF.

CASE REPORT

A 23 year old university student with a history of cyanosis since childhood presented with complaints of chest pains of 18 months duration. Chest pain was retrosternal, sharp in character, non-radiating, aggravated by strenuous activities and transiently relieved with rest and taking analgesia. There was a history of dyspnea on exertion and effort intolerance since childhood.. He admitted to frequent squatting to relief episodes of breathlessness following moderate exertion. There was also a history of occasional palpitations lasting about five minutes and associated with dizziness and one episode of a syncopal attack. No history of cough, leg

swelling, frothy urine, nocturia or oliguria. General examination revealed an asthenic plethoric patient , centrally cyanosed with grade 4 digital clubbing. His pulse was regular with a rate of 80 beats per minute. Blood pressure was 120/70 mmHg. On examination of the precordium, the apex was not displaced, and he had palpable systolic thrills over the left sternal border and pulmonary areas. A soft first heart sound and a pansystolic murmur over the left parasternal area and an ejection systolic murmur over the pulmonary area were heard. The lungs were clear. Abdomen was normal. Chest radiograph showed an enlarged boot shaped heart with pulmonary oligemia. Electrocardiogram revealed sinus rhythm, normal PR interval, right QRS axis deviation, right atrial enlargement, right ventricular hypertrophy and inverted T-waves in the anterior and inferior leads.

The echocardiogram revealed a non-restrictive ventricular septal defect with a large aortic override. The left ventricular systolic function was impaired (EF= 48.8%, FS= 23.3%) with right ventricular hypertrophy and grade 1 right ventricular diastolic dysfunction. There was no aortic or mitral regurgitation.

The packed cell volume was 72% and a blood film showed relative polycythemia. A final diagnosis of TOF was made and patient was placed on beta-blockers and low dose aspirin. He has also had serial venesection to reduce his packed cell volume with slight improvement in symptoms.

He requires total intra-cardiac repair.

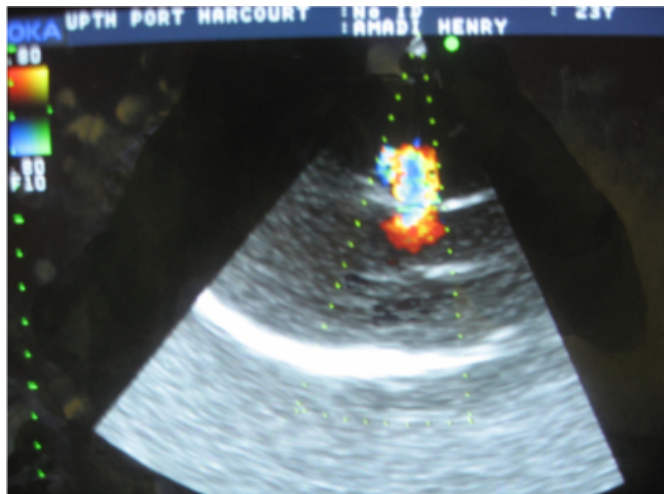
Figure 1

FIGURE 5: 2-D echo showing the ventricular septal defect and the huge overriding aorta.

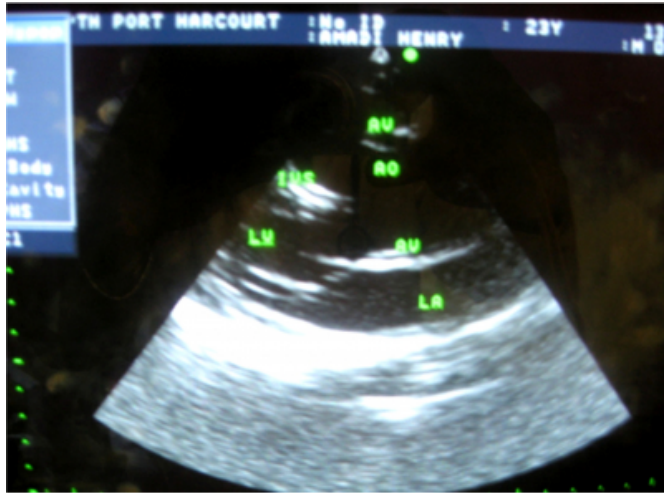

Figure 2

FIGURE 9: Colour flow study showing turbulence across the ventricular septal defect.



DISCUSSION

Tetralogy of Fallot occurs in 3 of every 10,000 live births. It is the commonest cause of cyanotic cardiac disease in patients beyond the neonatal age, and accounts for up to one-tenth of all congenital cardiac lesions.⁴ The etiology is multifactorial, but reported associations include untreated maternal diabetes, phenylketonuria, and intake of retinoic acid. Associated chromosomal anomalies can include trisomies 21, 18, and 13, but recent experience points to the much more frequent association of micro-deletions of chromosome 22. The risk of recurrence in families is 3%.⁴

There are three main reasons for the longevity in natural survivors with un-operated TOF. Firstly, a hypoplastic pulmonary artery with slow development of sub-pulmonary obstruction.⁵ A second common feature is that of left ventricular hypertrophy; presumably this acts by delaying of shunting from the right to left ventricle.⁶ LVH may be a late development in the natural history of TOF and any beneficial effect may not be seen until adult life. The third finding in other cases have been extra-cardiac shunts including patent ductus arteriosus⁷—reported in the oldest survivor who died at age 77⁸—or systemic to pulmonary artery shunting via aorto-pulmonary collaterals.

The treatment for TOF is either palliative using the Blalock-Tausig shunt or definitive with total intra-cardiac repair. Untreated TOF or patients treated late have various complications. The Mayo series on the outcome of 30 TOF patients, aged 40 to 60 years who had total correction throws some light.⁹ The operative mortality was 3% with long term survival rate at 5 years and 10 years postoperatively of 92% and 74% respectively. Eight patients (27%) had had preoperative complications. Five had a cerebro-vascular disease (CVD) and three had infective endocarditis. Two days post-operatively, one patient died from ventricular fibrillation while one had complete heart block. Another patient had CVD 7 days post-operatively. Though this patient has not had surgery, current techniques for total surgical repair greatly improve the hemodynamic functions of the heart of TOF patients. They however do not provide a lifetime correction of the defect. Ninety percent of patients with total repair as infants develop a progressively leaky pulmonary valve as the heart grows to its adult size. Patients also may have some degree of residual right outflow stenosis and damage to the electrical system of the heart from surgical incisions, causing abnormalities as detected by electrocardiogram and/or arrhythmias.¹⁰

Untreated, TOF rapidly results in progressive right ventricular hypertrophy due to the increased resistance on the right ventricle. This progresses to heart failure (dilated cardiomyopathy) which begins in the right heart and often leads to left heart failure. Actuarial survival for untreated TOF is approximately 75% after the first year of life, 60% by four years, 30% by ten years, and 5% by forty years.¹⁰

CONCLUSION

TOF can be corrected surgically with improved outcomes among patients. Effort should be made on our part as health workers to identify these patients early enough so that they

can benefit from corrective surgery to prevent late complications and poor quality of life.

References

1. Fallot ELA. Contribution à l'anatomie pathologique de la maladie bleue (cyanose cardiaque). Marseille Médical; 1888;25:77-93, 138-158, 207-223, 341-354, 370-386, 403-420.
2. Apitz C, Webb GD, Reddington AN. Tetralogy of Fallot. Lancet; 2009;374:1462-1471
3. Huehnergarth KV, Gurvitz M, Stout KK, Otto CM. Repaired tetralogy of Fallot in the adult: monitoring and management. Heart; 2008; 94:1663-1669
4. Bailliard F, Anderson RH. Tetralogy of Fallot . Orphanet J Rare Dis. 2009;4:2.
5. Meindok H. Longevity in the Tetralogy of Fallot. Thorax; 1964; 19:12-15.
6. Bowie EA. Longevity in Tetralogy and Triology of Fallot. Discussion of cases in patients surviving 40 years and presentation of two further cases. Am Heart J; 1961;62:125-132.
7. Nottestad SY, Slife DM, Rubal BJ. Tetralogy of Fallot in a 71 year old patient with new onset hypoxemia. Cathet Cardiovasc Diagn; 1993; 28:335-338.
8. Thomas SHL, Bass P, Pambakian H. Cyanotic tetralogy of Fallot in a 77 years old man. Postgrad Med J; 1987; 63:361-362.
9. Hu DCK, Seward JB, Puga FJ. Total correction of tetralogy of Fallot at age 40 years and older: long-term follow-up. J Am Coll Cardiol; 1985; 5:40-44.
10. Bertranou EG, Blackstone EH. Life expectancy without surgery in tetralogy of Fallot. Am J Cardiol; 1978; 42:458-466.

Author Information

Uchenna D.I., MBBS, FWACP, FMCP

Department of Internal Medicine, University of Port Harcourt Teaching Hospital

Jesuorobo D. E., MBBS

Department of Internal Medicine, University of Port Harcourt Teaching Hospital