

A Case Review of Atypical Presentation of Pulmonary Hypertension

M Rasool, D Bhatt, B Lakshminarayanan, J A Jokela

Citation

M Rasool, D Bhatt, B Lakshminarayanan, J A Jokela. *A Case Review of Atypical Presentation of Pulmonary Hypertension*. The Internet Journal of Infectious Diseases. 2013 Volume 12 Number 1.

Abstract

Background: Pulmonary Arterial Hypertension (PAH) is a rare but fatal complication of human immunodeficiency virus (HIV) exposure. PAH can complicate the course of HIV infection regardless of the stage of HIV infection, route of transmission and degree of immunosuppression.

Case Report: A 31-year-old African American woman presented with progressive shortness of breath, hemoptysis and unintentional weight loss. The clinical examination was consistent with profound hypoxia. The possibility of pulmonary embolism was excluded as well as red blood cell transfusions were administered to correct the underlying normocytic anemia. Due to minimal improvement in her clinical condition, a repeat CT of thorax and abdomen, and a trans-thoracic echocardiogram were performed which revealed generalized lymphadenopathy and moderate-to-severe pulmonary hypertension respectively. Due to multi-system manifestations, human immunodeficiency virus (HIV) testing was performed which confirmed HIV seropositivity. Antiviral therapy was initiated in addition to presumptive therapy for possible *Pneumocystis (carinii) jirovecii* infection. The patient did not demonstrate clinical improvement, however, and cardio-pulmonary decline was attributed to HIV-associated pulmonary hypertension.

Conclusion: Clinicians should include PAH in the differential diagnosis of unexplained hypoxia in HIV infected patients. Early recognition of PAH is necessary to ensure the greatest likelihood of favorable outcomes.

CASE REVIEW

A 31-year-old African American woman presented to the emergency room with progressive shortness of breath, generalized lethargy, and trace hemoptysis of two weeks duration. She had no reported fever, recent flight trip, chest discomfort or palpitations. The patient recalled weight loss of 15 pounds over the previous two months. Prior to symptom onset, she was in her usual state of health and was able to perform activities of daily living. Over the next several hours after admission, hypoxia persisted despite non-invasive positive pressure ventilation, so she was transferred to intensive care unit for close monitoring.

The patient had no prior history of pulmonary or cardiac conditions. She was not taking any prescription or herbal medications. She had smoked tobacco over the past ten years. There was no exposure to intravenous drug use. She was in a monogamous relationship with her husband and had two children; both were spontaneously delivered vaginally. Exposure to pets was denied by the patient. Two older siblings had no significant medical or surgical history.

The clinical examination revealed oxygen saturation of 87% on ambient air, tachypnea, tachycardia, bilateral pulmonary rales in basal fields, a low intensity systolic murmur at left sternal border, and inguinal lymphadenopathy. Remainder of the examination was normal.

The patient received pack red blood cell transfusions to correct the normocytic anemia; however her symptoms did not improve. The patient lacked systemic inflammatory response syndrome features. Mild elevation in brain natriuretic peptide (BNP) and a normal cardiac bio-marker profile were not consistent with myocardial ischemia. A trans-thoracic echocardiogram was performed which revealed cardiomegaly, moderate-to-severe pulmonary hypertension and tricuspid regurgitation (Figure 1). A non-contrast computerized tomography (CT) of thorax and abdomen (due to renal failure) was performed which revealed no pulmonary embolism and lymphadenopathy involving the superior mediastinal, paratracheal, supraclavicular, retroperitoneal, and inguinal regions (Figure 2). A flow cytometry analysis of peripheral blood showed no

evidence of abnormal myeloid maturation or blast populations. Laboratory testing for vasculitides and infectious mononucleosis was negative. Due to multi-system manifestations including generalized lymphadenopathy, moderately-severe pulmonary hypertension and profound anemia, human immunodeficiency virus (HIV) testing was performed which confirmed HIV seropositivity. The CD4 T-lymphocyte count was suppressed to 160 cells/ml and the HIV RNA viral load level was detectable at 26975 copies/ml. Antiviral therapy was initiated in addition to presumptive trimethoprim-sulfamethoxazole for possible *Pneumocystis (carinii) jirovecii* infection. She did not demonstrate clinical improvement, however, and her cardio-pulmonary decline was attributed to HIV-associated pulmonary hypertension. She required transfer to a specialized center for further management.

Figure 1

Transthoracic Echocardiogram obtained during this admission

A parasternal short-axis view (Panel A) shows normal left ventricular (LV) size but marked enlargement of the right ventricle (RV) with systolic flattening of the interventricular septum causing a D-shaped septum (arrows). Continuous wave Doppler image (Panel B) shows the tricuspid valve regurgitant jet. The peak systolic pressure gradient was 67 mmHg indicating marked right ventricular and pulmonary systolic hypertension.

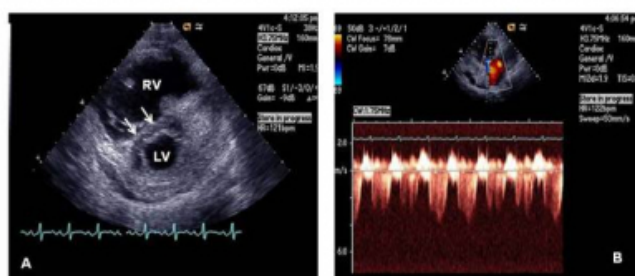
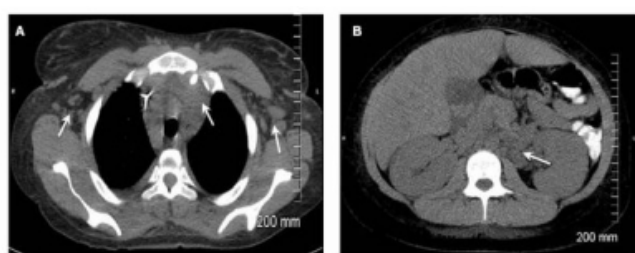


Figure 2

Non-contrast CT thorax (Panel A) shows superior mediastinal and bilateral axillary lymphadenopathy (arrows). Non-contrast CT abdomen and pelvis (Panel B) shows retroperitoneal and peri-aortic lymphadenopathy (arrow)



DISCUSSION

Pulmonary Arterial Hypertension (PAH) is defined as an increased mean pulmonary-artery pressure >25 mmHg at rest or >30 mmHg during exercise, and a pulmonary-capillary wedge pressure of less than 15 mmHg. This devastating disease is characterized by an increase in pulmonary vascular resistance which results in increased right ventricular strain leading to right ventricular hypertrophy, right heart failure and death. Symptoms of PAH are usually non-specific, and include dyspnea, fatigue, and atypical chest pain, which usually occur in the presence of a relatively normal physical examination. Patients often present later in the course of disease [1].

Multiple causes may lead to the development of PAH including hypoxia associated with pulmonary and non-pulmonary conditions, thromboembolism, left ventricular muscle or valve diseases, connective tissue disorders, congenital heart diseases, porto-pulmonary diseases, human immunodeficiency virus (HIV) infection and idiopathic PAH [1]. PAH is a rare but fatal complication of HIV exposure and can increase HIV associated morbidity and mortality. Histologically, PAH is characterized by medial hypertrophy, intimal proliferation, and plexiform lesions in small pulmonary arteries [2, 3].

PAH is a well established complication of HIV infection [4] and HIV infected individuals are at higher risk for development of PAH compared to the general population. This suggests that either the virus itself or the consequences of infection may directly be linked with development of PAH [5]. Despite the strong association of PAH with HIV, the underlying pathogenesis of this association remains unclear. A number of HIV viral proteins have been proposed to promote the development of PAH during the course of HIV infection, the most likely of which is the 'Nef' protein (negative factor). The 'Nef' protein is an N-myristoylated protein, originally identified as a negative regulatory factor for HIV replication, and later recognized as an important protein for the maintenance of high viral loads during the course of HIV infection [6]. The 'Nef' protein is abundantly expressed during early viral infection, and appears to promote the initiation and persistence of HIV infection, and enhancement of HIV infectivity [7]. A study by Duffy, et. al., suggested that the 'Nef' protein also plays an important role in the alteration in pulmonary vascular cells by decreasing endothelin dependent vasorelaxation as well as NOS (Nitrous Oxide Systems) expression, and induces

oxidative stress in an experimental model in porcine pulmonary arteries [8].

PAH can complicate the course of HIV infection regardless of the stage of HIV infection, route of transmission and degree of immunosuppression [9]. In 1990's, epidemiologic data suggested that the prevalence of PAH in HIV-infected persons was approximately 0.5% when highly active anti-retroviral therapy was not available [10]. More recently, the prevalence of PAH in HIV infection was re-evaluated and showed a stable prevalence of 0.46% (95% CI 0.32% to 0.64%) [11]. As mentioned above, PAH usually presents later in the course largely due to the non-specificity of symptoms [12].

Various treatment options are available for PAH in HIV infection. A Swiss study showed that antiviral therapy appeared to have no effect on preventing the development of PAH, as two-third of patients developed PAH while receiving antiviral therapy. Of note, this study showed no significant survival benefit in patients treated with antiviral therapy compared to those not treated [10]. However, Cicalini, et. al., in their study showed a survival rate of 55% among patients treated with antiviral therapy compared to 22% amongst a non-treatment group ($p = 0.02$) [13]. This study also recommended an endothelin receptor antagonist, prostacyclin analogs, and type 5 phosphodiesterase inhibitors for treatment of PAH associated with HIV infection [9]. However, the role of antiviral therapy remains unclear in the setting of HIV infection and concomitant PAH.

CONCLUSION

In conclusion, more research is required to explore the exact pathophysiologic mechanism of development of PAH in HIV infection, the natural history of PAH disease progression with respect to the course of HIV infection, and effective treatment strategies. Although available literature does not support the disease modifying role of antiviral therapy in the treatment of HIV infection associated PAH,

large multicenter prospective studies are needed to establish the effect of a sustained virologic response and a stable T-cell profile on the course of PAH. Clinicians should include PAH in the differential diagnosis of unexplained hypoxia in HIV infected patients. Early recognition of PAH is necessary to ensure the greatest likelihood of favorable outcomes.

References

1. Archer, S.L. and E.D. Michelakis, Phosphodiesterase type 5 inhibitors for pulmonary arterial hypertension. *N Engl J Med*, 2009. 361(19): p. 1864-71.
2. Simonneau, G., et al., Updated clinical classification of pulmonary hypertension. *J Am Coll Cardiol*, 2009. 54(1 Suppl): p. S43-54.
3. Lederman, M.M., et al., Pulmonary arterial hypertension and its association with HIV infection: an overview. *AIDS*, 2008. 22 Suppl 3: p. S1-6.
4. Kim, K.K. and S.M. Factor, Membranoproliferative glomerulonephritis and plexogenic pulmonary arteriopathy in a homosexual man with acquired immunodeficiency syndrome. *Hum Pathol*, 1987. 18(12): p. 1293-6.
5. Voelkel, N.F., C.D. Cool, and S. Flores, From viral infection to pulmonary arterial hypertension: a role for viral proteins? *AIDS*, 2008. 22 Suppl 3: p. S49-53.
6. Kestler, H.W., 3rd, et al., Importance of the nef gene for maintenance of high virus loads and for development of AIDS. *Cell*, 1991. 65(4): p. 651-62.
7. Miller, M.D., et al., The human immunodeficiency virus-1 nef gene product: a positive factor for viral infection and replication in primary lymphocytes and macrophages. *J Exp Med*, 1994. 179(1): p. 101-13.
8. Duffy, P., et al., HIV Nef protein causes endothelial dysfunction in porcine pulmonary arteries and human pulmonary artery endothelial cells. *J Surg Res*, 2009. 156(2): p. 257-64.
9. Degano, B., O. Sitbon, and G. Simonneau, Pulmonary arterial hypertension and HIV infection. *Semin Respir Crit Care Med*, 2009. 30(4): p. 440-7.
10. Opravil, M., et al., HIV-associated primary pulmonary hypertension. A case control study. *Swiss HIV Cohort Study. Am J Respir Crit Care Med*, 1997. 155(3): p. 990-5.
11. Sitbon, O., et al., Prevalence of HIV-related pulmonary arterial hypertension in the current antiretroviral therapy era. *Am J Respir Crit Care Med*, 2008. 177(1): p. 108-13.
12. Nunes, H., et al., Prognostic factors for survival in human immunodeficiency virus-associated pulmonary arterial hypertension. *Am J Respir Crit Care Med*, 2003. 167(10): p. 1433-9.
13. Cicalini, S., et al., Treatment and Outcome of Pulmonary Arterial Hypertension in HIV-Infected Patients: A Review of the Literature. *Curr HIV Res*, 2009. 7(6): p. 589-96.

Author Information

Mazher Rasool, MD, Internal Medicine Residency Program
University of Illinois College of Medicine at Urbana-Champaign
Urbana, IL 6180, USA
rasool2@illinois.edu

Digant Bhatt, MD, MPH, Clinical Instructor
Dartmouth Hitchcock Medical Center, Department of Cardiology
Lebanon, NH, 03766, USA
digant.dr@gmail.com

Batlangundu Lakshminarayanan, MD, Clinical Associate Professor Department of Medicine Division of Cardiology
University of Illinois College of Medicine at Urbana-Champaign
Urbana, IL 6180, USA
blakshminarayan@hotmail.com

Janet A. Jokela, MD, MPH, FACP, Head Department of Medicine Division of Infectious Diseases
University of Illinois College of Medicine at Urbana-Champaign
Urbana, IL 6180, USA
jokela@illinois.edu