

Pulmonary Emboli without Leg Symptoms, May-Thurner syndrome. Case Report and Review

A Hamo, M Alyaseen, F Alkhankan, T Gress

Citation

A Hamo, M Alyaseen, F Alkhankan, T Gress. *Pulmonary Emboli without Leg Symptoms, May-Thurner syndrome. Case Report and Review*. The Internet Journal of Internal Medicine. 2012 Volume 9 Number 2.

Abstract

May-Thurner syndrome or Iliac compression syndrome is a clinical condition that occurs as a result of compression of the left common iliac vein by the overlying right common iliac artery. This syndrome most often affects young to middle-aged women, and patients usually have left leg symptoms. We describe an unusual case of a 23-year-old female who had pulmonary emboli caused by iliac compression syndrome without leg symptoms. Combined venography and aortography confirmed the diagnosis, and patient was successfully treated with anticoagulants. May-Thurner or Iliac compression syndrome is generally underdiagnosed and should be considered when pulmonary embolism appears without obvious cause.

ABBREVIATIONS

INTRODUCTION

External compression of the left iliac vein by the artery which crosses over it is a normal anatomy and a common finding in the general population, but in some people the artery presses on the vein enough to thicken the vein wall over time. It may predispose patients to the development of deep vein thrombosis (DVT) of the left leg and may also lead to a more complicated course than in other types of DVT. This entity was first described by James P. McMurrich, professor of anatomy at the University of Michigan, in 1908^[1], and defined anatomically by May and Thurner in 1956^[2] and clinically by Cockett and Thomas in 1965^{[3][4]}.

May and Thurner, in 1956, described anatomic variations of the left common iliac vein that resulted in lower extremity venous outflow obstruction in 22% of 430 cadavers. Fibrous vascular lesions called “spurs” were found at the level where the right iliac artery compressed the left iliac vein against the fifth lumbar vertebra (Figure 1).

In 1965, Cockett and Thomas^[4] reported a series of 35 patients with the clinical entity of iliofemoral venous thrombosis with iliac vein obstruction. The majority of these patients were found to have involvement of the left lower extremity, and all of the patients who underwent surgical exploration showed fibrous obstruction of the left iliac vein.

This syndrome most often affects young to middle-aged women, and patients usually have left leg symptoms; including acute DVT, chronic leg edema, pain, and varicosities. We describe an unusual case of a 23-year-old female who had pulmonary emboli caused by iliac compression syndrome without leg symptoms. Combined venography and aortography confirmed the diagnosis, and patient was successfully treated with anticoagulants. We also review the management strategies of this syndrome using angioplasty, intraoperative thrombolysis, and endoluminal stent placement.

Figure 1

Figure (1) Drawing shows The right common iliac artery overlies the left common iliac vein and may compress it against the vertebral body that is located posteriorly. IVC = inferior vena cava.

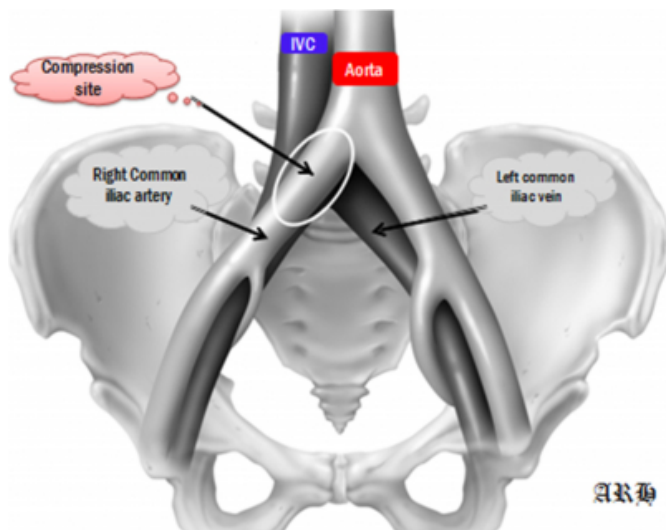
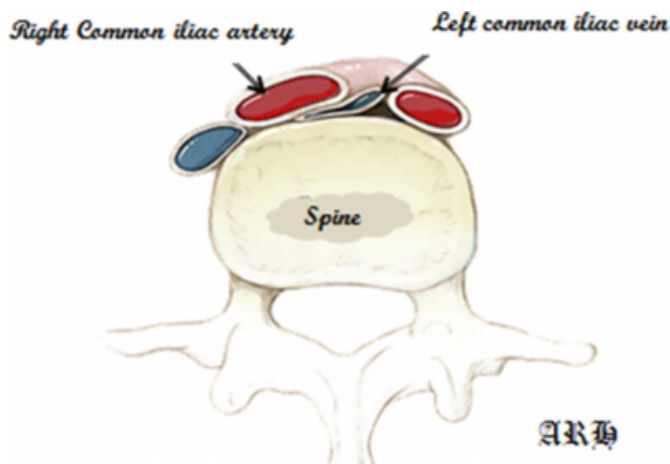


Figure 2

Figure (1) Drawing shows The right common iliac artery overlies the left common iliac vein and may compress it against the vertebral body that is located posteriorly. IVC = inferior vena cava.



CASE REPORT

A 23-year-old white female in her postpartum period, had presented to our emergency room 10 days after giving birth complaining of shortness of breath since delivery. She had uncomplicated vaginal delivery. The patient complained of mild dyspnea since then but it have been getting worse the last 4 days. She reported also a right sided pleuritic chest pain. Denied cough, fever or chills. Denied any prior personal or family history of thromboembolic disease. She reported social smoking of few cigarettes a week.

The patient was hemodynamically stable, Physical examination on presentation revealed no abnormality other than decreased breathing sounds bibasilar. There was no edema, nor were there any varicose veins of the lower extremities.

The complete blood count, chemistry studies, prothrombin time and activated partial prothromboplastin time were normal. She was found to have a positive D-Dimer and an A-a gradient. A chest radiograph showed a small bilateral pleural effusion. Helical CT scans of the chest revealed intraluminal filling defect in the the right upper division of the right pulmonary artery (figure 2). The patient was diagnosed as having pulmonary thromboembolism (PE), and anticoagulant therapy with intravenous unfractionated heparin was begun. Subsequent workup for hypercoagulability, including tests for protein C, protein S, antithrombin III, anticardiolipin antibodies, and factor-V Leiden, were negative.

Ultrasound (U/S) duplex examination of the pelvic and leg veins was performed, the patient lacked any apparent predisposition to PE, but at the same time the U/S suggested possible thrombosis with extrinsic compression of the left common iliac vein. The thrombosis was confirmed by helical CT scan of the pelvis (figure 3). Bilateral simultaneous iliac venography combined with aortography clearly demonstrated compression of the left common iliac vein by the overlying right common iliac artery, with multiple dilated collateral veins (figure 4).

It was concluded that the pulmonary emboli was caused by iliac compression syndrome (May-Thurner Syndrome).The patient was treated with enoxaparin and warfarin. She did well and was discharged home on oral anticoagulation.

Approximately 3 weeks later, she presented again for follow up, the patient remained asymptomatic. A compression ultrasound showed a stable deep venous system with no clear evidence of extension of the thrombus.

Figure 3

Figure 2. Helical CT scan of the chest reveals intraluminal filling defect in the right main pulmonary artery (arrow)

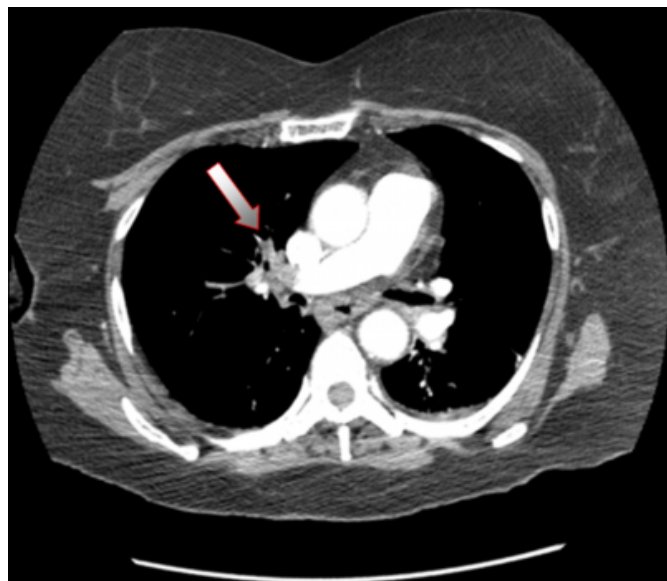


Figure 4

Figure (3). Helical CT scan of the pelvis demonstrating compression of the left common iliac vein (Blue arrow) as it passes under the right common iliac artery (Red arrow).

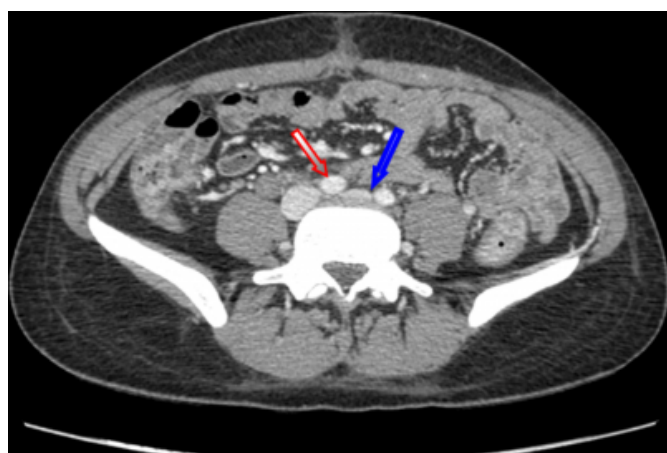
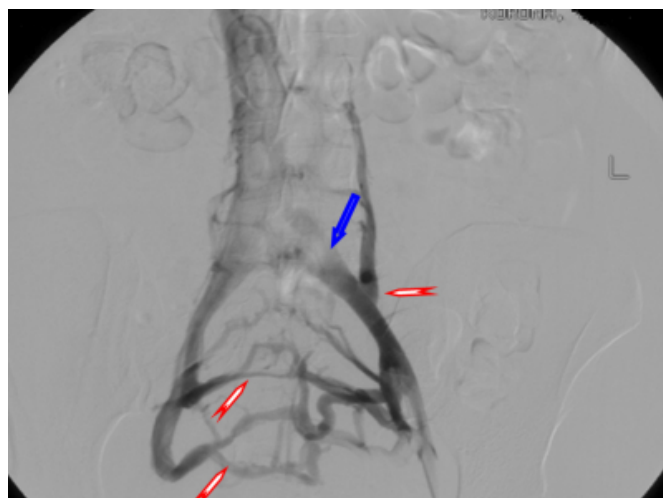

Figure 5

Figure(4). Venogram reveals compression of the left common iliac vein by the overlying right common iliac artery (blue arrow) with dilated collateral veins (red arrows).



DISCUSSION

Historically, Virchow ^[5] noted that the occurrence of thrombosis was five times more common on the left side than on the right. In 1906, McMurrich ^[1] noted the presence of strictures in the common iliac vein and thought that these were congenital in origin, causing left iliofemoral venous thrombosis.

In 1956, May and Thurner ^[2] observed focal intimal vascular thickening with web or septae formation in 22% of an autopsy series of 430 patients. They noted that in these cases, the right iliac artery crossed anteriorly to the left iliac vein, compressing it against the fifth lumbar vertebral body, as illustrated in (Figure 1). They proposed that the pulsatile right iliac artery might cause chronic injury to the left iliac vein, resulting in pathologic findings due to intimal fibrosis. Significantly, they noted the absence of these lesions in fetal autopsies, thus supporting their belief that the lesion is acquired rather than congenital.

The true prevalence of MTS remains debatable. It has been estimated to occur in 2 to 3% of all lower extremities. Wolpert et al ^[7] reviewed 24 patients with isolated left lower extremity swelling; 7 patients (29%) were found to have DVT, while 9 patients (37%) had evidence of May-Thurner anatomy without DVT by magnetic resonance venography (MRV).

Kibbe et al ^[8] reported a series of 50 consecutive patients who had undergone abdominal CT scans for reasons unrelated to venous thrombosis. They found that among

these patients 24% had 50% compression of the left iliac vein, and 66% had 25% compression. No patient in this series had left lower extremity edema or other signs or symptoms of venous obstruction.

Although, the true incidence of thrombosis in the setting of iliac compression syndrome is uncertain, there is evidence that patients in whom thrombosis develops may be at higher risk for recurrent DVT. Mickley et al^[9] have reported on a series of selected patients who underwent thrombectomy for iliofemoral thrombosis. Of the patients with left-sided thrombosis, 49% had venous spurs found intraoperatively. Prior to 1994, those spurs were untreated, and 72% of those patients had recurrent occlusive thrombosis despite treatment of at least 1 year with vitamin K antagonists. In comparison, recurrence occurred in only 1 of 28 similarly treated patients (4%) with either right-sided thrombosis or left-sided thrombosis without spur formation.

Clinically, the large majority of MTS patients are asymptomatic; the most common symptom is swelling of the left lower extremity (25-100%). Other signs and symptoms include left leg pain, and varicosities. Most authors have described a female predominance for the condition. In 1967, Cockett et al.^[3,6] reported that pulmonary embolus was the presenting symptom in about 25% of patients. However, interestingly, few cases with PE as the initial symptom have since been reported. Our patient developed pulmonary embolism first, without any leg symptoms or signs.

It seems that when the patient was pregnant the uterus was compressing these collaterals resulted in the patient's legs swelling. Now that the patient is post partum, the collaterals are able to flow more freely and the left leg is therefore not significantly swollen.

The diagnosis of MTS is best made radiographically. Venography remains the gold standard for the diagnosis of MTS, because it can demonstrate collateral veins as well as the compression itself. Although we have not performed MRA, it seems to be preferable prior to CT, especially in young or pregnant patients, because MRA eliminates the problem of radiation exposure. In our patient, combined venography and CT clearly demonstrated the point where the left common iliac vein was compressed by the right common iliac artery. Venography has the benefit that if an obstructive lesion exists, angioplasty or stenting can be performed during the same procedure.

Therapy for MTS has evolved over the years. Conservative

therapy with compressive stockings has been largely unsuccessful, likely due to the proximal mechanical nature of the obstruction^[3].

Many surgical procedures for the relief of obstruction have been described. Venovenous bypass procedures utilizing graft material have enjoyed moderate success^[3]. Other authors have discussed mobilizing the right common iliac artery off the left iliac vein with the interposition of a peritoneal flap, a fascia lata sling, or a prosthetic bridge to prevent recurrent damage. The best results have been seen with vein patch angioplasty, with rerouting of the right iliac artery to a retrocaval position. This procedure involves opening the iliac vein with the resection of the fibrous septa or web. The vein is closed with a patch angioplasty using a segment of cephalic vein that has been reanastomosed with an interposition autograft to minimize the tension on the graft. Taheri et al^[10] have reported an 80% success rate with this procedure using either a transabdominal or retroperitoneal approach.

Most recently, with the advancement of endovascular treatments, percutaneous angioplasty with stent placement has been utilized. Berger et al.^[11] were the first to describe catheter-directed thrombolysis followed by angioplasty with stent placement for the treatment of angiographically proven May-Thurner syndrome. Heijmen et al.^[12] reported a series of 6 patients in whom self-expanding stents were placed for the treatment of symptomatic May-Thurner syndrome that had been diagnosed by venography.

As our patient has been asymptomatic and without deep vein thrombosis, we maintained her on anticoagulant therapy for 2 years, although the optimum duration of anticoagulant therapy remains unknown.

At this time the stenting is not warranted as the longevity of the stent is short due to myointimal hyperplasia. The patient is very young and should avoid stenting as long as possible. Should symptoms get worse then repeat venogram with possible stenting would then be required.

CONCLUSION

May-Thurner syndrome is a partial occlusion of the left common iliac vein secondary to crossing of the iliac arteries, associated with the development of acute venous thrombosis of the left iliac vein.

May-Thurner or Iliac compression syndrome is generally underdiagnosed and should be considered when pulmonary

embolism appears without obvious cause, or cases of left leg DVT in young patients without other obvious culprits.

Although no consensus exists regarding the best treatment, and clinical data are limited to a small number of case series and reports, patients in whom May-Thurner syndrome is diagnosed may be at higher risk of recurrent thrombosis.

Consideration can be given to prolonged anticoagulation or stent placement for the relief of mechanical obstruction. Further clinical trials are warranted to define the optimal treatment strategy.

References

1. McMurrich JP. The occurrence of congenital adhesions in the common iliac veins and their relation to thrombosis of the femoral and iliac veins. *Am J Med Sci* 1908; 135:342–346
2. May R, Thurner J. The cause of the predominately sinistral occurrence of thrombosis of the pelvic veins. *Angiology* 1957;8:419–427
3. Cockett FB, Thomas LM: The iliac compression syndrome. *Br J Surg* 1965;52:816-821.
4. Verhaeghe R: Iliac vein compression as an anatomical cause of thrombophilia: Cockett's syndrome revisited. *Thromb Haemost* 1995;74:1398-1401.
5. Virchow R. *Über die erweiterung kleiner gefasse*. *Arch Path Anat* 1851; 3:427
6. Cockett FB, Thomas LM, Negus D: Iliac vein compression. Its relation to iliofemoral thrombosis and the post-thrombotic syndrome. *Br Med J* 1967;2:14-19.
7. Wolpert LM, Rahmani O, Stein B, et al. Magnetic resonance venography in the diagnosis and management of May-Thurner syndrome. *Vasc Endovascular Surg* 2002; 36:51–57
8. Kibble MR, Ujiki M, Goodwin AL, et al. Iliac vein compression in an asymptomatic patient population. *J Vasc Surg* 2004; 39:937–943
9. Mickley V, Schwagierek R, Rilinger N, et al. Left iliac venous thrombosis caused by venous spur: treatment with thrombectomy and stent implantation. *J Vasc Surg* 1998; 28:492–497
10. Taheri, SA, Williams, J, Powell, S, et al Iliocaval compression syndrome. *Am J Surg* 1987;154,169-172
11. Berger, A, Jaffe, JW, York, TN Iliac compression syndrome treated with stent placement. *J Vasc Surg* 1995;21,510-514
12. Heijmen, RH, Bollen, TL, Duyndam, DA, et al Endovascular venous stenting in May-Thurner syndrome. *J Cardiovasc Surg (Torino)* 2001;42,83

Author Information

Abdrhman Hamo, MD, M.MED

Joan C. Edwards School of Medicine, Marshall University

Maisoon Alyaseen, MD

Fadi Alkhankan, MD

Todd Gress, MD, MPH.