

Lipoma Oral Cavity: A Case Report With Review Of Literature

J Gulia, S Yadav, P Rana, S Singh, A Duhan, R Sen, A Hooda

Citation

J Gulia, S Yadav, P Rana, S Singh, A Duhan, R Sen, A Hooda. *Lipoma Oral Cavity: A Case Report With Review Of Literature*. The Internet Journal of Otorhinolaryngology. 2012 Volume 14 Number 1.

Abstract

Lipoma is one of the common mesenchymal neoplasms with most of the lipomas developing on the trunk and proximal portion of extremities. Lipoma of the oral cavity is rare and represent about 0.5% to 5% of all benign oral tumors. A case of lipoma oral cavity in an elderly male treated by surgical excision is reported.

INTRODUCTION

Lipoma is a benign mesenchymal neo-plasm composed of mature adipocytes, usually surrounded by a thin fibrous capsule¹. They develop in any location where fat is normally present, mostly in the subcutaneous tissues but also could develop in deeper tissues². Lipoma most commonly occurs in the trunk and limbs of the body, and seldom in the oral and maxillofacial region. They are relatively uncommon in the oral cavity, representing about 0.5% to 5% of all benign oral tumors^{1,3}. A lipoma arising from the anterior pillar of left tonsil in a 60 year old male is presented.

CASE REPORT

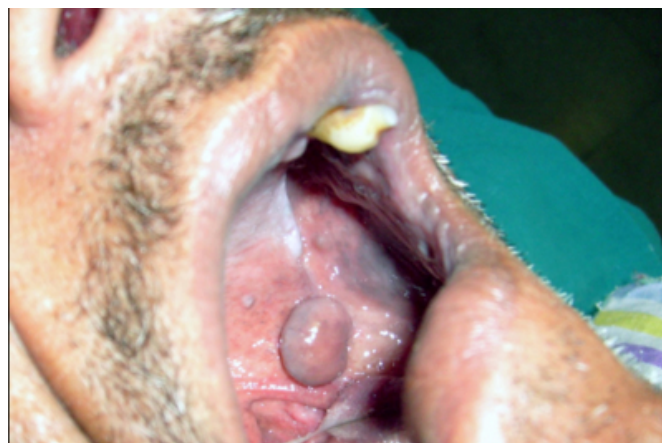A 60 year old male patient presented with three year history of swelling in the oral cavity, which has slowly increased in size. He complained of recurrent pain, and lump in the throat. The patient was a smoker and farmer by profession. Past history was insignificant.

General physical examination was normal.

Otorhinolaryngological examination of the oral cavity revealed a pedunculated, smooth, soft tumor of approximate size 1.5 x 1.0 x 0.8cm attached to left anterior pillar. It was painless, mobile and attached to the anterior pillar of tonsil by a narrow small stalk. There was no palpable cervical lymphadenopathy. Dental examination revealed that he was partially edentulous. (Figure1).

Figure 1

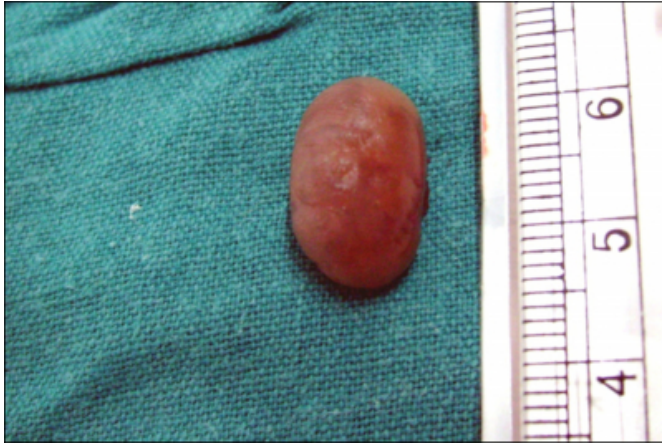Figure 1: A smooth encapsulated pedunculated mass of 1.5 x 1.0 x 0.8cm arising from left anterior pillar.



Provisional diagnosis of lipoma with epidermoid cyst and hamartoma as other differential diagnosis was made. The routine radiological and blood investigations were normal. After anesthetic fitness the patient was taken up for surgery under local anesthesia. The swelling was excised through trans-oral route. The excised specimen was well encapsulated, yellow colored tumor with a soft consistency measuring 1.5 x 1.0 x 0.8cm. (Figure2).

Figure 2

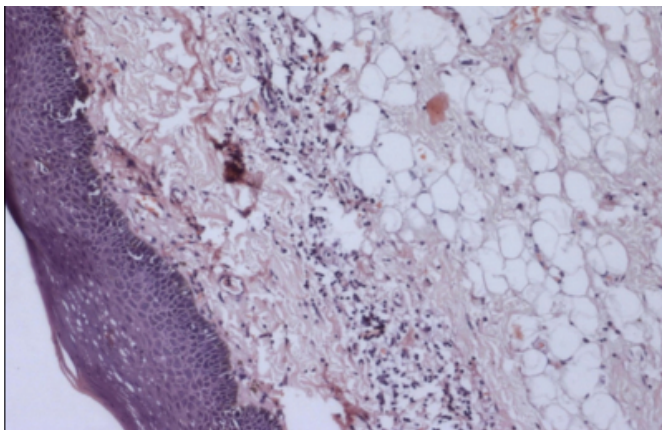
Figure 2: The excised Lipoma measuring 1.5 x 1.0 x 0.8cm.



On cut section, it had typical lobulated lipomatous appearance. Histopathological examination showed uniformly rounded cells with peripheral sheets of mature adipocytes containing large clear cytoplasm and eccentric nuclei with inconspicuous vascularity and no evidence of cellular atypia, confirming the pre-operative diagnosis of lipoma (Figure 3).

Figure 3

Figure 3: Stratified squamous lining covered some uniformly rounded cells (lymphoid tissue) with peripheral sheets of mature adipocytes (H&E; x20)



Post operative period was uneventful and after a follow up of 15 months, patient has no recurrence.

DISCUSSION

Benign lipomas are the most common mesenchymal tumors developing in any location where fat is normally present, but are relatively uncommon in the oral and maxillofacial region². Lipomas of the oral and maxillofacial region are slow growing neoplasms as in other parts of the body. They

mostly develop in one site and only 5% are multiple³.

Tumors in the oral cavity may become symptomatic earlier than those in other anatomic sites. Still most tumors in the literature have been relatively asymptomatic and several grew to a large size before patients sought medical advice.^{1,4,5} In the present case also patient gave a history of about three years.

These tumors most often occur in adult patients usually older than 40 years⁶ with a male predilection and are uncommon in children.⁷ Our case was also an elderly of male patient.

The lipomas in the maxillofacial region has been reported in the major salivary glands, buccal mucosa, tongue, lips, palate, vestibule, and floor of mouth^{1,6-8}. Superficial lipomas in oral and maxillofacial region sometimes can be diagnosed clinically. Palpation reveals a soft, painless, and mobile mass with a history of gradual enlargement, over several months or years as in the present case. Deep lipomas usually are not palpable and it may be difficult to distinguish between the mass and the adjacent tissues, especially when the mass is adherent to muscles and salivary glands. Hence, the imaging examination such as ultrasonography or a fine needle aspiration biopsy (FNAB) is useful for the diagnosis^{2,9,10}.

On ultrasonography most lipoma appears hypoechoic. Most lipomas have capsules and appear as well defined masses, usually with a distinct echogenic capsule. But the blending of fat into the surrounding subcutaneous or muscular tissue could result in ill defined ultrasonographic margins as can occur with intramuscular lipoma.² However, the soft tissue characterization is less specific with ultrasonography than with computed tomography or magnetic resonance imaging. When the mass is difficult to identify on ultrasonogram, CT or MRI is necessary.^{3,11}

Microscopically, it is not possible to distinguish these lipomas from normal adipose tissue, despite their different metabolism (they are not used as an energy source as is normal adipose tissue), probably due to high lipoprotein lipase activity in neoplastic lipoma cells^{1,12}. Based on their histopathologic features, lipomas can be classified as: classic lipoma; lipoma variants, such as angiolipoma, chondroid lipoma, myolipoma and spindle cell/pleomorphic lipoma, all with specific clinical and histologic features; hamartomatous lesions; diffuse lipomatous proliferations; and hibernoma.^{13,14}

Angiolipoma, a recognized clinical and histologic lipoma variant has been reported in the mucolabial fold, in the

buccal mucosa, and in other sites of the head and neck^{14,15}. Chondroid lipoma, first described by Meis and Enzinger in 1993, is a benign lipoma variant that can resemble liposarcoma and myxoid chondrosarcoma¹⁶. Cartilaginous or osseous metaplasia in a lipoma is a relatively rare finding characterized by mature, benign cartilage or bone formation within the neoplastic fatty tissue. The pathogenesis is largely speculative, but probably is related to endochondral ossification by pluripotent mesenchymal cells in the fat.^{14,17}

Intramuscular and poorly circumscribed lipomas can occur in the oral and maxillofacial region, most commonly in the tongue^{1,4}. The clinical significance of intramuscular lipoma in this anatomic location is unknown, although in extremity locations, these may have an infiltrative growth pattern and a tendency for local recurrence.¹⁸ Secondary changes such as fat necrosis and prominent hyalinization can also occur in lipomas.⁷

Differential diagnosis of oral lipoma include oral dermoid, epidermoid cysts, oral lymphoepithelial cysts, salivary gland tumors and benign mesenchymal neoplasms.^{19,20}

The treatment of oral lipomas, including all the histological variants, is simple surgical excision. No recurrence is observed¹. In our case also no recurrence was noted after 15 months. However Cao et al have reported recurrence in patients under 18 years old and development of liposarcoma after several recurrences. Therefore, the complete resection should be ensured during first surgical treatment. Long-term follow-up is necessary in patients under 18 year's old.²¹

References

1. Fregnani ER, Pires FR, Falzoni R, Lopes MA, Vargas PA. Lipomas of the oral cavity: clinical findings, histological classification and proliferative activity of 46 cases. *Int J Oral Maxillofac Surg* 2003; 32:49–53.
2. Zhong LP, Zhao SF, Chen GF, Ping FY. Ultrasonographic appearance of lipoma in the oral and maxillofacial region. *Oral Surg Oral Med Oral Pathol Oral Radiol Endod* 2004;98:738-40.
3. Fornage BD, Tassin GB. Sonographic appearance of superficial soft tissue lipomas. *J Clin Ultrasound* 1991;19:215-20.
4. Kacker A, Taskin M. Atypical intramuscular lipomas of the tongue. *J Laryngol Otol* 1996;110:189-91.
5. Dattilo DJ, Ige JT, Nwana EJ. Intraoral lipoma of the tongue and sub-mandibular space: report of a case. *J Oral Maxillofac Surg* 1996;54:915-7.
6. Epivatianos A, Markopoulos AK, Papanayotou P. Benign tumors of adipose tissue of the oral cavity: a clinicopathologic study of 13 cases. *J Oral Maxillofac Surg* 2000; 58(10):1113–7.11
7. Furlong MA, Smith JCF, Childers ELB. Lipoma of the oral and maxillofacial region: Site and sub-classification of 125 cases. *Oral Surg Oral Med Oral Pathol Oral Radiol Endod* 2004;98:441-50.
8. Dutt SN, East DM, Saleem Y, Jones EL. Spindle cell variant of intralingual lipoma: report of a case with literature review. *J Laryngol Otol* 1999;113:587-9.
9. Ahuja AT, King AD, Kew J, King W, Metreweli C. Head and neck lipomas: sonographic appearance. *Am J Neuroradiol* 1998;19:505-8.
10. Layfield LJ, Glasgow BJ, Goldstein N, Lufkin R. Lipomatous lesions of the parotid gland. Potential pitfalls in fine needle aspiration biopsy diagnosis. *Acta Cytol* 1991;35:553-6.
11. Gritzmam N, Hollerweger A, Macheiner P, Rettenbacher T. Sonography of soft tissue masses of the neck. *J Clin Ultrasound* 2002;30:356-73.
12. Solvonuk PF, Taylor GP, Hancock R, Wood WS, Frohlich J. Correlation of morphologic and biochemical observations in human lipomas. *Lab Invest* 1984; 51(4):469–74.8
13. Fletcher CDM, Unni KK, Mertens F. Adipocytic tumors. In: Pathology and genetics: tumours of soft tissue and bone. World Health Organization classification of tumours. Lyon, France: IARC Press; 2002. p. 9-46.
14. Weiss SW, Goldblum JR, editors. Benign lipomatous tumors. In: Enzinger and Weiss's soft tissue tumors. 4th ed. St. Louis: Mosby; 2001. p. 571–639.
15. Sugiura J, Fujiwara K, Kurahashi I, Kimura Y. Infiltrating angiolipoma of the mucolabial fold: a case report and review of the literature. *J Oral Maxillofac Surg* 1999;57:446-8.
16. Meis JM, Enzinger FM. Chondroid lipoma: a unique tumor simulating liposarcoma and myxoid chondrosarcoma. *Am J Surg Pathol* 1993;17:1103-12.
17. Neville BW, Damm DD, Allen CM, Bouquot JE. Soft tissue lesions. In: Oral & maxillofacial pathology. 2nd ed. Philadelphia: W.B. Saunders Co; 2002. pp 437-96.
18. Greer RO, Richardson JF. The nature of lipomas and their significance in the oral cavity: a review and report of cases. *Oral Surg Oral Med Oral Pathol* 1973;36:551-7.
19. Anavi Y, Gross M, Calderon S. Disturbed lower denture stability due to lipoma in the floor of the mouth. *J Oral Rehabil* 1995; 22 :83-5
20. Tan MS, Singh B. Difficulties in diagnosing lesions in the floor of the mouth- report of two rare cases. *Ann Acad Med Singapore* 2004;33(4 Suppl):72–6.
21. Cao JG, Zhou XS, Liu YP, Gu XM. The clinical analysis of lipomas in oral and maxillofacial region. *Chin J Stomatol* 1995; 15:18-9.

Author Information

Joginder Singh Gulia

Professor, Department of Otolaryngology, Pt. B.D Sharma University of Health Sciences

S P S Yadav

Senior Professor, Department of Otolaryngology, Pt. B.D Sharma University of Health Sciences

Parveen Rana

Senior Resident, Pathology, Pt. B.D Sharma University of Health Sciences

Sunita Singh

Professor, Pathology, Pt. B.D Sharma University of Health Sciences

Amrita Duhan

Postgraduate student, Pathology, Pt. B.D Sharma University of Health Sciences

Rajeev Sen

Senior Professor, Pathology, Pt. B.D Sharma University of Health Sciences

Anita Hooda

Associate Professor, Oral Anatomy, Pt. B.D Sharma University of Health Sciences