

# Neutrophilic Myocarditis : A Rare Case Presentation

S Nibhoria, N Bamra, S Sandhu, K Jhaji

## Citation

S Nibhoria, N Bamra, S Sandhu, K Jhaji. *Neutrophilic Myocarditis : A Rare Case Presentation*. The Internet Journal of Pathology. 2012 Volume 13 Number 2.

## Abstract

An autopsy case report of 24 years young male who died with brief history of epigastric pain and vomiting. Autopsy was conducted and viscera was sent to pathology department. The histopathological examination revealed presence of Neutrophilic infiltration and microabscesses in the myocardium with minimal myocyte damage. The coronaries were patent. The lungs also show extensive Neutrophilic exudates. The present case highlights the Neutrophilic Myocarditis as a rare fatal diagnosis made on autopsy.

## INTRODUCTION

Myocarditis refers to an inflammatory response within the myocardium that is not secondary to ischemic events or cardiac rejection in the setting of transplantation. Dallas criteria defined it as an inflammatory infiltrate of the myocardium with necrosis and /or degeneration of adjacent myocytes not typical of ischemic damage associated with coronary artery disease.<sup>[1,2]</sup> Histologically some overlap exists among categories of myocarditis and no finding is specific for a single etiology. In general the histologic patterns can be divided into lymphocytic ( including viral and autoimmune forms ) , eosinophilic ( in which hypersensitivity myocarditis is the most common , followed by cases of hypereosinophilic syndrome ) , granulomatous ( sarcoid and giant cell myocarditis [ GCM ] ) , Neutrophilic ( bacterial , fungal , and early forms of viral myocarditis ) and reperfusion type / contraction band necrosis ( present in catecholamine induced injury and reperfusion injury ).

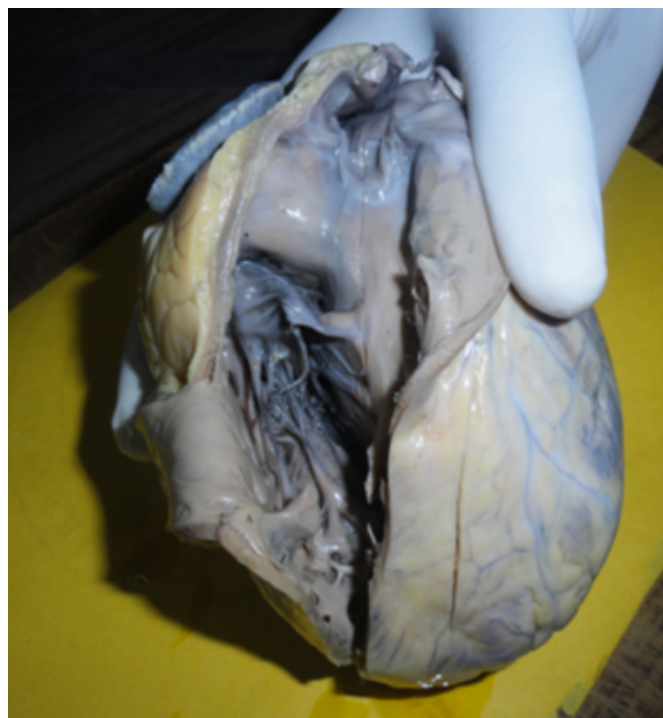## CASE REPORT

A 24 year old male patient was admitted to hospital with history of epigastric pain and vomiting. The preliminary diagnosis of acute gastritis was made from his symptoms and age but his condition deteriorated and he died within 45 minutes of hospital admission. Medico legal autopsy was conducted and the viscera was sent for histopathological examination to ascertain the cause of death. On gross examination the heart weighed only 280 gm and thickness of the left ventricular wall was 1.2 cm and thickness of right ventricular wall was 0.3 cm. The ventricular walls, papillary muscles, chordae tendinae, atria and valves were normal

.The Coronaries were patent [Figure 1]. Also received small parts of lungs.

## Figure 1

Figure 1 Gross appearance of Heart

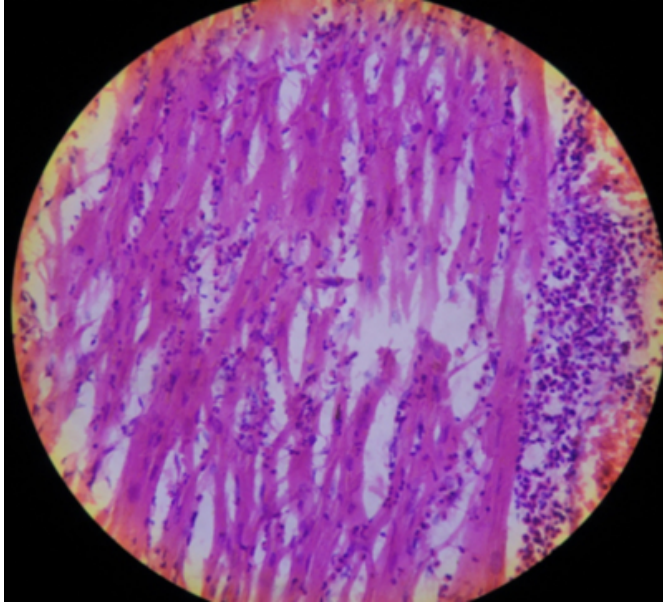


Microscopic examination of multiple sections taken from both ventricular walls showed inflammatory infiltrate consisting predominantly of neutrophils with foci of microabscesses and minimal myocyte damage [Figure 2] . Sections from lungs exhibited dense neutrophilic exudates and congestion highlighting the possibility that lungs may be

contiguous source of exudates in myocardium [Figure 3].

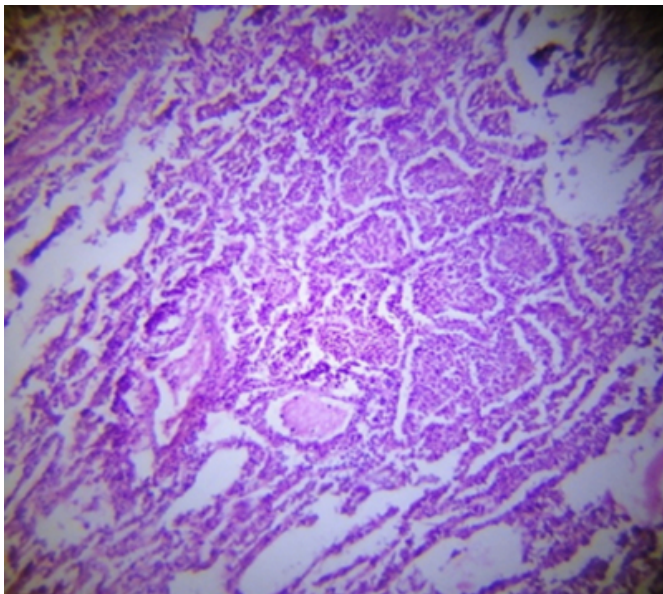
### Figure 2

Figure 2 Sections from myocardium showing inflammatory infiltrate consisting predominantly of neutrophils with foci of microabscesses (H& E X100)



### Figure 3

Figure 3 Sections from lungs exhibited dense neutrophilic exudates (H& E X100)



## DISCUSSION

Neutrophilic myocarditis is a rare and specific entity with very low incidence. Berry GJ and Atkins KA described that in developed countries infectious causes of heart muscle

inflammation are uncommon in immunocompetent individuals.<sup>[3]</sup> Patients with Acquired immunodeficiency syndrome ( AIDS ) , transplant associated immunosuppression to prevent allograft rejection and advanced cases of malignancy are susceptible to bacterial , viral , fungal , protozoal & rickettsial infections . In contrast in developing countries neutrophilic myocarditis due to infectious causes remains a significant cause of morbidity and mortality.<sup>[3]</sup> We are in developing country but still the diagnosis is very rare despite higher incidence in comparison to developed countries.

The major problem being that neutrophilic myocarditis has to be differentiated from myocardial infarction as in both conditions patients present with similar signs and symptoms and they can be differentiated only on histopathological grounds.<sup>[4,5,6]</sup> Raev D highlighted a case in 18 year old man who developed acute staphylococcal myocarditis in setting of acute tonsillitis in whom clinical, enzymatic and ECG findings have led to tentative erroneous diagnosis of acute myocardial infarction.<sup>[7]</sup>

In neutrophilic myocarditis there is seen neutrophilic infiltration and microabscesses in the myocardium with minimal myocyte damage. There is absence of coagulative necrosis and coronary artery disease. The classic mechanisms of myocardial dissemination include septicemia or localized infection from a contiguous source such as infected lung. Lorie R. and Hager WD et al documented that infective endocarditis was the most common pattern underlying neutrophilic myocarditis.<sup>[8,9]</sup>

The clinicians and the pathologists should keep in mind that in young male patients presenting with chest pain and absence of coronary artery disease, neutrophilic myocarditis is often the leading diagnosis.

## References

1. Artez HT: Myocarditis: The Dallas criteria. Hum Pathol 18:619,1987
2. Artez HT: Myocarditis: The Dallas classification. In: Virmani R, Atkinson JB, Fenoglio JJ (eds): Cardiovascular Pathology. Philadelphia, WB Saunders,1991,p246
3. Berry GJ, Atkins KA. Pathology of Human Myocarditis. In Myocarditis: From Bench to Bedside; 325-370
4. Silverman AJ, Kapadia N, Borin AJ: Acute myocarditis presenting as Acute myocardial infarction.J Am Osteopath Assoc.1995, Apr 95 (4):278-80
5. Goland S, Luthringer D, Shirvani V, Trento A, Czer L.S. An unusual case of allograft neutrophilic myocarditis mimicking acute myocardial infarction in a post –heart transplant patient. J Heart Lung Transplant 2009 Aug; 28 (8): 843-846
6. Beqieneman MP, Van de Goot Fr, Vander Bilt IA et al.

Pulmonary embolism causes endomyocarditis in the human heart. Heart 2008 Apr;94 (4): 450-456. Epub 2007 Jul.23  
7. Raev D: Acute Staphylococcal myocarditis masquerading as an acute myocardial infarction. Int. J Cardiol 1997 June 27; 60(1):95-98  
8. Lorie R. Cardiac lesions in bacterial endocarditis: from

findings of pathology to possibilities and limits of surgery. [French.] Arch Mal Coeur Vaiss 1993;86 Suppl:1811-1818  
9. Hager WD, Speck EL, Mathew PK, Boger JN, Wallace WA. Endocarditis with myocardial abscesses and pericarditis in an adult: group G streptococcus as a cause. Arch Intern Med 1977;137:1725-1728

**Author Information**

**Sarita Nibhoria**

Associate Professor, Department of Pathology, GGS Medical College Faridkot

**Navtej Singh Bamra**

Professor, Department of Pathology, GGS Medical College Faridkot

**Samarjit Kaur Sandhu**

Professor, Department of Pathology, GGS Medical College Faridkot

**Kanwardeep Kaur Jhajj**

Assistant Professor, Department of Pathology, GGS Medical College Faridkot