

Pedunculated Fibroma Of The Nipple; Case Report And Review Of The Literature

K Vagholkar, S Nair, S Tople, I Gopinathan

Citation

K Vagholkar, S Nair, S Tople, I Gopinathan. *Pedunculated Fibroma Of The Nipple; Case Report And Review Of The Literature*. The Internet Journal of Oncology. 2013 Volume 9 Number 1.

Abstract

Dermatoses of the nipple are a group of uncommon conditions. Fibroma of the nipple is one of the rarest of dermatoses. A pedunculated fibroma of the nipple is the rarest of all. It is a benign condition and is devoid of malignant potential. A case of pedunculated fibroma arising from the nipple is reported in view of its rarity along with a brief review of literature.

INTRODUCTION

Tumours originating from nipple-areola complex are not very common. They are usually classified as “dermatoses of the nipple”. These include a wide spectrum of lesions ranging from Paget’s disease to naevi. Pedunculated tumours are the rarest of all.

CASE REPORT

A 23 year old lady presented with a pedunculated lesion arising from the right nipple. (Figure 1) The patient gave history of its presence since childhood. There was no history of nipple discharge and surrounding skin changes. No history of similar lesion in opposite breast or in the family. Physical examination of the breast did not reveal any underlying mass in the nipple or breast. The lesion was excised under general anaesthesia taking utmost care to include root of peduncle. (Figure 2) The elliptical defect was closed with 5-0 prolene. Post-operative recovery was uneventful. Histo-pathological report of excised pedunculated mass confirmed the diagnosis of fibroma of nipple. (Figure 3) The patient has been following up for the last one year without any recurrence.

Figure 1

Pedunculated tumor arising from the right nipple.

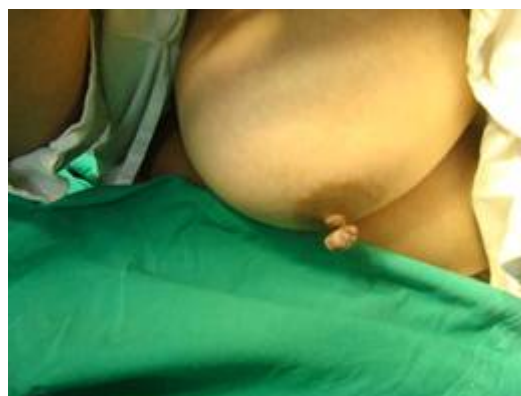

Figure 2

Excised specimen which includes the tumor and its stalk.

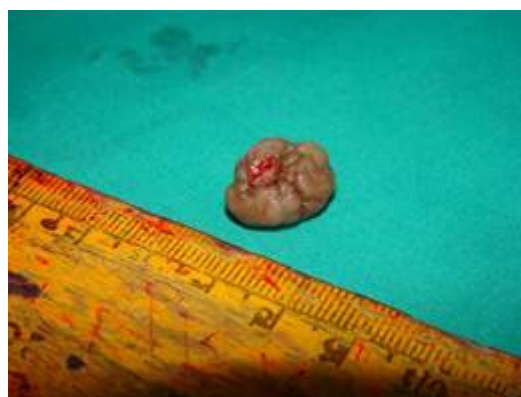
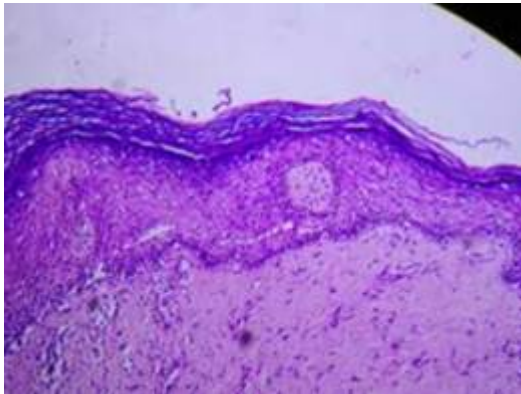


Figure 3

Fibroma of the nipple (H&E stain with Magnification 10x). Spindle shaped cells with benign cellular characteristics and thin walled vasculature.



DISCUSSION

Dermatoses of the nipple are an uncommon condition. The gross appearances of various lesions closely simulate each other, making diagnosis difficult. Various retrospective studies have been done to study the clinical and histological features.[1,2] In one such a study of 24 cases, Paget's disease was commonest, followed by nipple adenoma, molluscum contagiosum, soft fibroma, epidermal cyst and blue naevus. [2]

Patients with Paget's disease had overlying skin changes and blood stained nipple discharge. Fibroma especially those which are pedunculated in nature are extremely rare. Review of literature hardly revealed any specific case reports of pedunculated fibroma of nipple rendering this case a rarity. [3, 4]

Fibrous neoplasms range from fibromatosis to fibrosarcomas and malignant fibrous histiocytoma. [2] These tumours are grossly and histologically identical to their counterparts in other tissues and display the same tendency for recurrence

and metastasis in case of malignant cases. Fibromatosis involving the nipple may be mistaken for malignancy. Preoperative confirmation of the diagnosis may be difficult. Complete excision of the lesion with histological evaluation is the safest way to exclude malignancy. Fibromas of the nipple are slow growing benign tumours. Histologically they comprise of spindle shaped cells. Their potential for recurrence in a case of an adequately excised lesion is very low nor do they have a malignant potential. Local excision is therapeutic. In the case reported, excision of pedunculated lesion yielded excellent results with no evidence of recurrence.

CONCLUSION

Pedunculated nipple fibroma is extremely rare benign tumour of the nipple. It does not have malignant potential. Local excision is therapeutic.

ACKNOWLEDGEMENTS

We would like to thank Dr. Shirish Patil, Dean, Dr. D. Y. Patil Medical College, Navi Mumbai, India for allowing us to publish this case report.

We would also like to thank Mr. Parth K. Vagholkar for his help in typesetting the manuscript.

References

1. Doctor VM, Sirsat MV. Florid Papillomatosis (Adenoma) and other Benign Tumours of the Nipple and Areola. Br J Cancer 1971 March; 25(1): 1-9.
2. Alper Parlakgumus, Sedat Yildirim, Filiz Aka bolat, Kenan Caliskan, Ali Ezer, Tamer Colakoglu, Gokhan Moray. Dermatoses of the nipple. Can J Surgery. 2009 April; 52 (2): 160-161.
3. Prasad M, Pradhan PK, Bisarya BN. Pedunculated fibroma of nipple. J Indian Med Assoc. 1973 Dec 16; 61(12): 517.
4. Higaki Y, Yoshinaga Y, Kawashima M. Blister formation over a soft fibroma of the nipple. The Journal of Dermatology 1993; 20 (7): 447-448.

Author Information

Ketan Vagholkar, Dr, MS, DNB, MRCS, FACS.

Department of Surgery. Dr. D.Y.Patil Medical College

Navi Mumbai. India

kvagholkar@yahoo.com

Shalini Nair, MS

Department of Surgery. Dr. D.Y.Patil Medical College

Navi Mumbai. India

Swapnil Tople, Dr, DNB

Department of Surgery. Dr. D.Y.Patil Medical College

Navi Mumbai. India

Indumati Gopinathan, Dr, MD

Consultant Pathologist. Clinicopathological Labs

Mumbai. India