

# Retrocaecal Appendicular Perforation Causing Retroperitoneal Abscess Extending To Mediastinum With Pneumomediastinum.

B Suresh, L Ramachandra, S Charudut

## Citation

B Suresh, L Ramachandra, S Charudut. *Retrocaecal Appendicular Perforation Causing Retroperitoneal Abscess Extending To Mediastinum With Pneumomediastinum..* The Internet Journal of Surgery. 2012 Volume 28 Number 2.

## Abstract

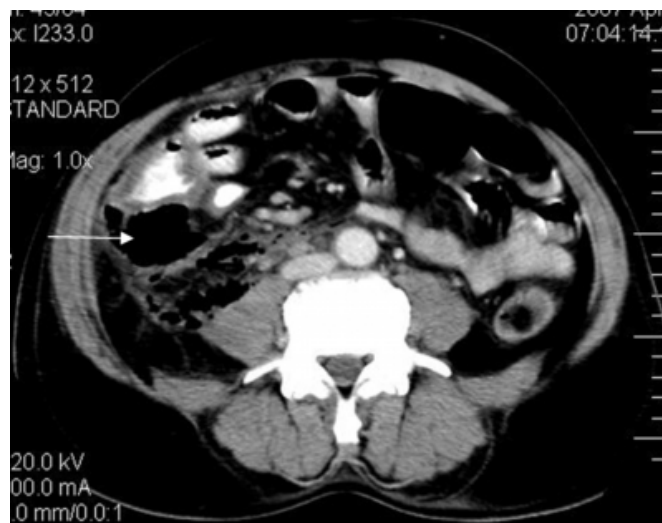Most of the time, the diagnosis and treatment of appendicitis are straightforward. However, a missed diagnosis can sometimes lead to life-threatening complications. While uncomplicated appendicitis can easily be treated, complicated appendicitis with perforation and abscess formation remains a challenging treatment. We present a case of retroperitoneal abscess secondary to retrocaecal perforated appendix; because of delay in treatment, the abscess extended to the mediastinum. The patient died during the post-operative period because of septicemia due to complicated retrocaecal appendicular perforation.

## CASE REPORT

A 54-year-old male presented with complaints of fever, pain and distension of abdomen for three days. At admission, the patient had tachycardia and tachypnoea. Abdominal examination revealed distension of abdomen, diffuse abdominal tenderness along with guarding, rigidity and absent bowel sounds. Decreased air entry in the mid and lower zone of the left lung was noted. Total leucocyte count was 18,700/ $\mu$ L. Chest X-ray showed air-space opacification in the left mid and lower lung zones (Fig. 2A). CT scan showed retroperitoneal air pockets with inflammation and ischemic changes in caecum and ascending colon (Fig. 1A & 1B) with pneumomediastinum and left-sided empyema (Fig. 2B). Possibility of retroperitoneal hollow visceral perforation was considered. Exploratory laparotomy showed retrocaecal appendicular perforation with abscess extending to the retroperitoneum. About 500ml of pus was drained. This retroperitoneal abscess also extended to the mediastinum through the esophageal hiatus. While draining pus from the mediastinum, a sudden passage of air was noted. Appendectomy was done. On the second post-operative day the patient developed multi-organ dysfunction syndrome due to septicemia and died.

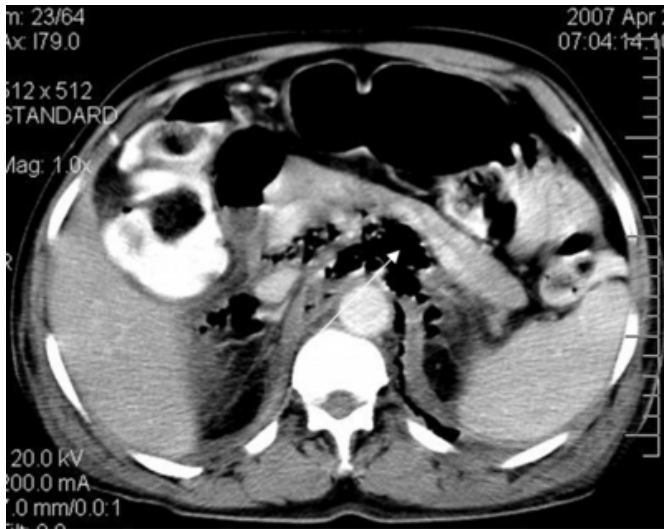
## Figure 1

Figure 1A: Contrast-enhanced axial image at the level of the caecum showing large collection of air in the retrocaecal area presumed to be secondary to perforation of retrocaecal appendix.



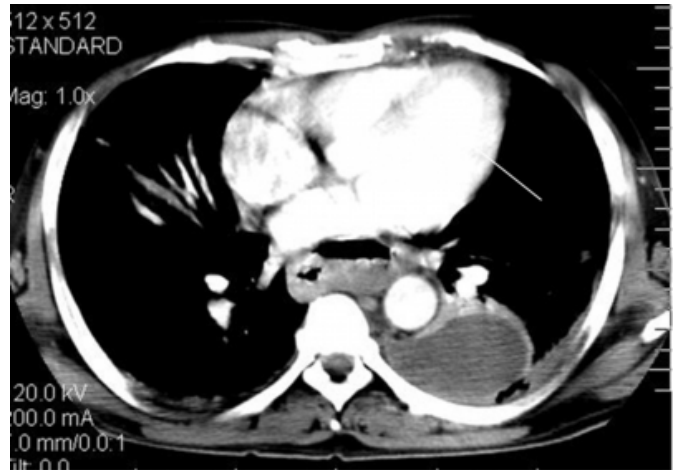
**Figure 2**

Figure 1B: Contrast-enhanced axial image at the level of pancreas shows extensive air in the retrocrural and paraaortic region.



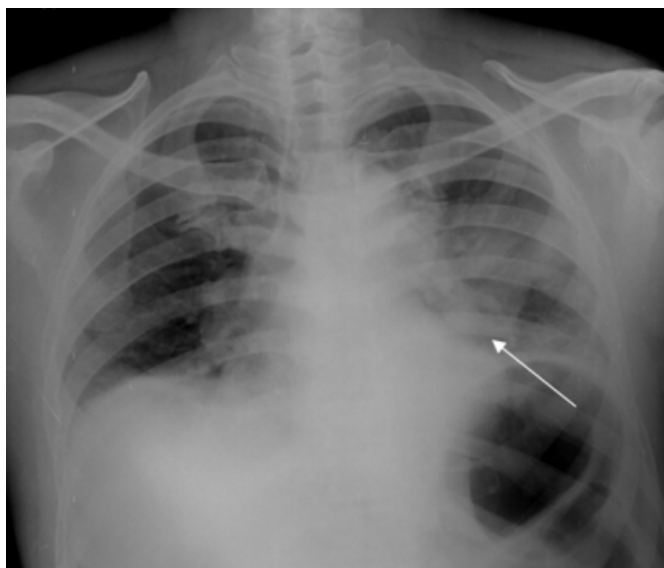
**Figure 4**

Figure 2B: Contrast-enhanced axial image at the level of the left atrium showing collection in the mediastinum between the esophagus and aorta and a loculated collection in the pleural cavity along the superior segment of the left lower lobe.



**Figure 3**

Figure 2A: Frontal chest radiograph reveals haziness in the left perihilar and paracardiac region silhouetting the cardia, confirmed on CT to be a loculated pleural effusion.



## DISCUSSION

Gastrointestinal perforation due to appendicitis, diverticulitis, or a carcinoma can cause retroperitoneal and psoas abscesses (1). Because of different positions of the appendix, a retroperitoneal perforation can cause atypical and confusing physical findings. After abscess formation has started, it may spread from the pelvis along the spine and psoas muscle up to the diaphragm and laterally to the abdominal wall since there are no anatomical barriers limiting its penetration (2). Infection and air can extend to communicating compartments, resulting in emphysema and abscesses in unexpected anatomical sites. An early appendectomy could help in preventing this extensive spreading of infection. For a definite diagnosis of acute appendicitis, CT scan of the abdomen is considered to be the imaging study with the highest accuracy and efficiency. Not only can it be of great help in diagnosis, but also in evaluating the extension of involvement. It also helps in approach for drainage of abscesses (3).

Hsieh et al. analyzed twenty-two cases of acute appendicitis, complicated by retroperitoneal abscess. Retroperitoneal abscesses involving thigh, psoas muscle, perinephric space and lateral abdominal wall occurring as a serious complication of perforated acute appendicitis have been reported in the literature [4, 5]. The high mortality rate in these cases was attributed to profound sepsis [4]. After intensive web and English literature search, this is the first

case report on retroperitoneal abscess extending to mediastinum with pneumomediastinum following retrocaecal appendicular perforation. We are reporting this case due to its rarity.

## **CONCLUSION**

We diagnosed a rare complications related to acute appendicitis. So we are trying to explain this rare complication following acute appendicitis, which helps in immediate recognition and adequate treatment to avoid deadly outcome.

## **References**

1. Ushiyama T, Nakajima R, Maeda T, Kawasaki T,

Matsusue Y: Perforated appendicitis causing thigh emphysema: A case report. J Orthop Surg; 2005; 13(1): 93–95.

2. Diana M, Paroz A, Demartines N, Schäfer M: Retroperitoneal abscess with concomitant hepatic portal venous gas and rectal perforation: a rare triad of complications of acute appendicitis. A case report. World J Emerg Surg; 2010; 28; 5:3.

3. Tomaso NB, Ultee JM, Vrouwenraets BC: Retroperitoneal Abscess and Extensive Subcutaneous Emphysema in Perforated Appendicitis: a Case Report. Acta Chir Belg; 2008; 108: 457-459.

4. Hsieh CH, Wang YC, Yang HR, Chung PK, Jeng LB, Chen RJ: Retroperitoneal abscess resulting from perforated acute appendicitis: analysis of its management and outcome. Surg Today; 2007; 37:762-767.

5. Sookraj KA, Bowne WB, Ghosh BC: Perforated appendicitis presenting as a thigh abscess. J Am Coll Surg; 2009; 208: 1142.

**Author Information**

**BP Suresh, MS**

Department of Surgery, Kasturba Medical College

**L Ramachandra, MS**

Department of Surgery, Kasturba Medical College

**Sambhaji Charudut, MD**

Department of Radiology, Kasturba Medical College