

# Subileus Caused By A Retroperitoneally Located Hydatid Cyst Disease: Case Report

M Yasar, M Çetin, U Cöbek

## Citation

M Yasar, M Çetin, U Cöbek. *Subileus Caused By A Retroperitoneally Located Hydatid Cyst Disease: Case Report*. The Internet Journal of Surgery. 2012 Volume 28 Number 2.

## Abstract

Hydatid disease (Hydatidosis) is an endemic parasitic disease of the Mediterranean countries. Although the liver is the most commonly involved organ, this disease can be seen anywhere in the body. Hydatid disease of the retroperitoneum is a very rare condition. Hydatid cysts with unusual localizations may cause serious problems. Early diagnosis is important, because prompt intervention enables efficient management and treatment of the disease and results in reduced morbidity and mortality. Initially, cysts are small and patients are asymptomatic. We report a case of a subileus in a 63-year-old male with the diagnosis of hydatid cyst of retroperitoneum, which was treated surgically.

## INTRODUCTION

Hydatid disease is a parasitic infection with worldwide distribution, especially in sheep and cattle-rearing regions of Australia, South America, the Middle East, South Africa, Eastern Europe, and the Mediterranean region (1). Hydatid disease (HD) is a parasitic infection caused by *Echinococcus granulosus* and less frequently by *Echinococcus multilocularis*. HD mostly occurs in the liver (59-75%), followed in frequency by lung (8.5-43%), and only 10-15% occur in other parts of the body (2). Although effective preventive and therapeutic measures have been developed for most parasitic helminths, cystic echinococcosis (CE) infection is still very common in the developing world today. CE, a widely chronic endemic helminthic disease caused by infection with metacestodes (larval stage) of the tapeworm *Echinococcus granulosus*, is one of the most widespread helminth zoonotic diseases in humans (3-4). Despite the advances in modern imaging and therapeutic strategies, problems associated with the diagnosis and treatments of human CE are still challenging and often difficult to resolve. Early diagnosis is important, because prompt intervention enables efficient management and treatment of the disease and results in reduced morbidity and mortality. Initially, cysts are small and patients are asymptomatic (5)

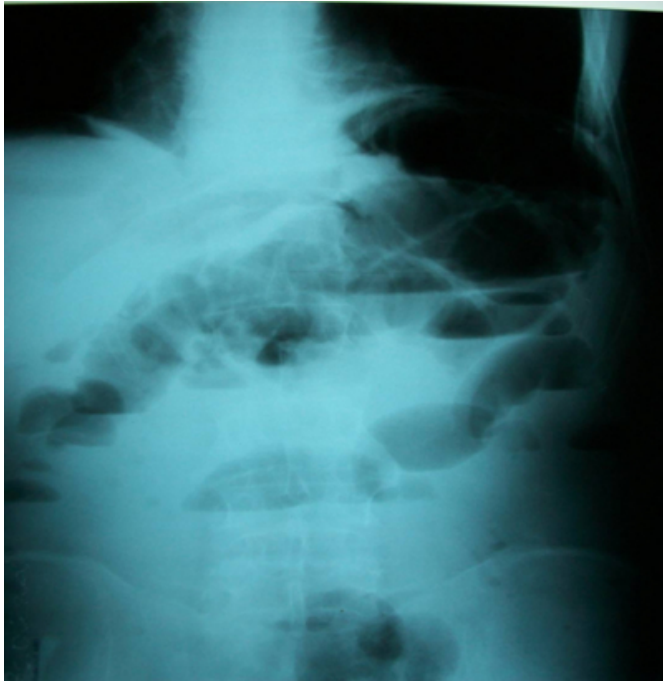
Localization of hydatid disease in the retroperitoneal space causing subileus is extremely rare.

## CASE REPORT

A 63-year-old man was admitted to our hospital with a swelling in the suprapubic region for 15 years. Physical examination revealed a palpable suprapubic tenderness. Laboratory examinations were normal. Ensuring workup included a positive serology for *Echinococcus*. Chest x-ray was within normal limits. Upright abdominal radiographs showed abnormal gaseous distension/dilatation of small bowel loops, with fluid levels (Figure 1). Ultrasound examination revealed a round thick-walled cyst close to the sigmoid colon. On the abdominal computerized tomography scan, a multilocular thick-walled round septated cyst of 10x8x7cm was seen (Figure 2). Total cystectomy with capitonage tube drainage and irrigation with betadine was the operation of choice for the hydatid cyst. Histopathological examination confirmed the diagnosis of a hydatid cyst (Figure 3). The patient was discharged on the fifth postoperative day.

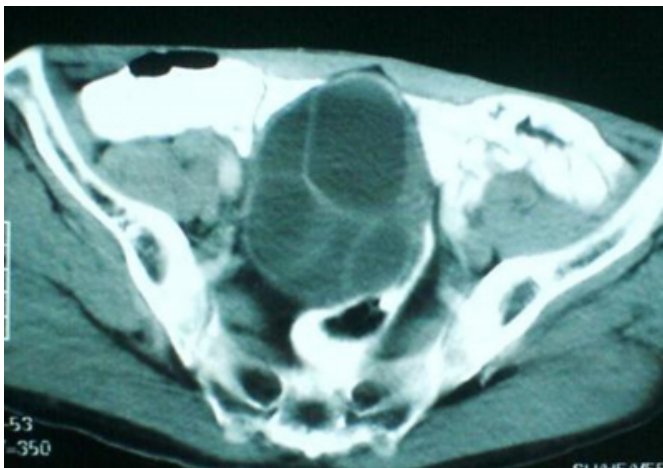
**Figure 1**

Figure 1: Upright abdominal radiograph



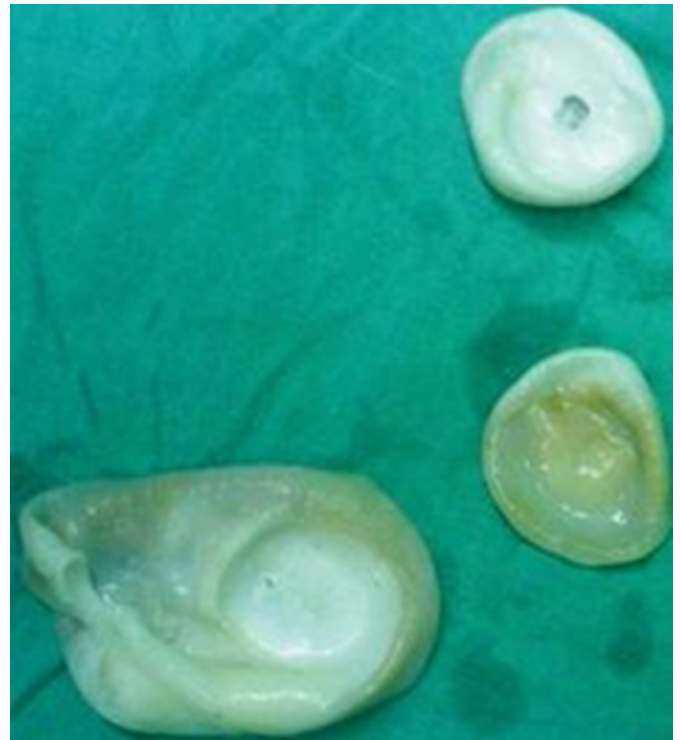**Figure 2**

Figure 2: A multilocular thick-walled round septated cyst of 10x8x7cm is seen on the abdominal computerized tomography scan.



**Figure 3**

Figure 3: Three daughter hydatid cysts taken from within the main cyst are seen.



## DISCUSSION

Hydatid disease is a parasitic infection with worldwide distribution, especially in sheep and cattle-rearing regions of Australia, South America, the Middle East, South Africa, Eastern Europe, and the Mediterranean region (1). In humans, HD is commonly caused by *E. granulosus* and less frequently by *E. multilocularis*. Adult *E. granulosus* tapeworms live in the intestinal tract of infected dogs. The excreted eggs are swallowed by intermediate hosts – sheep, cattle, goats or humans. After ingestion, the eggs are freed from their coating and larvae penetrate the mucosa of the jejunum and are carried to different regions of the body where they form small cysts. The liver acts as the first filter for the larvae whereas the lungs are the second filter. Most hydatid cysts occur in the liver (59–75%), followed in frequency by lung (8.5–43%) and only 10–15% occur in other parts of the body. In a patient with echinococcosis of the liver, right upper quadrant abdominal pain, hepatomegaly or a palpable mass are the most frequently seen symptoms. The most common complications are generalized toxic reaction due to hydatid cyst rupture and secondary infection (6). In our case, the patient complained of abdominal pain, epigastric fullness or a mass and constipation. On physical examination, we observed

abdominal distension and tenderness in the suprapubic region. The cyst was not ruptured. A hydatid cyst has three layers. The outer layer, or pericyst, shows the host response to the parasite and consists of modified host cells, fibroblasts, giant cells and eosinophils. The middle laminated membrane is acellular and permits the passage of nutrients, but is impervious to bacteria. The disruption of this layer predisposes to infection. The innermost layer is the germinal layer. The scolices develop from an outpouching of this layer known as the brood capsule. Freed scolices, together with the brood capsules, form the hydatid sand. Daughter cysts may form within the main cyst. The natural history of untreated hydatid cyst usually involves gradual enlargement and possible rupture with its complications (6). In our patient, the three-layered cyst was adherent to adjacent organs.

Hydatid cysts may be single or multiple, uniloculated or multiloculated and thin-walled or thick-walled. Various radiological features that favor the diagnosis of hydatid cyst include the presence of cyst wall calcification, daughter cysts and membrane detachment. The cysts are generally round or oval (7).

Although serology is particularly useful in assessing whether the disease is active or not, radiography, US and CT studies are important for a diagnosis of echinococcal disease (8). Plain abdominal X-rays may show calcifications of the cystic wall (9). In our patient, the cyst was round-shaped and diagnosed preoperatively by laboratory, ultrasound and CT findings

Despite the advances in modern imaging and therapeutic strategies, problems associated with the diagnosis and treatments of human cystic echinococcosis (CE) are still challenging and often difficult to resolve. Early diagnosis is important, because prompt intervention enables efficient management and treatment of the disease and results in reduced morbidity and mortality. Initially, cysts are small and patients are asymptomatic (5).

Theoretically, the best surgical method is total cystectomy; however, if it can not be performed because of dense adhesions to important anatomical structures, partial cystectomy should be the procedure of choice (8). Location

of hydatid disease in the retroperitoneal space is an extremely rare condition. The main finding in retroperitoneal echinococcosis is a palpable mass (9). After completing total cystectomy, we performed capitonage with 2/0 vicryl sutures.

In conclusion, we believe that hydatid disease can involve almost any part of the body in patients from endemic countries presenting with a cystic mass. It is very rarely seen retroperitoneally. The optimal treatment is total cystectomy regardless of the location. When this is impossible because of anatomical location or other factors such as adhesions to surrounding organs as also in our case, partial cystectomy, irrigation with scolecidals, and tube drainage of the cyst might be the suboptimal treatment (or we may choose omentopexy). If the cyst wall is sticking to the mesentery of sigmoid colon and also if the sigmoid colon is long, efficient omentopexy or resection of sigmoid colon would be preferred in order to avoid postoperative ileus. We believe that early diagnosis and treatment are required in retroperitoneal cyst hydatid disease (which is a rare form), because it can cause complications such as subileus.

### **References**

1. Tsaroucha AK, Polychronidis AC, Lyrantzopoulos N, Pitiakoudis MS, J Karayiannakis A, Manolas KJ, Simopoulos CE: Hydatid disease of the abdomen and other locations. *World J Surg*; 2005; 29: 1161-1165.
2. Polat P, Kantarci M, Alper F et al.: Hydatid disease from head to toe. *Radiographics*; 2003; 23: 475-94.
3. Thompson RCA: The taxonomy, phylogeny and transmission of Echinococcus. *Experimental Parasitology*; 2008; 119(4): 439-446.
4. Moro P, Schantz PM: Echinococcosis: a review. *International Journal of Infectious Diseases*; 2008; 13(2): 125-133.
5. Pawlowski ZS: Critical points in the clinical management of cystic echinococcosis: a revised review. In: Anderson FL, Ouhelli H, Kachemi M, editors. *Compendium on Cystic Echinococcosis in Africa and Middle Eastern Countries with Special Reference to Morocco*. Provo, Utah, USA: Brigham Young University Print Services; 1997; pp. 119-135.
6. Balik AA, Celebi F, Basglu M, Oren D, Yildiran I, Atamanalp SS: Intra-abdominal extrahepatic echinococcosis. *Surg Today*; 2001; 31: 881-884.
7. Ammann RW, Eckert J: Cestodes; Echinococcus. *Gastroenterol Clin North Am*; 1996; 25: 655-89.
8. Sofioleas M, Misiakos E, Manti C: Surgical treatment for splenic hydatidosis. *World J Surg*; 1997; 21: 374-8.
9. Spiliotis JD, Kakkos SK, Petsas T, Siablis D, Androulakis JA: Inguinal swelling: a rare presentation of retroperitoneal hydatidosis. *Eur. J Surg*; 1999; 165: 75-7.

**Author Information**

**Mehmet Yasar**

Assistant Professor, Department of General Surgery, Faculty of Medicine, Duzce University

**Mehmet Fuat Çetin**

Department of General Surgery, Faculty of Medicine, Duzce University

**Utku Can Cöbek**

Department of General Surgery, Faculty of Medicine, Duzce University