

A Rare Complication Of Colonoscopy: Subarachnoid Hemorrhage

O Ünsal, H Türk, M Açık, P Sayin, N Ediz, S Oba

Citation

O Ünsal, H Türk, M Açık, P Sayin, N Ediz, S Oba. *A Rare Complication Of Colonoscopy: Subarachnoid Hemorrhage*. The Internet Journal of Anesthesiology. 2012 Volume 30 Number 2.

Abstract

Colonoscopy-induced neurological complications are very rare, but they have high mortality and morbidity rates. Subarachnoid hemorrhage, which was the complication of colonoscopy, was reported in 1 case in literature and ended with death. We report this survived case to discuss this rare complication and emphasize the management of subarachnoid hemorrhage.

INTRODUCTION

Due to frequency of colorectal malignancies in industrial countries, diagnostic and therapeutic colonoscopy rates have increased dramatically. The most common complications of colonoscopy are bleeding and perforation of the colon (1,2). Neurological complications are very rare and have high mortality-morbidity rates (2,3). Colonoscopy-induced pain and anxiety affects patient hemodynamic responses. Anesthesia is recommended for comfortable colonoscopy procedures, which are invasive and can be painful (4). Anesthesia also reduces the adverse effects of the procedure. In this survived case, we aimed to discuss the rare complication of colonoscopy; subarachnoid hemorrhage.

CASE REPORT

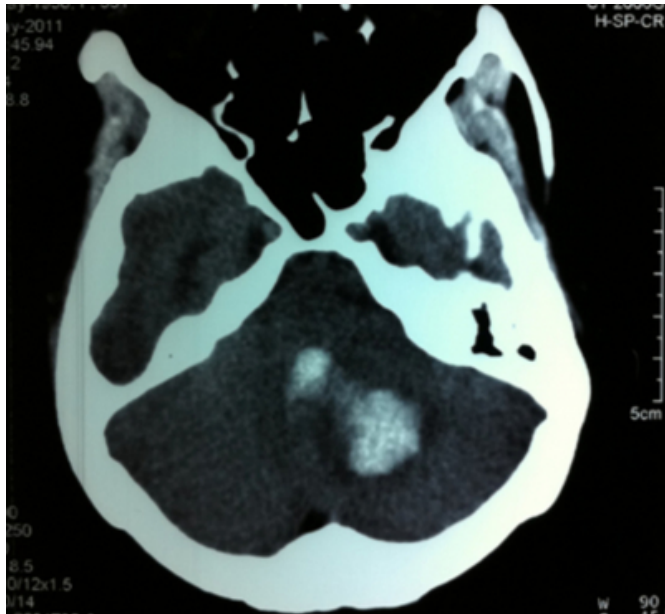
A 53-year-old female patient was admitted to our hospital's surgical endoscopy unit in order to undergo a colonoscopy examination due to persistent constipation. The patient had a history of cerebrovascular disease for two years along with an ongoing 10-year history of hypertension. No neurological sequela related to cerebrovascular disease was ascertained. She had been irregularly using acetylsalicylic acid 300 mg and cilazapril 5 mg tablets. She had not taken any of her medication in the last 15 days. Examinations implemented before colonoscopy revealed that her complete blood count, platelets and coagulation parameters were normal.

Colonoscopy screening was stopped temporarily so it could be carried out with anesthesia at a later time, since the patient could not tolerate the primary colonoscopy without anesthesia and the colonoscopist was not able to reach to the cecum. We consulted the patient for anesthesia in the

surgical endoscopy unit. Our non-Turkish speaking patient was informed with respect to the course of anesthesia for procedure with the help of her daughter's interpretation, and the patient's written consent was obtained. Meanwhile, she told us that she was suffering a headache. When monitored, her heart rate was 84 beats/minute, blood pressure was 134/110 mmHg, and SpO₂ was 98%; she was given 3 liters/minute of oxygen through nasal cannula. With 1.5 mg/kg propofol and 10 mcg/kg alfentanil, induction of anesthesia was achieved by the anesthesiologist. The procedure lasted 20 minutes, and no additional anesthetic need emerged. The patient was kept under supervision for 2 hours following the treatment. After 2 hours, a cranial CT was performed on the patient, who reacted to voice, shout only, by opening her eyes. In CT, subarachnoid hemorrhage into the fourth ventricle was detected (Figure 1).

Figure 1

Figure 1: Cranial CT. Subarachnoid hemorrhage from cerebellum into the fourth ventricle



She was put under observation in the intensive care unit. She was consulted with neurosurgeons. External drainage was implemented along with anti-oedema treatment with mannitol and dexamethasone. On the second day, she was referred to neurosurgery service with a condition of consciousness, drowsiness, and stabile hemodynamics. On the fifth day, external drainage was removed, and on the seventh day, the patient was discharged from the hospital. Upon neurological examination during the discharging process, her deep tendon reflex on the left crania was hyperactive, and on sensorial examination, there was hypoesthesia at L4-5, S1. Her muscle strength at left upper and lower extremities was 4+. Physical treatment and neurosurgery polyclinic follow-up were suggested.

DISCUSSION

Colonoscopy is performed safely and routinely in the diagnosis, treatment, and follow-up of colorectal diseases. The most common complications are bleeding and perforation of the colon. In a study, the overall rate of complications in the course of colonoscopy was determined as 2.9/1000. It is ascertained that a good number of these complications relate to colon perforation and bleeding. Pneumothorax, pneumomediastinum, hemoperitoneum, and splenic rupture are rarely seen, yet are highly likely to have mortal complications (1). Nevertheless, neurological complications with high mortality and morbidity are rarely reported. A 47-year-old female patient, Erden et al reported,

develops subarachnoid hemorrhage as a consequence of arteriovenous anomaly although she has no known systemic disorder, and the case resulted in death (3). Rathgaber et al.'s huge series of studies related to complications of colonoscopy report only one posterior circulation stroke as a neurological complication (2).

Intracranial hemorrhage is one of the common neurological diseases with high rates of mortality and morbidity. Most prominent causes are trauma, hypertension, aneurysm, arteriovenous malformations, tumor, and bleeding diathesis. During colonoscopy, an increase in intra-abdominal pressure and consequently, an increase in intracranial pressure are detected, and this condition induces hypertension (5). This type of hemodynamic change may cause intracranial hemorrhage in patients with cerebrovascular disease. Age, hypertension, hyperlipidemia, use of anticoagulant, arterial fibrillation, and history of stroke are all reported to augment the risk of complication in endoscopy (6). In our case, hypertension and history of cerebrovascular disease are the risk factors. The use of acetylsalicylic acid, too, is a risk factor. Whereas, the fact that our patient had not used the acetylsalicylic acid for a period of 15 days, and moreover, the normalcy of the number of platelets and coagulation parameters resulted in our exclusion of bleeding diathesis. Endoscopists may control risk factors with the detailed anamnesis before the colonoscopy procedure.

Despite the fact that there are publications claiming the applicability of colonoscopy without anesthesia, the common opinion is that it ought to be implemented with sedation or general anesthesia (7,8). The use of anesthesia in the course of colonoscopy affects patient comfort and examination success. Furthermore, it pressurizes hemodynamic responses. Pressurization of hemodynamic response blocks the development of rare complications that increase mortality and morbidity rates. Colonoscopy treatment must be performed by authorized people, the patient group exposed to anesthesia must be assessed elaborately, the selection of anesthetic agents must be correctly executed, and patients must be monitored closely after the procedure.

References

1. Singh H, Penfold RB, DeCoster C, Kaita L, Proulx C, Taylor G, et al. Colonoscopy and its complications across a Canadian regional health authority. *Gastrointest Endosc* 2009;69(3):665-71.
2. Rathgaber SW, Wick TM. Colonoscopy completion and complication rates in a community gastroenterology practice. *Gastrointest Endosc* 2006;64(4):556-62.
3. Erden M, Önder E, Doğan S, Güngör A, Celbek G,

Coşkun H, et al. An Unusual Mortal and Unpredicted Complication of Colonoscopy: Severe Subarachnoid Haemorrhage: Case Report. Türkiye Klinikleri J Gastroenterehepatol 2011;18(3):51-4.

4. Madan A, Minocha A. Who is willing to undergo endoscopy without sedation: patients, nurses, orthephysicians? South Med J 2004;97:800-5.

5. Vegar-Brozovic V, Brezak J, Brozovic I. Intraabdominal hypertension: pulmonary and cerebral complications.

Transplant Proc 2008;40(4):190-2.

6. Blacker DJ, Wijidicks EF, McClelland RL. Stroke risk in anticoagulated patients with atrial fibrillation undergoing endoscopy. Neurology 2003;61(7):964-8.

7. Lazzaroni M, Bianchi-Porro G. Premedication, preparation, and surveillance. Endoscopy 1999;31:2-8.

8. Sporea I, Popescu A, Sandesc D, Salha CA, Sirli R, Danila M. Sedation during colonoscopy. Rom J Gastroenterol 2005;14(2):195-8.

Author Information

Oya Ünsal

Department of Anesthesiology and Intensive Care Medicine, Şişli Etfal Training and Research Hospital

Hacer ?ebnem Türk

Department of Anesthesiology and Intensive Care Medicine, Şişli Etfal Training and Research Hospital

Mehmet Eren Açık

Department of Anesthesiology and Intensive Care Medicine, Şişli Etfal Training and Research Hospital

P?nar Sayın

Department of Anesthesiology and Intensive Care Medicine, Şişli Etfal Training and Research Hospital

Naim Ediz

Department of Anesthesiology and Intensive Care Medicine, Şişli Etfal Training and Research Hospital

Sibel Oba

Department of Anesthesiology and Intensive Care Medicine, Şişli Etfal Training and Research Hospital