

Management Of Biliocutaneous Fistula: Fistulo-Duodenal Anastomosis - A Case Report.

A Mate, M Tapase, S Jadhav, S Deolekar, A Gvalani

Citation

A Mate, M Tapase, S Jadhav, S Deolekar, A Gvalani. *Management Of Biliocutaneous Fistula: Fistulo-Duodenal Anastomosis - A Case Report.* The Internet Journal of Surgery. 2012 Volume 28 Number 2.

Abstract

External biliary fistulas (biliocutaneous fistulas) are known to occur following trauma as well as surgery. These injuries are less common now because of a better understanding of anatomy and disease processes. When they occur, biliocutaneous fistulas are often associated with significant morbidity. Because of the difficulty of dissection, surgery is reserved for cases of failure of expectant and endoscopic management. Hepaticojejunostomy is the procedure of choice. Reports of fistuloenteric anastomosis are very rare. We present a case of a 40-year-old gentleman who presented to us with a biliocutaneous fistula following lateral pancreaticojejunostomy (Puestow procedure) with cholecystectomy and ligation of gastroduodenal artery pseudoaneurysm performed 4 months prior in a public hospital. After endoscopic retrograde cholangiopancreatography, which showed complete obstruction of common bile duct, the patient was electively subjected to surgery. Because of altered anatomy and the difficulty of the dissection, the fistulous tract was divided and anastomosed with the duodenum. Postoperatively, the patient recovered uneventfully and was doing well at 6-month follow-up.

INTRODUCTION

Biliocutaneous fistulas are unusual but known complications following hepatobiliary surgery. Chronic fistulas are associated with significant morbidity due to skin problems, malabsorption of fat-soluble vitamins, steatorrhea and rarely sepsis as a result of blockage of the fistulous tract.^[1] They are a challenge to a surgeon for management from many standpoints like metabolism, nutrition, hygiene, quality of life as well as surgery.^[2]

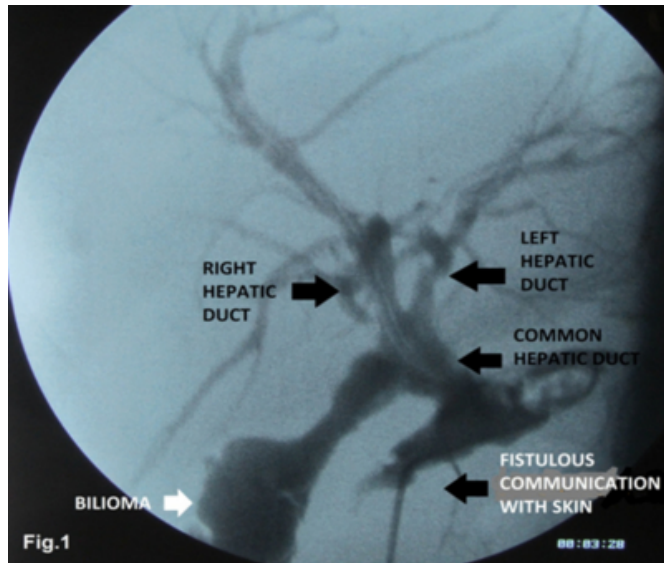
CASE HISTORY

A 40-year-old male presented in the emergency department with giddiness and fever. There was associated history of clay-colored stools and yellowish discoloration of urine with greenish discharge from a surgical abdominal wound since 4 months. The patient was operated on 4 months prior in a public hospital for chronic pancreatitis and gastroduodenal artery pseudoaneurysm based on CT scan findings. Lateral pancreaticojejunostomy (Puestow procedure) with cholecystectomy and ligation of aneurysmal vessel was done. Details of operation and imaging were not available. Oral feeds were started on postoperative day 6 and the patient was discharged. The patient gave history of greenish discharge from the surgical abdominal wound on postoperative day 13. He was given conservative

management. A fistulogram performed through the abdominal site demonstrated a bilioma and its communication with the biliary tree. [Fig. 1] Conservative management was continued. However, the patient did not improve and was referred to our tertiary centre for definitive management.

Figure 1

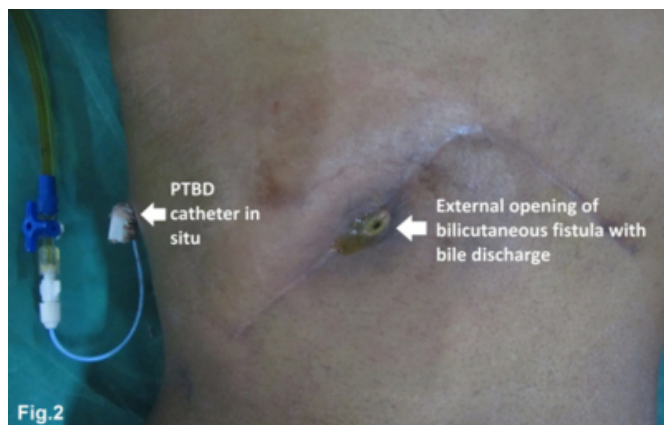Fig. 1: Fistulogram showing communication of biliocutaneous fistula with common hepatic duct and distal common bile duct obstruction with bilioma



On examination, the patient was hypotensive and had tachycardia. There was mild icterus. The abdomen was soft with bilious discharge from the right end of the Chevron incision. [Fig. 2] In view of cholangitis, antibiotics and intravenous fluids were started.

Figure 2

Fig. 2: External opening of biliocutaneous fistula on the right side of the Chevron incision with bile discharge. PTBD is in situ.

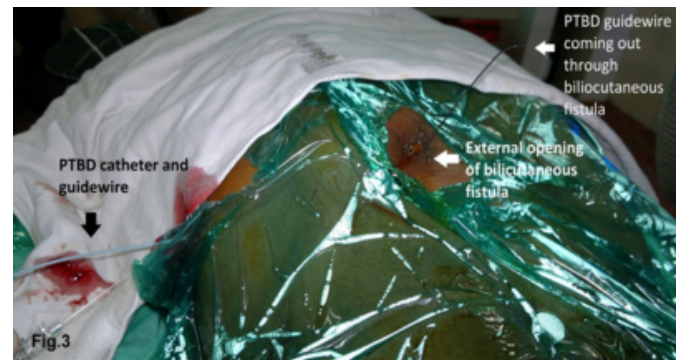

After initial stabilization, ultrasonography and computerized tomography of the abdomen were performed to rule out intra-abdominal collection. The patient was subjected to endoscopic retrograde cholangiopancreatography (ERCP) for delineation of biliary anatomy and therapeutic biliary stenting, if possible. It revealed a supraduodenal complete

stricture of the common bile duct. As it was not feasible to put a stent in the common bile duct during ERCP, a percutaneous catheter (PTBD) was inserted into the common hepatic duct for drainage of bile and for identification of the biliary system intra-operatively. [Fig.3]

Figure 3

Fig. 3: Percutaneous transhepatic guidewire coming out through the cutaneous opening of the biliocutaneous fistula



After optimization, the patient underwent surgery for definitive management. A right subcostal incision was made along the scar of previous surgery. The biliocutaneous fistula tract was identified and disconnected from the skin. The bilioma was drained. The fistula tract was dissected cautiously up to the common hepatic duct. Due to adhesions with vital structures at the porta hepatis, i.e. portal vein and hepatic artery, dissection was difficult beyond this point to obtain significant length of common hepatic duct for anastomosis. As the tract was epithelialised, a decision was made to perform an anastomosis between the fistula tract and intestine. The tract was divided and an anastomosis was performed between the proximal end of the fistulous tract and the duodenum with interrupted PDS sutures as the duodenum was adequately mobilized after kocherisation. [Fig. 4&5] The PTBD was kept in situ for proximal diversion of bile. The postoperative course was uneventful. Ryle's tube was removed and oral feeds were started on postoperative day 4 after appearance of bowel sounds. A cholangiogram performed through a percutaneous stent on postoperative day 8 showed no leak from the anastomotic site; hence, the drain and percutaneous stent were removed. Histopathology of the fistulous tract showed the presence of a fibrous tract with epithelilisation. The patient recovered uneventfully and was doing well on 6-month follow-up.

Figure 4

Fig. 4: Intraoperative photograph of fistuloduodenal anastomosis

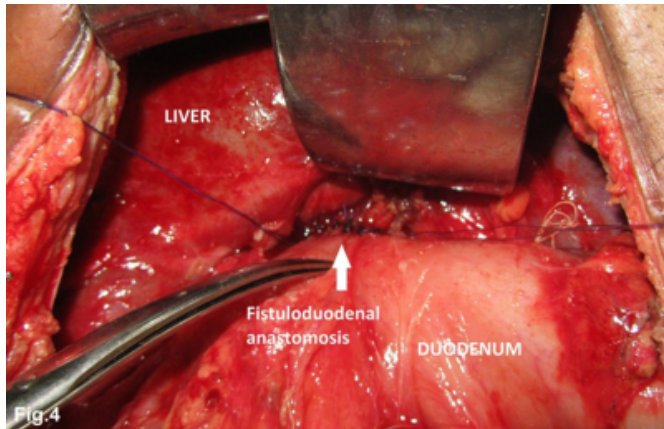
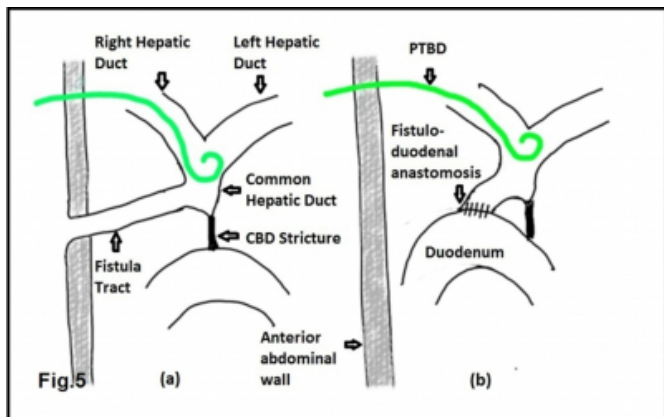


Figure 5

Fig. 5: Illustrative diagram showing; site of fistulous communication with biliary tree and fistuloduodenal anastomosis.



DISCUSSION

Injuries to the biliary tree are common after trauma and surgery. However, they usually result in biliary peritonitis or bilioenteric fistula. External biliary fistulas are less common now because of early diagnosis of biliary diseases and the advent of biliary surgery.^[3] They can result spontaneously as complications of acute suppurative cholecystitis associated with cholelithiasis.^[4] They may also follow blunt or penetrating abdominal trauma and hepatobiliary surgeries. Biliocutaneous fistulas have been reported following open cholecystectomy, liver transplantation, percutaneous liver biopsy, radiofrequency ablation for hepatocellular carcinoma, hydatid cyst surgery, etc.^[2, 5-7] Possible trauma to the bile duct in our case could have occurred during cholecystectomy or ligation of the pseudoaneurysm of the

gastroduodenal artery.

Patients usually present with bilious discharge through the abdominal wall with or without features of obstructive jaundice. Chronic fistulas are associated with significant morbidity due to skin problems, malabsorption of fat soluble vitamins, steatorrhea and rarely sepsis as a result of blockage of the fistulous tract.^[1] Diagnosis is obvious clinically. Communication with the biliary tree can be confirmed by a fistulogram as in our case. ERCP can be diagnostic as well as therapeutic in such cases. In cases in which ERCP fails, a PTBD can diagnose the communication as well as drain an obstructed system.

A significant number of such fistulas close spontaneously. Hence, the first line of management is conservative, particularly for low-output fistulas, i.e. fistulas draining less than 500ml per day.^[1,2,8] Zer et al. reported spontaneous closure of 4 out of 7 biliocutaneous fistulas in their series.^[8] Endoscopic management through ERCP with sphincterotomy, stenting or nasobiliary drainage, which reduces intrabiliary pressure, has showed encouraging results.^[1,6,7] Surgery is opted for only after failure of these modalities, as it may involve extensive dissection, and should be withheld for at least 3 months whenever possible.^[8] In our case, failure of ERCP to drain the biliary system due to supraduodenal obstruction was the indication for surgical intervention. Other modalities like selective biliary embolisation, percutaneous transhepatic catheter drainage, sclerosis with tetracycline, percutaneous cyanoacrylate, embolisation of the tract with gelatin matrix and oral nitrates are also described as promoting closure, provided the distal tract is patent.^[2,5,9] However, in our case it was not possible to use these modalities as the distal tract was not patent.

Operative procedures for refractory biliocutaneous fistula depend upon the anatomic site of the biliary tract disruption. Surgery of choice is usually a Roux-en-Y hepaticojejunostomy^[8] with the jejunal loop being sutured to the hepatic duct or directly to the liver capsule.^[2] Rarely, the actual fistula tract is used as a conduit and sutured to a loop of small bowel. The fistula tract is divided and its proximal end is anastomosed to a loop of intestine.^[10] Because of the difficulty of dissection and altered anatomy as a result of previous surgery, we opted for anastomosis between the fistulous tract and intestine. The duodenum was preferred as a site for anastomosis because of its adequate mobilisation after complete kocherisation and past history of lateral

pancreaticojejunostomy. Also, it gave us the added benefit of maintaining normal anatomical continuity of the intestinal tract for further interventions if required.

Internal drainage of biliary cutaneous fistula secondary to blunt liver trauma into the gallbladder has been described.^[10] De-epithelialisation of the skin opening of the tract and its direct usage in an anastomosis has been described by Morris et al.^[2]

In conclusion, biliocutaneous fistulas are less common but morbid complications of hepatobiliary surgery and are a challenge to the surgeon for management. Though many close spontaneously, endoscopic management may be required. Surgery is reserved for resistant cases. Fistuloenteric anastomosis is a valid approach if there is no existing external biliary system or if difficult anatomy does not allow drainage by conventional methods.

ACKNOWLEDGEMENT

We thank the Dean & Director (ME&MH), Seth GS Medical College and King Edward Memorial Hospital, Parel, Mumbai 400 012, for allowing the hospital data to be used for the case report

References

1. Musher DR, Gouge T: Cutaneous bile fistula treated with ERCP-placed large diameter stent. *Am Surg*; 1989; 55: 653-655.
2. Morris D, Ladizinsky D, Abouljoud M: Successful internalization of a chronic biliary cutaneous fistula after liver transplantation: deepithelializing the fistula tract. *J Gastrointest Surg*; 2007; 11(4): 538-541.
3. Ruderman RL, Laird W, Reingold MM, Rosen IB: External biliary fistula. *Can Med Assoc J*; 1975; 113(9): 875-878.
4. Urban CA, Urban LABD, Lima RS, Bleggi-Torres LF: Spontaneous combined internal and external biliary fistulae in association with gallstones and gliomatosis of the gallbladder. *Revista Brasileira de Cancerologia*; 2001; 47(3): 273-76.
5. Hatzidakis A, Petrakis I, Mantatzis M, Chamalakakis C, Chalkiadakis G, Gourtsoyiannis N: Bilio-cutaneous fistula formation after percutaneous liver mass biopsy: embolization of the tract with a gelatin matrix. *Int Surg*; 2006; 91(6): 341-4.
6. Tsujino T, Sasahira N, Hirano K, Tateishi R, Isayama H, Tada M et al.: Endoscopic management of biliocutaneous fistula after percutaneous radiofrequency ablation therapy for hepatocellular carcinoma. *Dig Endosc*; 2010; 22(1): 53-5.
7. Tzias V, Psatha P, Stergiopoulos S, Lagoudakis M: Left hepatic duct cutaneous fistula after right hepatic lobe hydatid cyst operation treated with nasobiliary tube. *Gastrointest Endosc*; 1999; 50(5): 710-1.
8. Zer M, Dintsman M: External biliary-pancreatic fistulas. *Int Surg*; 1977; 62(3): 175-178.
9. Kuran S, Disibeyaz S, Parlak E, Arhan M, Kacar S, Sahin B: Biliocutaneous fistula following alveolar hydatid disease surgery treated successfully with percutaneous cyanoacrylate. *Dig Dis Sci*; 2006; 51(1): 18-20.
10. Smith EE, Bowley N, Allison DJ, Blumgart LH: The management of post-traumatic intrahepatic cutaneous biliary fistulas. *Br J Surg*; 1982; 69(6): 317-318.

Author Information

Ajay D Mate, M.S., D.N.B. (Surgery).

Assistant Professor, Department of Surgery, Seth G.S.Medical College & K.E.M.Hospital

Manish S Tapase, M.B.B.S.M.S. (Surgery).

Registrar, Department of Surgery, Seth G.S.Medical College & K.E.M.Hospital

Sudhir Jadhav, M.B.B.S.M.S. (Surgery).

Assistant Professor, Department of Surgery, Seth G.S.Medical College & K.E.M.Hospital

Samir S Deolekar, M.S. (Surgery), M.R.C.S.

Associate Professor, Department of Surgery, Seth G.S.Medical College & K.E.M.Hospital

Anil K Gvalani, M.S. (Surgery) F.I.C.S.

Professor & Head, Department of Surgery, Seth G.S.Medical College & K.E.M.Hospital