

# Ultrasound Guided Vascular Access and Unusual Complications – Two Case Reports

A Riyat, R Baikady

## Citation

A Riyat, R Baikady. *Ultrasound Guided Vascular Access and Unusual Complications – Two Case Reports*. The Internet Journal of Anesthesiology. 2012 Volume 30 Number 2.

## Abstract

Ultrasound is being increasingly used to aid the placement of central venous catheters and has been demonstrated to decrease associated complications. However, catheter tip placement is not guaranteed using ultrasound, as we describe in two case reports. The first case described a central venous catheter passing into a tributary of the left brachiocephalic vein, and the second case describes the catheter tip close to the jugular bulb. We conclude with a discussion exploring the potential issues of left internal jugular vein catheterisation and inadvertent retrograde passage towards the jugular bulb.

## INTRODUCTION

In September 2002, the National Institute of Clinical Excellence (NICE) in the United Kingdom (UK) issued guidelines recommending the use of ultrasound (US) locating devices for placing central venous catheters<sup>1</sup> (CVC). It highlighted that out of the estimated 200,000 CVCs inserted annually in the UK's National Health Service, the complication rate of the traditional landmark technique is as high as 35%, the most common being arterial puncture, arteriovenous fistula, pneumothorax, nerve injury and multiple unsuccessful catheterisation attempts. We present two separate cases of rare complications of ultrasound guided CVC insertion. By reporting our cases we intend to highlight that although reducing a significant degree of complications, tip position of CVC is not guaranteed by using US.

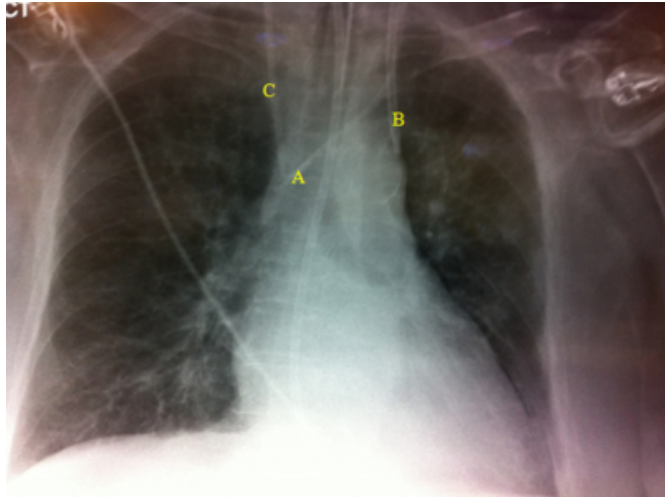
## CASE 1

The patient was a 64 year old female who presented with shortness of breath secondary to ST segment elevation myocardial infarction and pulmonary oedema. Respiratory failure necessitated invasive ventilation on the intensive care unit (ICU). She subsequently developed acute kidney injury requiring haemofiltration for which a large bore vascular access catheter (vas cath) was required. An existing CVC was in situ in the right internal jugular vein (IJV), but required replacement to minimise potential catheter-related infection. Therefore a new CVC and vas cath were planned with removal of the existing catheter. The left IJV was identified for the site of both.

The catheters were inserted by the first author (ASR, a final year anaesthesia trainee with full competency in ultrasound guided CVC insertion) in an aseptic manner using the Seldinger<sup>2</sup> technique. US was used in real-time to visualise the needle-tip entering the left IJV, following which a cannula was advanced. The needle was removed and after successful aspiration of venous blood from the cannula, a guide wire was passed into the IJV without resistance. The position of the wire was then confirmed using ultrasound to ensure it was within the IJV. The procedure was repeated (identically) to insert a second guide wire in close proximity to the first. After dilating the skin and subcutaneous tissues, a CVC (quad lumen CVC, Arrow International, Blue Flex Tip ref CV-22854, 16cm, 8.5F) was passed first over the wire into position, followed by the vas cath over the second wire. The CVC passed easily, blood was aspirated from all ports confirming position and it was sutured to the skin. However the vas cath (Dualyse Expert, 2 lumen, 20cm, 12F) passed easily over its wire until resistance was felt at 15cm, following which it was not possible to advance further. Blood was easily aspirated from both ports, as was flushing with 0.9% saline. The vas cath was sutured into position. Figure 1 shows the chest radiograph taken.

**Figure 1**

Figure 1. The radiograph shows satisfactory position of the CVC within the left IJV (A), but the tip of the vas cath can be seen to pass vertically (B). A right-sided CVC (C), endotracheal tube, nasogastric tube and ECG monitoring can also be identified.

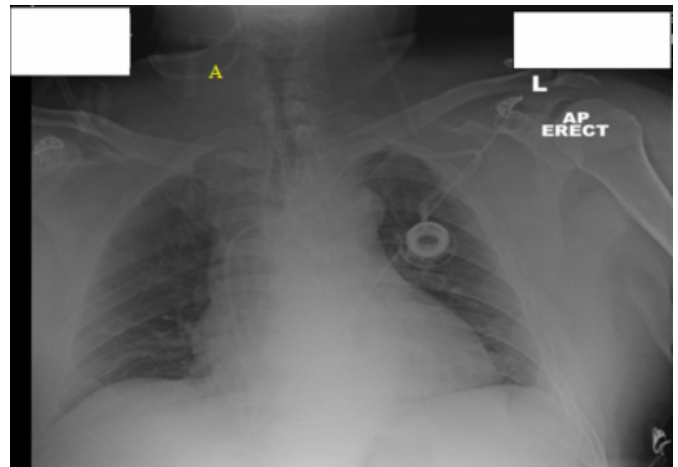


## CASE 2

A 63 year old male patient presented for elective right hemihepatectomy for metastatic large bowel carcinoma. He had previously received chemotherapy (via a portocath in situ). There was no other significant medical history of note. On examination he had a relatively short neck with a large neck circumference, which was identified pre-operatively to be a risk factor for anticipated difficult tracheal intubation and IJV cannulation. Following unremarkable induction of anaesthesia and tracheal intubation, a right-sided IJV CVC was inserted by the first author (ASR) using US in real-time as per the method described in case 1. There was no observed peri-procedure difficulty or complication. Blood was easily aspirated from all ports, as was flushing with 0.9% saline solution. There was no intra-operative concern or complication related to the CVC. The waveform displayed on transduction of the line was that consistent with central venous pressure. The post-operative chest radiograph in the ICU confirmed the tip position in right internal jugular bulb (figure 2).

**Figure 2**

Figure 2. The post-operative radiograph displays a portocath, ECG monitoring, nasogastric tube (with some coiling) and a right-sided CVC passing superiorly (A).



## DISCUSSION

Figure 1 displays the path of the vas cath, parallel to the left mediastinal edge, clearly distinct from the route of the central line, which is seen passing the expected route via the left IJV and left brachiocephalic (BCV). The tip of the vas cath is difficult to locate with precision using the chest radiograph alone. Unfortunately there was no further imaging taken. The line position was deemed satisfactory as venous blood was easily aspirated from both lumens despite the resistance to further advancement. Haemofiltration was unremarkable. Likely sites for the vas cath tip include smaller tributaries of the left BCV, such as the left internal mammary vein (IMV), left superior intercostal vein and pericardiophrenic vein. The absence of an arterial waveform excluded the possibility of the catheter tip lying in the descending aorta, another possibility. Schummer<sup>3</sup> described the possibilities of left IJV central venous cannulation, highlighting the often unconsidered presence of a left superior vena cava in up to 0.5% of the healthy population. It is clear that the tip does not lie in the same region at the tip of the central line, excluding this.

Catheterisation of the tributaries of the left BCV has been previously reported in a small number of case reports. It has been noted that left IJV catheterisation is associated with a higher risk of misplacement than the right<sup>4</sup>; an examination of the anatomy of the left-sided venous system explains this. Iconic<sup>4</sup> and colleagues describe the anatomical relationship of the left BCV and its smaller tributaries. The orifices of the left IMV and left pericardiophrenic vein lie directly opposite the junction of the left IJV and left subclavian vein, hence

cannulation via the left IJV can proceed directly inferiorly into either of these tributaries. Case 1 simultaneously highlights two possible pathways for CVCs to pass from the left IJV. Changes in portal pressures such as those seen in portal hypertension<sup>5</sup> can lead to dilatation of these smaller tributaries and the increased likelihood of their cannulation. In awake patients, some case reports have described pain in particular anatomical regions in the presence of CVC misplacements. Webb<sup>6</sup> described a number of cases, such as a patient who experienced intermittent precordial pain on infusion of total parenteral nutrition (TPN) via a CVC which was inadvertently placed in the left IMV, another patient who experienced localised left sternal pain on the infusion of TPN via a CVC also in the left IMV, and a third patient who described right sided chest pain on the administration of TPN via a CVC placed in the right IMV. Our patient was sedated and described no such symptoms.

Case 1 describes the only reported case of a vas cath inadvertently placed into a tributary of the left BCV, and also the first reported misplaced CVC inserted using US guidance. However, US did provide optimal conditions for placement. There was no noted deterioration in this patient's condition which could be attributed to the catheter misplacement, but it has been noted that cannulation of these smaller veins can lead to complications. In retrospect, taking into account the resistance felt at 15cm, it could be argued to have removed the line and re-attempt insertion, but we considered it satisfactory due to ease of aspiration and catheter flush, as well as achieving a central venous waveform. We did have a low threshold to remove the line at any stage if indicated.

Figure 2 displays the vertical path of the CVC passing superiorly towards the jugular bulb, instead of the expected path inferiorly towards the SVC. The main point of this case is to demonstrate that catheter tip misplacement can occur despite using US. At no stage during the insertion phase or during surgery was there any evidence to suggest the catheter tip had passed towards the skull. Jugular bulb cannulation is a technique used to measure cerebral blood flow and cerebral metabolism, but complications have been reported. Fumagalli<sup>7</sup> described a case report in which a right IJV retrograde cannula had inadvertently passed into the subarachnoid space of a patient who had suffered subarachnoid haemorrhage and subsequent coma. The

patient required immediate surgery. In hind sight US visualisation after the catheter placement could have identified the catheter misplacement. Our patient did not receive any inotropic drug through the CVC before X-ray imaging.

We would like to use these cases to illustrate that although US can reduce many complications associated with CVC insertion, the ultimate position of the tip cannot be assumed to be satisfactory until further imaging is performed. Since the publication of the NICE guidelines, it has been shown in a tertiary referral centre<sup>8</sup> that the complication rates associated with CVC insertion have decreased from 10.5% to 4.6%. But, catheter tip position ultimately needs to be confirmed using routine chest radiography, with further imaging such as computerised tomography where catheter tip position cannot be verified. In summary, we have described two cases of CVC catheter misplacement despite US guidance. The first illustrates the risks associated with cannulation of the left IJV, whilst the second is an example of how an unremarkable CVC insertion can still result in tip misplacement. We would like to clearly state we agree with the NICE guidance and would advocate to our colleagues to follow suit, but would like to emphasise that US alone will not exclude catheter tip misplacement.

### References

1. Guidance on the use of ultrasound locating devices for placing central venous catheters. National Institute of Clinical Excellence, 2002.
2. Seldinger, S. Catheter replacement of the needle in percutaneous arteriography (a new technique). *Acta Radio*, (1953); 39: 368-376.
3. Schummer, W et al. Persistent left superior vena cava and central venous catheter position: clinical impact illustrated by four cases. *Surg Radiol Anat* (2003) 25: 315-321
4. Ikonc, N et al. Are we underestimating the frequency of malpositioned central venous catheters inserted via the left internal jugular vein? A case report and short review of the literature. *Cent. Eur. J. Med*, 6(1), (2010);45-48
5. Liao, H et al. Rare malposition of a central venous catheter into the left internal mammary vein in a liver transplant patient. *J Anaes*, 2011;25:462-464.
6. Webb, J et al. Central venous catheter malposition presenting as chest pain. *Chest*, 1986;89:309-312.
7. Fumagalli, P et al. Retrograde cannulation of the jugular vein: erroneous positioning of the catheter in the subarachnoid space. *Br. J. Anaes* (1995);74:345-346.
8. Wigmore, T et al. Effect of the implementation of the NICE guidelines for ultrasound guidance on the complication rates associated with central venous catheter placement presenting for routine surgery in a tertiary referral centre. *Br. J. Anaes* (2007);99(5):662-665.

**Author Information**

**Amardeep S Riyat, FRCA**

Teaching Fellow in Medical Education, Anaesthesia and Critical Care, Imperial College London & NW London Hospitals NHS Trust

**Ravishankar Rao Baikady, FRCA**

Consultant in Anaesthesia, Royal Marsden Hospital