

Follicular Carcinoma Of The Thyroid Presenting As Distant Metastases: A Case Report And Review Of The Literature.

P Krishnappa, S Ramakrishnappa, M Kulkarni ., S Giriyan

Citation

P Krishnappa, S Ramakrishnappa, M Kulkarni ., S Giriyan. *Follicular Carcinoma Of The Thyroid Presenting As Distant Metastases: A Case Report And Review Of The Literature..* The Internet Journal of Laboratory Medicine. 2012 Volume 5 Number 1.

Abstract

Context: Follicular carcinoma of the thyroid presenting as a distant metastases is rare. Case Report: We present a rare case of a 42 year old patient with follicular carcinoma of the thyroid who presented with pathological fracture of the tibia at the time of diagnosis. The cytological samples from the fracture site showed follicular neoplasm. Histopathological study of the resected thyroid specimen showed a tumor with capsule and vascular invasion. Conclusions: The present case emphasizes that it is unusual for this neoplasm to initially present as distant metastases, although metastases in the late stages of the disease is more common presentation. Thyroid follicular carcinoma should be included in the differential diagnosis in cases of extrinsic tumoral lesions.

INTRODUCTION

Follicular thyroid carcinoma is the second most common thyroid cancer and is a slow growing tumor¹. It accounts for 10-20% of all thyroid malignancies². The lesion tends to occur in older age groups, with a peak incidence in the fifth decade. It is three times more common in females than in males. The tumor usually presents as an asymptomatic solitary intra-thyroid nodule. These neoplasms tend to metastasize hematogeneously, with lung and bone most commonly affected^{1,2}. The incidence of distant metastasis of follicular thyroid carcinoma has been reported as between 11 and 25%^{3,4,5}. However, Follicular thyroid cancer presenting

with metastases as initial presentation is very rare. We report and discuss the unusual presentation of this case.

CASE REPORT

A 42-year old female, presented with fracture tibia (left) after a trivial trauma. Radiological studies were suggestive of a pathological fracture (Image 1). The patient was examined for general survey and health. On general physical examination, she appeared to be in mild distress, poorly built and nourished. The vital signs were stable. The systemic examination was apparently normal. Examination of the neck revealed prominent right lobe thyroid.

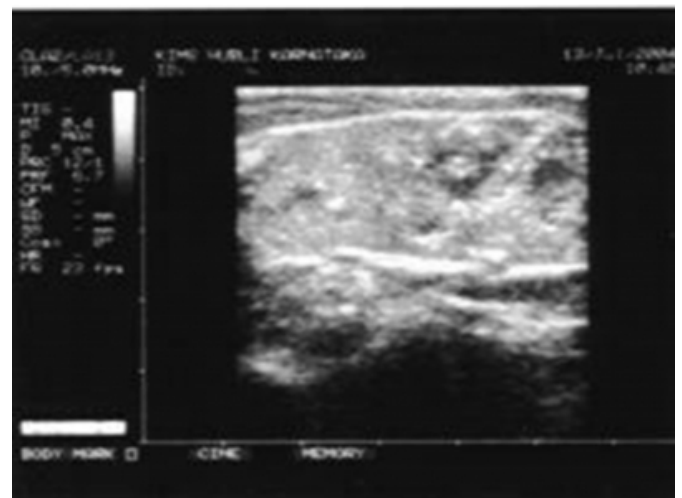
Figure 1

Image 1: X-ray left leg (showing pathological fracture in left tibia)

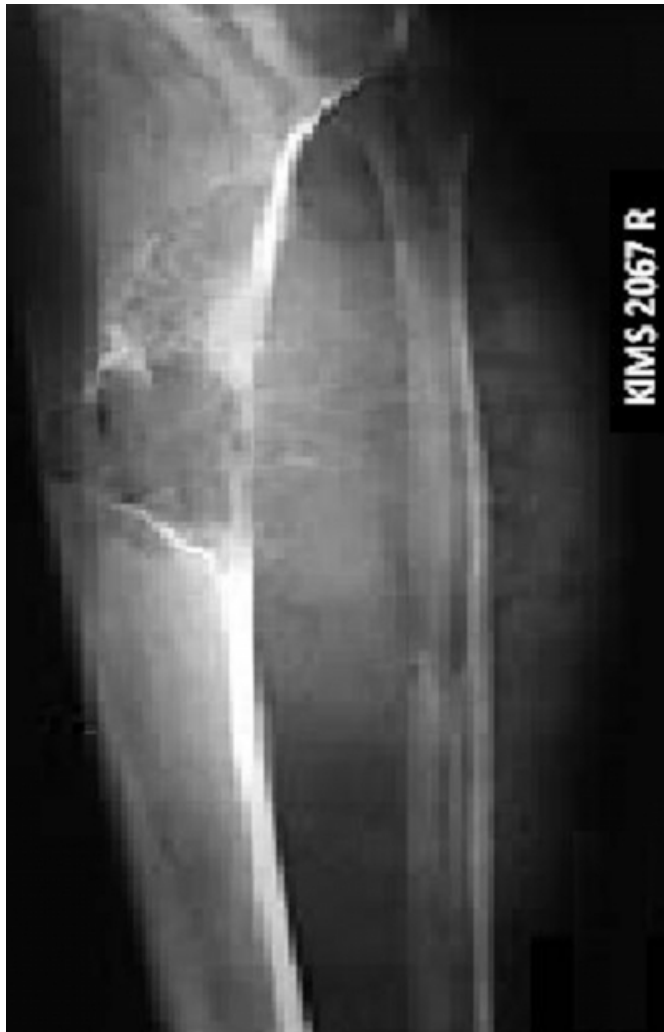

Figure 2

Image 2: Ultrasound Thyroid (Showing well delineated lesion in the right lobe of thyroid)



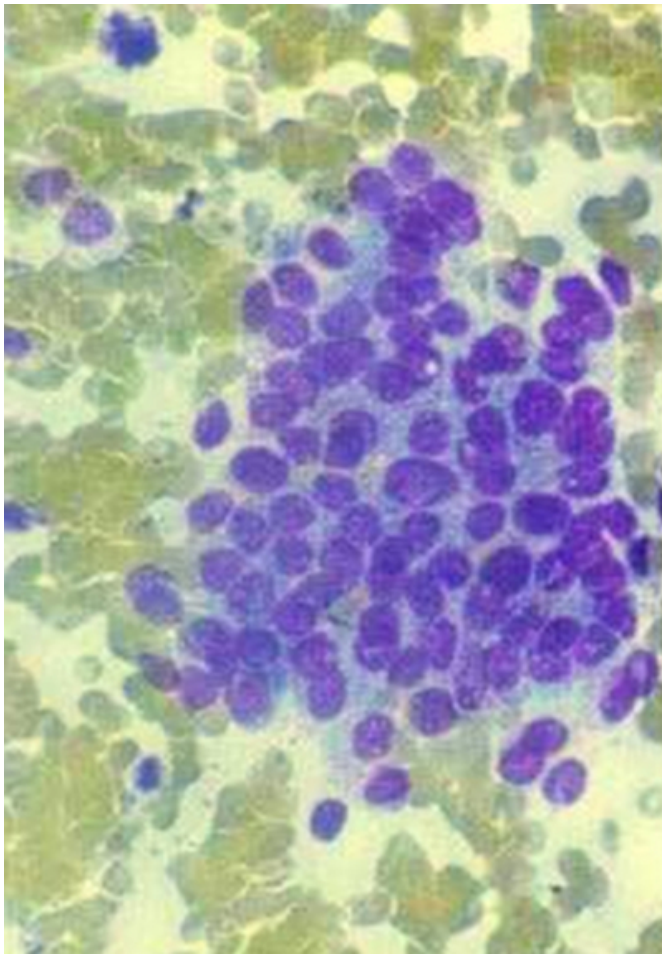
Fine needle aspiration was done from fracture site of tibia which showed features of follicular neoplasm (Image 3). Biopsy from the fracture site of tibia revealed metastatic follicular carcinoma thyroid.

The patient was further evaluated with ultrasound neck, which showed a well delineated lesion of 2cm in right lobe of thyroid (Image 2). The blood tests for thyroid hormones levels were in normal range. A working diagnosis of thyroid malignancy with metastases was made.

Further workup was initiated.

Figure 3

Image 3: FNAC Thyroid lesion (x40 Wright's stain)



The pathologic fracture of the left tibia was operatively repaired. She then underwent resection of the thyroid.

HISTOPATHOLOGY

The thyroidectomy specimen measured 5x4x4cm. The external surface was smooth and showed congested blood vessels. On sectioning, the right lobe of thyroid showed a single encapsulated lesion measuring 1.8 cm in diameter, two tiny satellite lesions around the main lesion each measuring 0.2cm.

The biopsy specimen from the fracture site of the tibia consisted of multiple pieces of bony fragments largest measuring 0.2x0.2x0.1cm. Histological study of all the specimens confirmed the diagnosis of follicular thyroid carcinoma. Capsular and vascular invasion was evidently seen.

DISCUSSION

Carcinoma of thyroid accounts for approximately 1% of malignancies¹. Follicular carcinoma is the second common malignancy of the thyroid only after papillary carcinoma⁷. Follicular carcinoma is more common in women, and tends to occur in patients in the fifth decade⁸. Follicular carcinoma has the higher mortality rate in comparison to papillary variant⁹ and is known for vascular invasion and metastases. It has been reported that the incidence of presentation with distant metastases of follicular carcinoma thyroid ranges from 11% to 25%^{3,4}. Disseminated metastases from follicular carcinoma thyroid as an initial presentation at the time of diagnosis is rare. Okutan et al presented a case of metastatic follicular carcinoma thyroid to the lumbar vertebrae¹¹. Shamim et al reported two cases of follicular carcinoma thyroid presenting as solitary skull metastasis¹². Tazi et al reported a case of thyroid carcinoma presenting as a dural metastasis mimicking a meningioma¹³.

In our case, the patient presented with metastatic disease i.e pathological fracture of the tibia as the chief complaint and later work up guided to the diagnosis of the thyroid malignancy. The unusual presentation delayed the diagnosis thus delaying the treatment for the patient. It demands a high clinical awareness and suspicion when encountered with pathological fracture. In such cases of metastasis of thyroid carcinoma, the literature emphasizes on treatment like total thyroidectomy and complete removal of metastatic foci^{14,15,16}. In summary, we present a rare case of a follicular carcinoma of the thyroid presenting as a metastatic disease in a relatively young patient.

CONCLUSION

Follicular carcinoma of the thyroid occasionally presents as metastatic disease with an occult primary. Metastatic thyroid carcinoma should be included in the differential diagnosis when evaluating a pathological fracture of the bone.

References

1. Rodrigues G, Ghosh A. Synchronous bony and soft tissue metastases from follicular carcinoma of the thyroid. *J Korean Med Sci* 2003;18: 914-916.
2. Mazzaferri EL. Papillary and follicular thyroid cancer: A selective approach to diagnosis and treatment. *Annu Rev Med* 1981;32: 73-91.
3. Girelli ME, Casara D, Rubello D, Piccolo M, Piotta A, Pelizzo MR. Metastatic thyroid carcinoma of the adrenal gland. *J Endocrinol Invest* 1993;16: 139-141.
4. Shaha AR, Shah JP, Loree TR. Differentiated thyroid cancer presenting initially with distant metastasis. *Am J Surg* 1997;174: 474-476.
5. Lin JD, Chao TC, Hsueh C. Follicular thyroid carcinomas with lung metastases: A 23-year retrospective study. *Endocr J* 2004;51: 219-225.

6. Parker SL, Tong T, Bolden S, Wingo P . Cancer statistics. CA Cancer J Clin 1996; 46: 5-28.
7. Kaplan EL. Principles of surgery. In: Schwartz SI, Shires GT, Spencer FC, editors. Thyroid and parathyroid. 5th ed. Singapore: McGraw-Hill Book Company, 1989: 1613-1685.
8. Sobrinho Simoes M, Asa SL, Kroll TG, Nikiforov Y, DeLellis R, Farid P, Kitamura Y, Noguchi SU, Eng C, Harach HR, et al. Follicular Carcinoma. In World Health Organization Classification of Tumors: Pathology and Genetics of Tumors of Endocrine Organs. Edited by DeLellis RA, Lloyd RV, Heitz PU, Eng C. Lyon: IARC Press; 2004:67-72.
9. Grebe SK, Hay ID. Follicular thyroid cancer. Endocrinol Metab Clin North Am 1995; 24: 761-801.
10. Fanchiang JK, Lin JD, Huang MJ, Shih HN. Papillary and follicular thyroid carcinomas with bone metastases: A series of 39 cases during a period of 18 years. Changeng Yi Xue Za Zi 1998; 21: 377-382.
11. Ozerk Okuntan Erkan Kaptanoglu Erdal Gocmen Ihsan Solaroglu Etem beskonakli Mahmut Koc. Metastasis of follicular carcinoma of the thyroid to the lumbar vertebrae: A case report. Turkish Neurosurgery 2005; 15(1), 32-35.
12. Muhammad Shahzad Shamim, Faraz Khursheed, Muhammad Ehsan Bari, Khalid Naseem Chisti, Syed Ather Enam. Follicular Thyroid Carcinoma Presenting as Solitary Skull Metastasis: Report of Two Cases. J Pak Med Assoc Oct 2008; 58(10):575-7.
13. Tazi E, Essadi I, Errihani H. Thyroid carcinoma presenting as a dural metastasis mimicking a meningioma: A case report. North Am J Med Sci 2011; 3: 39-42.
14. Goldstein SI, Kaufman D, Abati AD. Metastatic thyroid carcinoma presenting as distal spinal cord compression. Ann Otol Rhinol Laryngol 1998; 97: 393-396.
15. Scarrow AM, Colina JL, Levy EI, Welch WC. Thyroid carcinoma with isolated spinal metastasis: Case history and review of the literature. Clin Neurol Neurosurg 1999; 101:245-248.
16. Nam M, Chu YC, Choe W, Kim SJ, Hang SB, Kim YJ, Kim YS. Metastatic follicular thyroid carcinoma to the thymus in a 35-year-old woman. Yonsei Med J 2002; 43: 665-669.

Author Information

Purushotham Krishnappa, M.B.B.S.,M.D.

Department of Pathology, International Medical University

Sowmya Ramakrishnappa, M.B.B.S

Department of Anatomy, Malaysian Allied Health Sciences Academy

Mohan H Kulkarni ., M.B.B.S.,M.D

Department of Pathology, Karnataka Institute of Medical Sciences

Sujatha Giriyan, M.B.B.S.,M.D.

Department of Pathology, Karnataka Institute of Medical Sciences