

Hoffa's Disease In A Skeletal Immature Patient With Plica Syndrome - A Rare Case Report

R Sharma, S Gupta, N Saini, R Gupta

Citation

R Sharma, S Gupta, N Saini, R Gupta. *Hoffa's Disease In A Skeletal Immature Patient With Plica Syndrome - A Rare Case Report*. The Internet Journal of Orthopedic Surgery. 2012 Volume 19 Number 2.

Abstract

A rare case of Hoffa's disease in a skeletal immature patient with infrapatellar plica is presented. It was diagnosed by MRI and clinically confirmed and treated with a complete resection of the lesion. However, delay in the diagnosis and treatment ended the professional career of the player.

INTRODUCTION

Hoffa's disease is an obscure cause of anterior knee pain resulting from impingement and inflammation of the infrapatellar fat pad, although it was first reported by Albert Hoffa in 1904¹. To the best of our knowledge Hoffa's disease has not been seen in any skeletally immature patient. There are only sporadic cases reported. As per the most recent study of Carmont et al most of the patients with Hoffa's disease are seen in fifth decade or beyond². After a thorough search of literature we found the youngest patient was found to be of 37 years of age³. We describe a case of Hoffa's disease in an 18 year old girl active in contact sports (kho-kho sport) who was suffering from disease since the age of 13 years. To the best of our knowledge this is the first case of Hoffa's in skeletally immature patient.

CASE REPORT

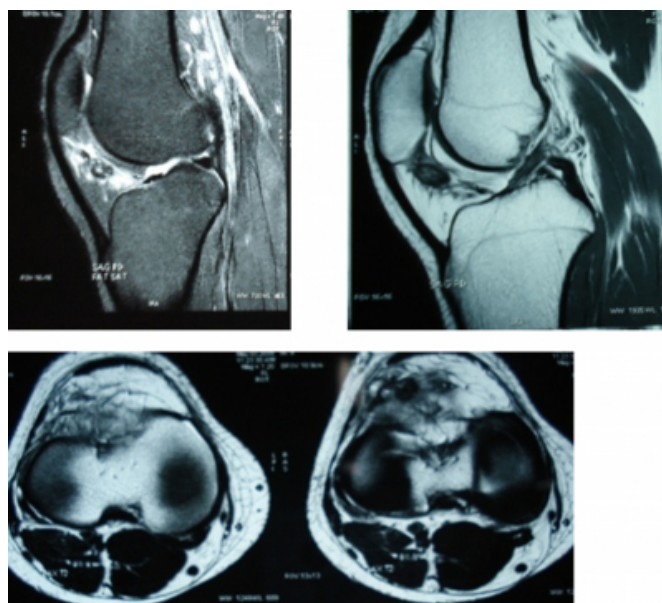
An 18 year old –female kho-kho player (traditional sport in India) patient presented to the out patient department of our institution in April 2009 with swelling of the right knee and inability to squat since childhood and anterior knee pain for about 5 years. 1 year back, she reported a history of direct local trauma while playing, with worsening of the knee pain, inability to fully straighten the knee. She consulted six different physicians and during all this period, the plain X ray of the knee joint done 5 times by different physicians reported as unremarkable, but was found to have raised blood uric acid levels and was advised synovial biopsy which was non conclusive. She had been treated conservatively with rest, analgesics and allopurinol with the diagnosis of gouty arthritis, growing pains, jumper's knee etc., but without any relief. Examination revealed a minimal

fullness in the lateral infrapatellar region. There was tenderness on palpation and hoffa's test was positive. Range of motion was from 10 – 100.

Repeated X ray examination were unremarkable; the last having been done 7 months back. MRI showed two small popcorn like lesions in the infrapatellar fat pad of Hoffa which displayed bright signal on fat-sat images indicating chondromas with oedema in the surrounding fat. Patellar tendon displayed normal signal intensity. Both menisci, cruciate ligaments and collateral ligaments were normal.

Figure 1

Figure 1: MRI picture showing the Hoffa's lesion in the fat pad.



The patient was taken up for arthroscopy right knee, which

revealed hypertrophied fat pad, plica extending from retropatellar fat tissue to intercondylar notch separating the medial and the lateral compartments, normal menisci . Through a lateral parapatellar approach complete resection of the thickened fat pad was done. Post-operatively quadriceps strengthening exercises were started. On post-op day 1, the patient was relieved of anterior knee pain. She visited the clinic on regular monthly follow up.

DISCUSSION

Liposynovitis prepatellaris, Launois-Bensaude's syndrome, Fat pad syndrome and Lipoid dermatoarthritis are all names used to describe Hoffa's disease³. Hoffa's disease or infrapatellar fat pad syndrome was first described by Albert Hoffa in 1904, and is characterized by the development of chronic inflammatory alterations associated with the impingement of the infrapatellar fat pad between the femorotibial and femoropatellar spaces. The process may be caused by major acute or by chronic repetitive traumas, resulting in hemorrhage and edema in the infrapatellar fat pad. This predisposes to fat pad hypertrophy which further results in impingement. This progresses to chronic inflammation which may be followed by chondroid metaplasia¹.

To the best of our knowledge there were no cases reported in skeletal immature patients and most were in or beyond the fifth decade². Our case noted infrapatellar swelling during childhood and was 13 years old when she developed anterior knee pain. 1 year back the knee pain increased after a fall on ground while playing kho-kho (A traditional sport in India in which the player has to squat for a while and stands up suddenly and runs once indicated by the other player)

Extraskelatal chondromas in the region of the knee joint are very rare tumors which may cause diagnostic problems. Magnetic resonance imaging allows evaluation of inflammatory alteration both at acute and chronic phases of the disease. Chondroid matrix may be identified as nodular areas with increased signal intensity on T2 weighted images. Hoffa's fat pad contains residual synovial tissue meaning that primary neoplastic conditions of the synovium may originate and be confined to fat pad⁴.

Differentiation from other lesions, particularly synovial osteochondromatosis and chondrosarcoma is essential to avoid unnecessary aggressive surgical procedures as marginal excision is adequate for these lesions⁵. Other differential diagnoses to be considered are: pigmented villonodular synovitis, calcinosis, osteochondrosis,

calcaneous tendinopathy, femur, tibia or even patella tumors with infrapatellar fat tissue invasion¹.

In this case the disease was diagnosed after 5 years which could have been earlier if an MRI was done at an early stage. We thus realize that one should not hesitate in using an MRI as a diagnostic modality where an early and accurate diagnosis is needed provided that MRI is indicated.

Most of the cases require surgical resection of the lesion . Both open⁶ and arthroscopic⁷ are feasible¹.

Plica syndrome of the knee is a constellation of signs and symptoms that occur secondary to injury or overuse. An otherwise normal structure, a plica can be a significant source of anterior knee pain. During embryonic development, the knee is divided initially by synovial membranes into 3 separate compartments. By the third or fourth month of fetal life, the membranes are resorbed, and the knee becomes a single chamber. If the membranes resorb incompletely, various degrees of septation may persist. These embryonic remnants are known as synovial plicae⁸.

Four types of synovial plicae of the knee have been described in the literature. The suprapatellar plica, or plica synovialis suprapatellaris, divides the suprapatellar pouch from the remainder of the knee. The mediopatellar plica is the most frequently cited cause of plica syndrome. The rare and poorly documented lateral synovial plica is a wider and thicker band than the medial plica. It is located along the lateral parapatellar synovium, inserting on the lateral patellar facet. The plica found to be the least symptomatic of all, the infrapatellar plica or ligamentum mucosum, is, ironically, the most commonly encountered plica. Some authors even claim this plica is never responsible for plica syndrome In our case the plica was probably the cause of difficulty in squatting since childhood. This bell-shaped remnant originates in the intercondylar notch, widens as it sweeps through the anterior joint space, and attaches to the infrapatellar fat pad. This plica's ability to obscure portal entry sites or interfere with visualization during arthroscopy is touted as its only significance.

Kim et al have classified ligamentum mucosum (ie, infrapatellar plica) into 5 groups, as follows⁹ :

Surgical intervention for plica syndrome should be considered when symptoms have persisted and efforts at nonoperative management have failed for a period typically approaching 6 months.

Until the age of 13 years our case was performing well in the sports, but in the last 5 years her performance has deteriorated. However, she could still play the game. Now for last 1 year following the trauma she could not play the game due to increased knee pain, decreased range of motion and inability to squat.

In our case, an arthroscopic examination, we saw a septum extending from intercondylar notch infrapatellar fat pad. This septum may be a separate entity or a part of a syndrome. So we propose that she developed plica syndrome during childhood. She continued playing and 1 year back she suffered trauma which might have precipitated the Hoffa's disease.

CONCLUSION

Hoffa's disease is usually seen in skeletally mature patients⁹. In the present case, the diagnosis was delayed for 5 years most probably due to lack of suspicion on the part of various physicians. The diagnosis was only clinched after the report of MRI examination. The 5 year delay in diagnosis confined our patient to the most restrictive activities thus resulting in loss of her career.

We report the rare occurrence of a para-articular chondroma

of the knee developing in a skeletally immature with infrapatellar plica. The development of Hoffa's disease at an early age in the presence of infrapatellar plica suggests they may be associated.

References

1. Rafael Burgomeister Lourenço, Marcelo Bordalo Rodrigues WHICH IS YOUR DIAGNOSIS? Radiol Bras 2007;40(3):IX-X
2. Michael R Carmont, Sian Davies, Daniel Gey van Pittius and Robin Rees Accelerated para-articular osteochondroma formation within the knee: a case report Cases J 2008, 1:6
3. Y. Emad1, Y. Ragab. Liposynovitis prepatellaris in athletic runner (Hoffa's syndrome): case report and review of the literature. Clin Rheumatol (2007) 26:1201-1203
4. D Saddik, E G McNally, M Richardson. MRI of Hoffa's fat pad. Skeletal Radiology, August 2004, 433-444.
5. Maheshwari AV, Jain AK, Dhammi IK Extraskelatal paraarticular osteochondroma of the knee--a case report and tumor overview. Knee. 2006 Oct;13(5):411-4. Epub 2006 Jul 11.
6. Mosher JF, Kettelkamp DB, Campbell CJ. Intracapsular or para-articular chondroma: a report of three cases. J Bone Joint Surg Am 1966;48: 1561-1569.
7. Krebs VE, Parker RD. Arthroscopic resection of an extrasynovial ossifying chondroma of the infrapatellar fat pad: end-stage Hoffa's disease? Arthroscopy 1994;10: 301-304.
8. Dupont JY. Synovial plicae of the knee. Controversies and review. Clin Sports Med. Jan 1997;16(1):87-122.
9. Kim SJ, Min BH, Kim HK. Arthroscopic anatomy of the infrapatellar plica. Arthroscopy. Oct 1996; 12(5):561-4.

Author Information

Rohit Sharma, MBBS; DNB (Ortho); MNAMS

Assistant Professor, Department Of Orthopaedics, SGRD Medical College

Sachin Gupta, MBBS; MS (Ortho)

Assistant Professor, Department Of Orthopaedics, SGRD Medical College

Nitin Saini, MBBS; DNB (Ortho)

Senior Resident, Department Of Orthopaedics, SGRD Medical College

Ravi Kumar Gupta, MBBS; MS (Ortho)

Associate Professor, Department Of Orthopaedics, Government Medical College