

# Percutaneous Reduction Of Femoral Fractures During Intramedullary Fixation: A Technical Tip

P Lorentzos, A Kanawati, G Shyan, F Hoe

## Citation

P Lorentzos, A Kanawati, G Shyan, F Hoe. *Percutaneous Reduction Of Femoral Fractures During Intramedullary Fixation: A Technical Tip*. The Internet Journal of Orthopedic Surgery. 2012 Volume 19 Number 2.

## Abstract

We have developed a simple technique of percutaneously reducing displaced femoral fractures; this is especially useful for those fractures that remain displaced and angulated in the sagittal plane while setup in traction on a fracture table. The technique requires use of 2 ring-handle Trethowan bone levers commonly found in most orthopaedic instrument trays. They are inserted percutaneously, one anterior and the other posterior to the proximal and distal fragments respectively. The levers use the stab incision in fascia lata, which is taut in traction, as fulcrum points to reduce the main fragments in a first class lever action. We cannot find any description of this technique in current literature.

## INTRODUCTION

Reduction of a displaced femoral fracture is a challenging task for many orthopaedic surgeons of all levels of experience, but is essential in intramedullary nail fixation to allow the passage of a guide wire across the fracture site. Open reduction is associated with more nonunions from disruption of soft tissue envelope with its blood supply to the fracture fragments<sub>1</sub>. Closed reduction using external manual pressure or with special instruments can be difficult because of the thick soft tissue envelope of the thigh. Femoral shaft fractures can be particularly difficult to reduce in a closed manner, especially when translated or off-ended. Subtrochanteric femoral fractures are also notorious for being fixed in non-anatomical positions, due to the short proximal fragment<sub>2</sub>.

We have developed a simple technique of percutaneously reducing displaced femoral fractures; this is especially useful for those fractures that remain displaced and angulated in the sagittal plane while setup in traction on a fracture table. The technique requires use of 2 ring-handle Trethowan bone levers commonly found in most orthopaedic instrument trays. They are inserted percutaneously, one anterior and the other posterior to the proximal and distal fragments respectively. The levers use the stab incision in fascia lata, which is taut in traction, as fulcrum points to reduce the main fragments in a first class lever action. We cannot find any description of this technique in current literature.

## SURGICAL TECHNIQUE

The patient is positioned supine on the fracture table in the routine fashion for an antegrade intramedullary nailing of the femur. The entry point and reaming of the proximal fragment is performed as per the recommended technique for the specific nail being used. The guide wire is passed into the proximal fragment.

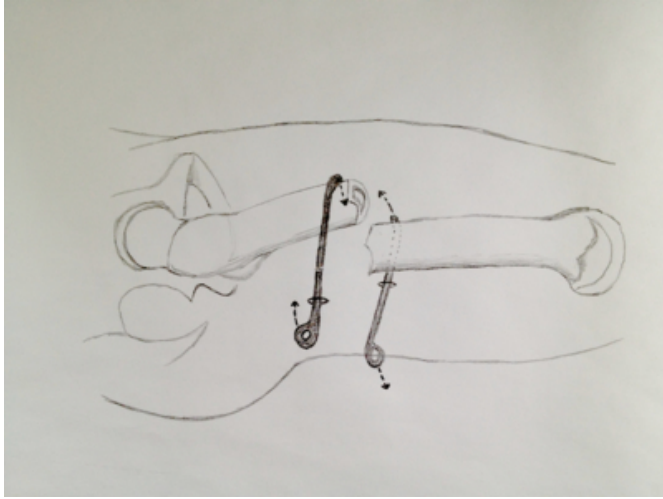
One or two ring-handle Trethowan bone levers (Figure 1) are required at this point. These slim instruments are ideal for percutaneous insertion, blunt tipped to minimize the chance of injury to vital structures and have a slightly curved tip to wrap around and engage the anterior and posterior surfaces of the femoral shaft. In some cases, only one bone lever will suffice, to manipulate the proximal or distal fragment. If this maneuver is not sufficient, the second bone lever can be inserted to gain the additional leverage required.

Antero-posterior image intensification is performed with the two levers lying on the skin of the anterior thigh to determine the level of the skin incisions on the lateral thigh. On the image intensification the proximal lever lies on the proximal fragment, the distal lever on the distal fragment, with both approximately 1-2cm from the main fracture site. Once the proximal and distal levels for the incisions are determined, stab incisions are made through the skin and fascia lata. The proximal incision should be made 2-3 cm posterior to the mid-lateral line of the thigh, and the distal incision should be made 2-3 cm anterior to the mid-lateral line (Figure 1). This will allow a bridge of fascia lata

between the bone levers.

**Figure 1**

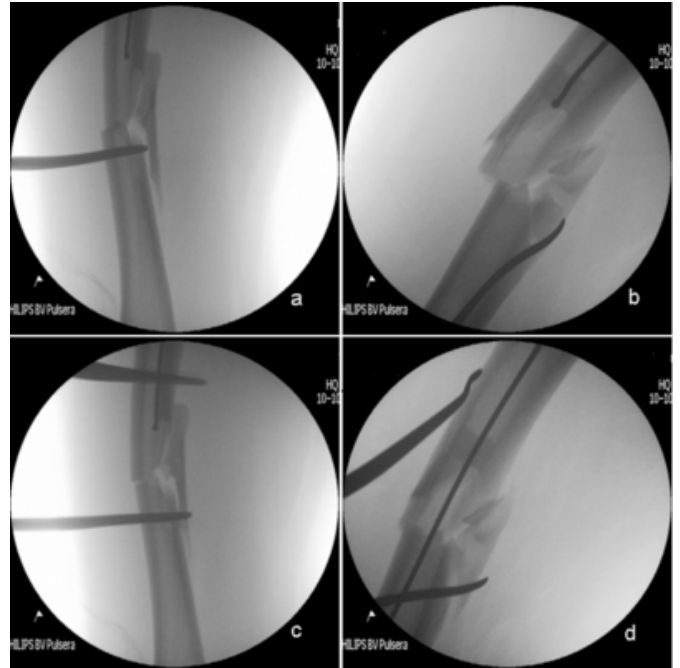
Figure 1: Diagram of typical placement of Trethowan bone levers.



The bone levers are bluntly passed through the vastus lateralis until they contact the shaft, where the proximal lever is positioned to lie on the anterior of the shaft, and the distal lever is passed to lie on the posterior surface of the shaft. The image intensifier is brought to give a lateral view of the fracture site. The handles of the bone levers are brought towards each other until the fracture is reduced sufficiently to allow the passage of the guide wire (Figures 2 and 3).

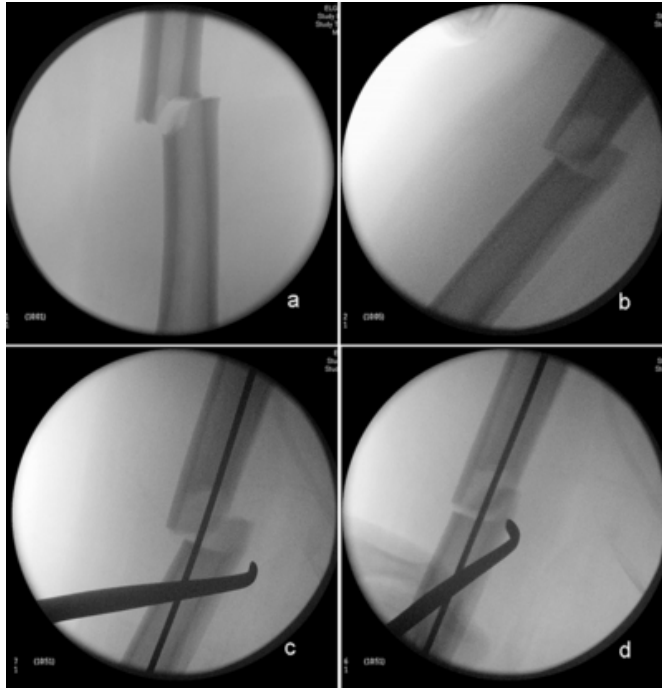
**Figure 2**

Figure 2: Trethowan bone lever placed on posterior aspect of distal fragment of a right mid-shaft femur fracture with posterior displacement, with guide wire in proximal fragment, anteroposterior view (a); lateral view (b). Bone lever placed on anterior aspect of proximal fragment, anteroposterior view (c); lateral view with the fracture reduced and the guide wire successfully passed (d).



**Figure 3**

Figure 3: Anteroposterior and lateral views of a right mid-shaft femur fracture with posteromedial displacement (a,b). Lateral views of the fracture, one bone lever placed on the posterior aspect of the distal fragment with the wire already passed (c); displacement corrected (d).



Percutaneous insertion of the bone levers could potentially cause neurovascular damage; particularly the descending branch of the lateral femoral circumflex artery anteriorly (from the proximal lever) and the perforating branches of the profunda femoris and sciatic nerve posteriorly (distal lever). To reduce the complication rate we recommend the levers should first contact the femoral shaft laterally and stay on the cortex as they pass anteriorly or posteriorly. Small haematoma may occur when the levers perforate the proximal bony attachment of vastus intermedius muscle (anteriorly), or the adductor and hamstrings origins at the linea aspera of the femur.

### OUR EXPERIENCE

The senior author has used the technique in the last 11 cases of mid-shaft femoral shaft fractures including comminuted subtypes, with sagittal plane displacement. This percutaneous reduction technique was successful in all cases without requiring other manipulation methods. The time taken to pass the guide wire once the bone levers were in position was usually 1-2 minutes. The senior author has also used the technique in subtrochanteric femoral fractures where it assists the reduction of the fractures at least in the

sagittal plane. No complications occurred as a result of the technique.

### DISCUSSION

The current gold standard for fixation of femoral shaft fractures has been intramedullary nail insertion as popularized by Küntschnner more than 50 years ago<sup>3</sup>. Closed nailing in closed fractures has the advantage of maintaining both fracture haematoma and periostium, while providing a stable fixation construct that can be applied using indirect reduction techniques<sup>4</sup>. If the canal is reamed, both osteoinductive and osteoconductive materials are produced at the fracture. There is still concern regarding the systemic pulmonary effects of reamed intramedullary nailing<sup>5</sup>.

Various methods have been described to reduce this fracture deformity when the surgeons chose to use a traction table. External strategies include a well-placed bump, crutch, F-clamp or mallet with an upward force applied on a sagging distal fragment. This reduction can be insufficient especially in patients with large body habitus, short proximal fragment (Fieldings Type I and II: less than 2.5cm from less trochanter), or too tiring and difficult for the surgical assistant to maintain the pressure for long periods<sup>2</sup>. Percutaneous techniques utilizing certain instruments such as bone hook, ball spike pusher, Schanz pins, a femoral distractor, temporary external-fixator or intramedullary reduction tool help by allowing the operator to 'joystick' the fragments<sup>6</sup>. These methods are often helpful in getting good fracture reduction but some instruments have sharp tips, which can potentially damage neurovascular structures, and also require the tools to be available or separate trays to be opened.

Proximal femoral shaft and subtrochanteric fractures (as defined by proximal femoral shaft fracture within 5 cm distal to the less trochanter) remain a unique challenge to many orthopaedic surgeons, requiring good fragment reduction for both guidewire insertion as well as preventing varus-flexion deformity from intramedullary fixation<sup>7</sup>. Proximal fragment tends to be flexed, abducted and in external rotation by the action of the iliopsoas, abductors and short external rotators respectively, though the latter two deformities often partially corrects with longitudinal traction on a fracture table<sup>8</sup>. Manipulation of the proximal fragment by insertion and levering with a intramedullary reduction tool can still be difficult when the proximal fragment is very short (ie 2-3 cm below the lesser trochanter) without any control of the distal fragments. Open reduction of this fracture type is known to

be associated with bone non-union and infection<sup>9</sup>.

Therefore many surgeons will try closed manipulation where possible to avoid such complications. Unfortunately it can be difficult to gain direct control of the fragments with strong muscle deforming forces and any external pressure on the fragments have to be transmitted through a thick soft tissue envelope. The development of a long locked intramedullary nail with an anterior bow inserted antegrade, with proximal fragment control via recon screws, has allowed improved fixation of this difficult fracture but requires good fracture reduction<sup>6</sup>.

The use of 2 Trethowan bone levers commonly found in standard orthopaedic operating sets avoid such problems. It is simple to use and obtain good fracture reduction quickly and, as this technique uses a first class lever system, can be managed by an operator of any physique. If the levers are removed any stage, the reduction obtained can be easily reproduced by reinserting the instruments through the small passage created previously. This frees the operator after guide-wire insertion, before nail insertion and proximal screw locking. It avoids unnecessary use of other orthopaedic equipment trays and reduces associated cost. A successful closed reduction also reduces potential nonunion and infection related to open reduction.

Limitations of this surgical technique are largely related to the reduction quality. While longitudinal traction on a fracture table usually improves the varus and valgus alignment deformity, where there is both sagittal and coronal displacement of fragments the levers can only control sagittal plane deformity and a third force is needed to reduce the coronal varus deformity<sup>3</sup>. This is applied externally (like a mallet) or percutaneously (using a Bristow bone elevator) on the distal end of the proximal fragment. In cases of subtrochanteric fractures with very short proximal fragment, the depression force involved to overcome the deforming forces can bend the proximal bone lever; a thicker Bristow bone elevator is used instead. When closed reduction is inadequate, the fracture should be opened to

ensure reduction is achieved. Open techniques should be employed that minimize soft-tissue dissection<sup>10</sup>. The use of clamps remains controversial, with good results being reported by Afsari et al. in a series of clamp-assisted reduction of subtrochanteric femoral fractures<sup>11</sup>.

### **CONCLUSION**

Many methods of closed manipulation of femoral fractures for intramedullary nailing exist, and require a strong assistant of good stamina, or special equipment. We have described a technical tip which we hope to be as useful to others as we have found in the management of this difficult fracture.

### **References**

1. Winquist RA, Hansen ST, Clawson DK: Closed intramedullary nailing of femoral fractures: A report of five hundred and twenty cases. 1984. *J Bone Joint Surg Am* 2001; 83:1912
2. Park J, Yang KH: Correction of malalignment in proximal femoral nailing—Reduction technique of displaced proximal fragment. *Injury* 2010; 41: 634-638.
3. Küntscher G; Rinne HH (trans): *Practice of Intramedullary Nailing*. Springfield, Ill: Charles C Thomas, 1967.
4. Ricci WM, Gallagher B, Haidukewych GJ: Intramedullary Nailing of Femoral Shaft Fractures: Current Concepts. *J Am Acad Orthop Surg* 2009;17:296-305.
5. Brumback RJ, Virkus WW: Intramedullary nailing of the femur: Reamed versus nonreamed. *J Am Acad Orthop Surg* 2000;8:83-90.
6. Wolinsky P, Stephen D. Femur shaft. In: Ruedi T, Buckley R, Morgan C, editors. *AO principles of fracture management*. 2nd ed., Stuttgart and New York: Thieme; 2007; 766–85.
7. Tornetta P III, Ritz G, Kantor A: Femoral torsion after interlocked nailing of unstable femoral fractures. *J Trauma* 1995; 38:213-219.
8. Koval KJ, Zuckerman JD: *Handbook of Fractures*, 3rd ed., Philadelphia: Lippincott Williams & Wilkins; 2006; 346-54.
9. Bhandari M: Ipsilateral femoral neck and shaft fractures. *J Orthop Trauma* 2003; 17:138-140.
10. Lundy DW, Subtrochanteric Femoral Fractures. *J Am Acad Orthop Surg* 2007; 11: 663-671.
11. Afsari A, Liporace F, Lindvall E, Infantejr A, Sagi HC, Haidukewych GJ. Clamp-Assisted Reduction of High Subtrochanteric Fractures of the Femur. *J Bone Joint Surg Am* 2009. 91:1913-1918.

**Author Information**

**P Lorentzos, MBBS Syd**

Orthopaedic Registrar, Westmead Hospital

**AJ Kanawati, MBBS UNSW**

Orthopaedic Registrar, Westmead Hospital

**G Shyan, MBBS Syd**

Orthopaedic Registrar, Westmead Hospital

**F Hoe, MBBS UNSW, FRACS (Orth)**

Orthopaedic Surgeon, Westmead Hospital