

# A Case of An Adult Synchronous Thyroglossal Cyst and Branchial Sinus: Case Report

M Kyi, T Zin, M Maw, R Paijan, M Abdullah, N Din

## Citation

M Kyi, T Zin, M Maw, R Paijan, M Abdullah, N Din. *A Case of An Adult Synchronous Thyroglossal Cyst and Branchial Sinus: Case Report*. The Internet Journal of Pathology. 2012 Volume 13 Number 2.

## Abstract

Congenital anomalies in the neck region are formed at birth, however, the resulting lump or complications related to them appear sometimes in later adult life. The thyroglossal duct cyst and branchial cleft cyst are the second most common congenital lesions.(1). Conversely, a synchronous presentation of thyroglossal cyst and branchial sinus in the same patient is really extraordinary and has not yet been reported to our knowledge. We report the first case of 44 year old adult patient with synchronous thyroglossal duct cyst and branchial sinus.

## INTRODUCTION

The thyroglossal cyst is one of the most often seen congenital asymptomatic masses of the neck region (2). The exact incidence of branchial cyst and related fistula is unknown. An estimated 2-3% of cases are bilateral. A tendency exists for cases to cluster in families. (3). Both conditions are the second most common causes of neck lumps. The Abhishek J study showed rare presentation of both thyroglossal and complete type branchial fistula (4). We present the first case report of thyroglossal cyst and right branchial sinus which appeared concurrently.

## CASE REPORT

Our patient is a 44-yr-old gentleman who had history of recurrent discharge from an opening located at right lower neck for a four year duration. Patient occasionally experienced slight pain when swelling appeared near the opening which was relieved after seropurulent discharge. He also had a lump on left upper part of the neck for five month duration which increased in size with time.

Clinically, there was a discharging opening situated at right lower anterior border of the sternocleidomastoid muscle. No signs of inflammation seen around the sinus, even though having minimal odorous discharge while squeezing. The lump on the left upper neck is firm, non tender and it moves on deglutition and protrusion of the tongue.(Figure 1)

According to the above findings, our clinical diagnosis is thyroglossal cyst and chronic skin sinus right lower neck. Ultrasound neck revealed multiloculated cystic lesion at the

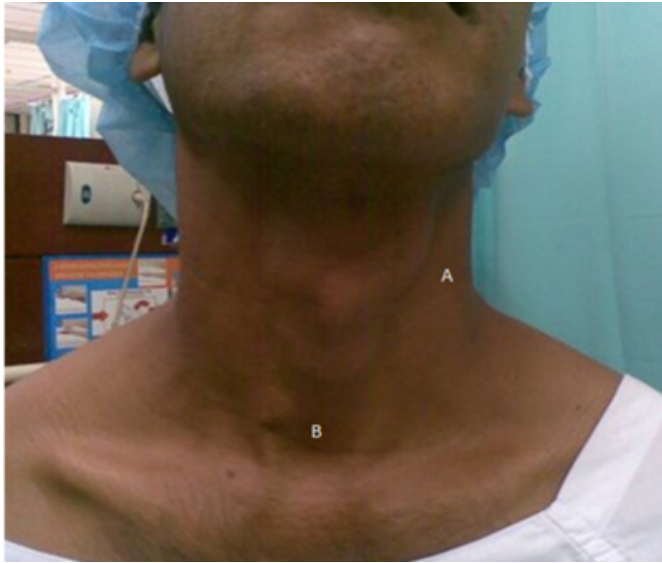
left upper neck likely of thyroglossal cyst. Sinus opening has short tract which ends within the subcutaneous tissue and no communication seen with thyroid gland or left paramedian cyst.

Patient was subsequently scheduled for removal of thyroglossal cyst and excision of skin sinus after the initial discussion with an ENT colleague.

During the operation, the thyroglossal cyst was removed completely together with part of the hyoid bone as a standard Sistrunk Operation. With an aid of ENT surgeon, excision of skin sinus was done through elliptical incision. Methylene blue was injected into the tract during dissection. Whole tract was removed with formal step ladder incisions, the upper blind end which blends with middle constrictor muscle.(Figure 2) Post operative period was uneventful and patient was discharged on day two. Histology of both specimens confirmed the diagnosis of thyroglossal duct cyst (Figure 3) and branchial sinus. (Figure 4)

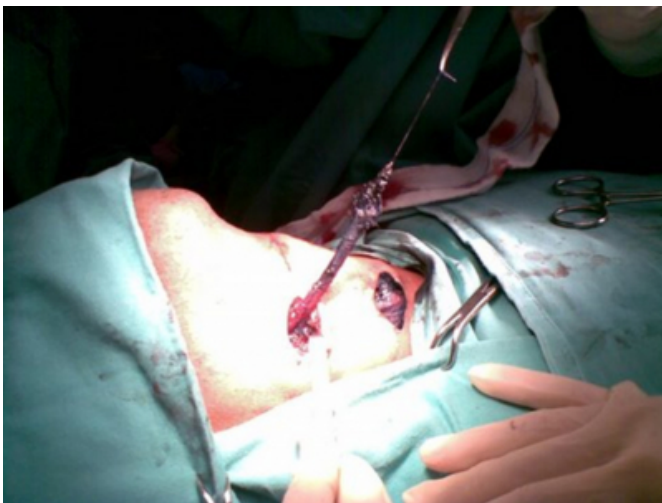
**Figure 1**

Figure 1. Patient with thyroglossal duct cyst (A) and synchronous branchial sinus on left lower part of the neck (B)



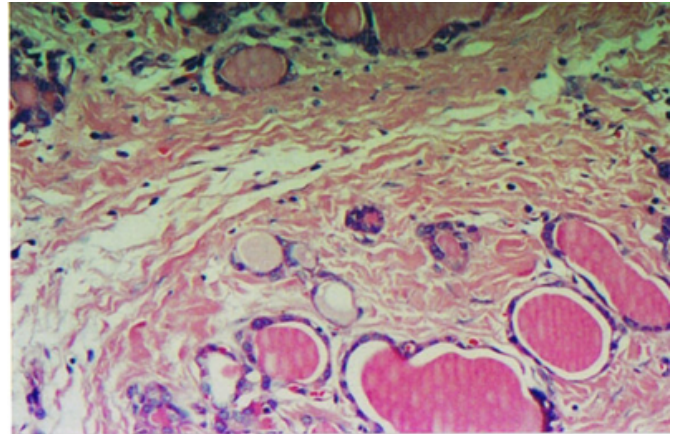
**Figure 2**

Figure 2. Step ladder incisions to excise whole Branchial sinus tract.



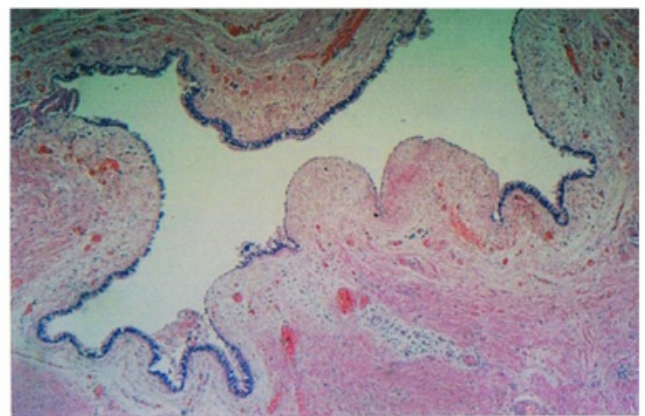
**Figure 3**

Figure 3. Histological Appearance of Thyroglossal Duct Cyst.



**Figure 4**

Figure 4. Histological Appearance of Branchial Sinus Tract



## DISCUSSION

Thyroglossal duct cyst and branchial apparatus abnormalities are the second most common causes of neck lumps. Again, Branchial sinus or fistula is one of the commonest causes of head and neck fistulae(5). Thyroglossal tract fistula accounts another important cause. Both conditions are common individually, and rarely seen both together, like in our study.

A thyroglossal duct cyst is the most common midline neck lump, which was formed from remnant of the thyroglossal tract(6). Majority of patients present with asymptomatic midline mass usually located at or below the level of the hyoid bone. According to previous studies, most of the patients showed up with this problem with an age of below 30. But interestingly, most recent studies mention a number of older patients with thyroglossal cyst with their age of 80s (1). Infection of cyst content can lead to fistula formation.

Recurrence thyroglossal tract from previous operation also had a chance to get fistula formation like in Abhishek J studies. (4).

The branchial cleft abnormalities may develop from any one of the branchial clefts from first to fourth branchial cleft. The most common abnormalities are found in second cleft. The external opening from second branchial cleft is usually located along the anterior border of the sternocleidomastoid near the junction of the lower and middle third portions. Infection and incision for the persistent branchial cyst lead to fistula formation. In our study, the branchial cyst was infected and ruptured spontaneously which formed branchial sinus.

According to the studies, 50% of branchial fistulae are externally drained sinuses. 11% of cases show complete fistula which drain respective regions at the oropharynx together with the type of the cleft involvement; like in second cleft fistula opens up at the tonsillar fossa. In our case, it forms as external sinus and remaining upper tract is obliterated and blended with middle constrictor muscle fibres.

Bailey (1933) mentioned stepladder incisions as a standard technique for removal of fistulous tract from second branchial cleft (7). We use methylene blue injection into the fistulous tract which facilitates the dissection. Other options to visualize the tract during the operation are injection, paraffin, or fast harden polymers in to the tract.

The standard technique for removal of thyroglossal cyst is the classical Sistrunk operation. (8). It reduces the recurrent rate down to 5% in compare to simple excision where recurrent rate is reported as high as 50%.

### **SUMMARY**

We report the first case of adult patient presents with concurrent branchial sinus and thyroglossal duct cyst. Branchial cleft and thyroglossal duct tract related problems are one of the most common causes of neck lump and

fistulae individually. However, both conditions occurring in the same patient simultaneously, like in our case, is tremendously rare and not reported previously to our knowledge. This report shows that there is a possibility that more than one anomaly can be seen in same patient simultaneously, so that we should always keep in mind and look for a possible associated or concurrent lesion. Standard investigation like sinograms or fistulograms should be performed to rule out the extent and nature of the tract before exploration. Again, expert opinions and handling from specialist for proper exposure and exploration of the tract are also required to excise all the pathology inside which will evidently reduce the recurrences.

### **ACKNOWLEDGEMENTS**

We thank all the staffs from major operation theatre and specialist clinic; Hospital Pakar Sultanah Fatimah, help to get all necessary things required in this paper and special thanks to research committee; Melaka Manipal Medical College, to give research paper writing training and encourage getting this publication.

### **References**

1. Acierno SP, Waldhausen JH. Congenital cervical cysts, sinuses and fistulae. *Otolaryngol Clin North Am*. Feb 2007;40(1):161-76.
2. An incidence study on thyroglossal duct cysts in adults; Kurt A et al. *Saudi Med J*. 2007 Apr;28(4):593-597
3. Anand TS, Anand CS, et al. Seven cases of branchial cyst and sinuses in four generation. *Hum Hered*. 1979;29(4):213 – 6.
4. Abhishek J et.al. Simultaneous complete branchial and thyroglossal fistula – a rare presentation. *Indian J Otolaryngol. Head Neck Surg*. (January – March 2008)60:94 – 96.
5. Androulakis M, Johnson JT et.al. Thyroglossal duct and second branchial cleft abnormalities in adults. *Ear Nose Thorad J*. 1990;(9); 318 -322.
6. Allard RH. The thyroglossal cyst. *Head Neck Surg*. Nov – Dec 1982;5(2): 134 – 46.
7. Myers EN (1997) Branchial cleft cysts and sinuses. In: Myers EN, ed. *Operative Otolaryngology: Head and Neck surgery*. Philadelphia, Pa: Saunders;638 – 647.
8. Sistrunk WE. The Surgical Treatment of Cysts of the Thyroglossal Tract. *Ann Surg*. Feb 1920;71(2):121 -122.

**Author Information**

**Myo Kyi, MMedSc(Surg)(Institute of Medicine 1, Yangon)**

Surgical Specialist, Department of Surgery, Hospital Pakar Sultanah Fatimah

**Thant Zin, FRCSE(Royal College of Surgeons of Edinburgh)**

Associate Professor, Department of Surgery, Melaka Manipal Medical College

**Myat Maw, MRCS (Ireland)**

Associate Professor, Department of Surgery, Melaka Manipal Medical College

**Rosaini Binti Paijan, Master(Surgery)(USM).**

Consultant Surgeon, Department of Surgery, Hospital Pakar Sultanah Fatimah

**Mohamed Khir Abdullah, MS (ORL)(UKM).**

Consultant Surgeon, Department of ENT, Hospital Pakar Sultanah Fatimah

**Noorafidah MD Din, MPATH(UM).**

Pathologist, Department of Pathology, Hospital Pakar Sultanah Fatimah