

Laparoscopic Repair of Subcostal Hernia

J McClenathan

Citation

J McClenathan. *Laparoscopic Repair of Subcostal Hernia*. The Internet Journal of Surgery. 2012 Volume 28 Number 2.

Abstract

The repair of an abdominal subcostal hernia is presented. Diagnosis was confirmed by CT scan and repair was accomplished laparoscopically.

PURPOSE

The author describes the presentation and management of a patient with subcostal hernia. There is no reference to adult subcostal hernia in PUBMED. Therefore, we wish to bring it to attention of readers and show that the laparoscopic repair is suitable for this condition.

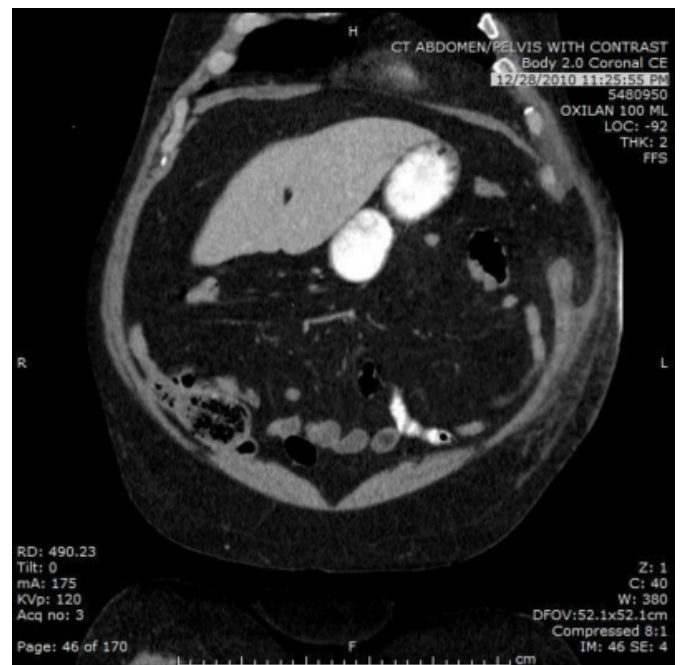
CASE REPORT

A 69-year-old man was referred for evaluation of a left sided abdominal wall mass. The mass was first noted after a neurosurgical procedure for a lumbar arachnoid cyst. The mass was described as the size of a fist and was just below the left lateral costal margin. There were no gastrointestinal symptoms. The patient denied previous abdominal surgical procedures and there were no scars. He also denied previous trauma.

Physical exam confirmed the hernia in the left subcostal area. A CT scan showed a left lateral subcostal hernia in the location described by the patient (Figure 1).

Figure 1

Figure 1: CT scan demonstrates mushroom-shaped left subcostal hernia



At operation, three laparoscopic ports were placed. The incarcerated omentum was reduced from a 6-cm defect below the ribs on the left. A mesh repair was completed. The mesh was secured with four corner sutures and a tacking device. The repair was secure at a three month postoperative visit.

DISCUSSION

Laparoscopic techniques are used with increasing frequency for repair of abdominal wall hernias. Prior to operation on this patient, a search of PUBMED for “subcostal hernia” did not reveal any previous cases in adults. The etiology of this unusual hernia in our patient is uncertain. He did not recall

any major trauma and he did not have a surgical procedure at the site of the hernia.

Based on the success of this repair, we recommend laparoscopic mesh repair for subcostal hernia.

References

Author Information

James H. McClenathan

Associate Professor of Clinical Surgery, University of Arizona Healthcare South Campus