

Insulinoma Masquerading As Status Epilepticus

P A Shah, H A Malik, H M Bhat, J A Basu

Citation

P A Shah, H A Malik, H M Bhat, J A Basu. *Insulinoma Masquerading As Status Epilepticus*. The Internet Journal of Neurology. 2013 Volume 16 Number 1.

Abstract

ABSTRACT

Insulinoma is a very rare endocrine disorder. 80% of insulinomas result from benign simple adenomas of pancreas and hypoglycemia is the commonest presenting feature. Although seizures as a consequence of insulinoma are well known, yet status epilepticus as the initial presenting feature is a rarity. Here, we report a young female in whom insulinoma masqueraded as status epilepticus.

INTRODUCTION

Insulinoma, the most common cause of endogenous hypoglycemia is rare in adults. Insulinoma is a neuro-endocrine tumor derived mainly from pancreatic beta-cells which secrete insulin in addition to other hormones. The symptoms of insulinoma are mainly due to hypoglycemia and about 30% of patients are initially erroneously diagnosed as seizure disorder.¹

The diagnosis of insulinoma is established by the demonstration of fasting hypoglycemia ($< 50\text{mg/dl}$), inappropriate plasma insulin levels ($> 6\text{microu/ml}$) and C-peptide levels ($> 0.25\text{nmol/l}$).²

Seizures tend to be more common in children but permanent neurologic sequelae have been observed in about 7% adults.³

CASE SUMMARY

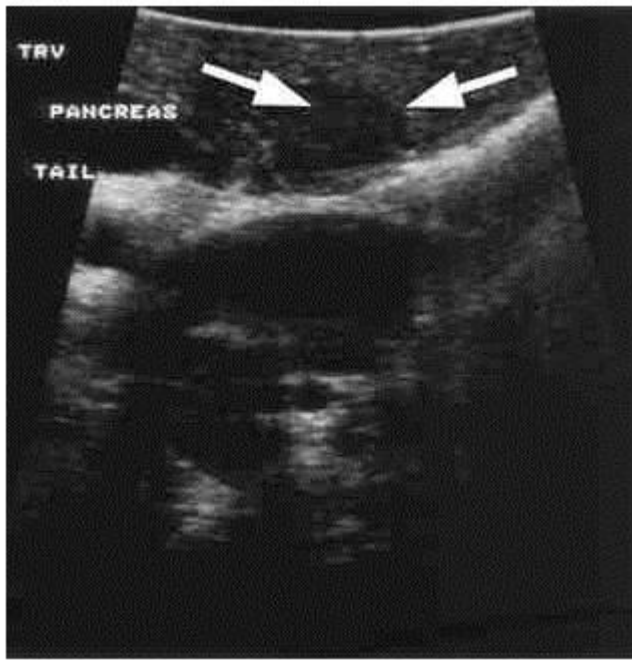
A 35 year old female, presented with 6 months history of episodic lapses in consciousness associated with incoherent speech, confusion, sweating and palpitations. The patient had been getting such episodes of unconscious spells recurrently once or twice a week. She was initially managed as anxiety disorder with no relief in her symptomatology. Moreover, three days prior to hospitalization, patient had been getting recurrent episodes of unconscious spells, accompanied by abnormal body movements, uprolling of eyeballs, tongue bite and incontinence of urine. There was no history of head trauma or complaints pertaining to any other system involvement. Past medical history too was

unremarkable except for selective serotonin receptor uptake inhibitors and benzodiazepine intake during last six months, there was no other drug intake prior to the onset of present symptomatology.

On admission, patient was stuporose with a GCS of 8/15 with bilateral extensor plantar responses. The rest of the general physical and systemic examination was unremarkable. Except for plasma glucose level of 28mg/dl , her routine serum chemistry including serum electrolytes was unrewarding. During hospital stay, patient was getting recurrent episodes of generalized tonic-clonic seizures with blood glucose levels fluctuating between $28\text{--}35\text{mg/dl}$ during. Her plasma insulin and C-peptide levels were 10.9iu/l and 30ng/dl respectively. Plasma insulin and C-peptide levels were inappropriate for her blood glucose level of 30mg/dl and USG abdomen revealed a hypoechoic mass in pancreas measuring $16.9 \times 13.1\text{mm}$. Her ECG, echocardiography, 24 hour Holter monitoring, CT head(plain) and MRI abdomen were unremarkable. Electroencephalography during the interictal period revealed background slowing. With aforementioned clinical and laboratory parameters, a diagnosis of insulinoma masquerading as status epilepticus was entertained. After phenytoin infusion, the patient received diazoxide. After detailed endocrinological evaluation, she underwent surgical extirpation of the pancreatic tumour. Histopathological examination of the tumour was corroborative.

Figure 1

Abdominal ultrasonograph revealing Pancreatic mass



DISCUSSION

Insulinoma is a neuro-endocrine tumor derived mainly from pancreatic β -islet cells which apart from insulin, secretes gastrin, chorionic gonadotropin, corticotrophin, serotonin, somatostatin, glucagon and pancreatic polypeptide. The estimated incidence of insulinoma is one case per 2,50,000 patients years.⁴ Insulinoma can be sporadic or familial or a component of the MEN1 (multiple endocrine neoplasia) syndrome. Insulinoma has a female preponderance with a 5% rate of malignancy.⁴

About 8% of insulinoma patients are diagnosed with multiple endocrine neoplasia type I (MEN1), a syndrome characterized by simultaneous or successive cellular proliferation in at least two endocrine organs. The more commonly affected endocrine organs include the pancreas, parathyroid and pituitary.⁵ MEN1 patients present at a younger age (median age of 25 years).¹

In insulinoma there is dysregulated insulin release which leads to hypoglycemia. Normally increased insulin levels and hypoglycemia perse suppress insulin release.⁶ In insulinoma, suppression of insulin release by insulin and hypoglycemia is erratic and not appropriately suppressed by hypoglycemia.

Clinical features of of insulinoma vary widely and are mainly due to hypoglycemia and rarely due to mass effect. Insulinomas, however, are primarily associated with

neuroglycopenic symptoms, and occasionally sympatho-adrenal autonomic symptoms. Neuro-glycopenic symptoms include dizziness, amnesia, confusion, personality and behavioural changes, diplopia, seizures, and in some cases stroke and coma.⁷ 20%-60% of insulinoma patients are initially misdiagnosed with neurological disorders of which 30% are diagnosed with seizure disorders.^{1,7} Except in late diagnosed malignant cases in which an abdominal mass and signs of metastasis may be present, physical examination is usually normal.

Insulinoma can be diagnosed by demonstration of fasting hypoglycemia ($< 50\text{mg/dl}$), inappropriate plasma insulin and C-peptide levels ($> 0.25\text{ng/ml}$). The gold standard is the classic 72 hour fasting test. Hypoglycemia develops in essentially all insulinoma patients during this test, infact 75% will become symptomatic within 24 hours 8 99% of insulinoma's occur in pancreas with equal frequency in head, body and tail. Other rare sites are duodenal wall and gastrosplenic omentum. CT scan and MRI of abdomen localize tumour in 50-70% cases. Real-time transabdominal high resolution ultrasonography has a 50% sensitivity, celiac arteriography and transsplenic portal venous sampling are invasive and probably not needed. ⁹ Currently preoperative transabdominal ultrasonography followed by intraoperative ultrasonography is considered the most specific and sensitive approach which can detect more than 95% of tumors.¹⁰ Surgery is the treatment of choice for insulinoma.¹¹ Diazoxide given preoperatively reduces the need for glucose supplementation and risk of hypoglycemia. In MEN1, hypercalcemia must be corrected initially by parathyroidectomy followed by tumour resection. Nonsurgical management is contemplated for recurrent and inoperable tumors.

Diazoxide (3-5mg/kg/day per oral 8 hourly)inhibits insulin release from insulinoma, is most commonly used. Phenytoin and Calcium Channel blockers are less commonly used. Octreotide 200-300 $\mu\text{g/day}$ I.V. or subcutaneous bid or qid and continuous glucagon infusion too are used in selected cases. Hepatic artery embolization, chemo-embolization and chemotherapy with streptozocin and floro-uracil may be considered for malignant tumors

CONCLUSION

To conclude, insulinoma resulting in hypoglycemia induced seizures should be considered in a patient of late-onset status epilepticus or refractory epilepsy especially with normal neuroimaging. It is pertinent to mention here, that seizures in such cases cannot be adequately controlled unless underlying pancreatic tumor and hypoglycemia is taken care

of.

References

1. Boden G. Glucagonomas and insulinomas. *Gastroenterology Clinics of North America* 18: 831: 1989.
2. Service F. Hypoglycemic disorder. *N Eng J Med* 1995; 332: 1144-1152.
3. Stefanini P, Carboni M, Patrassi N et al. Beta-islet cell tumors of the pancreas: Results of study on 1,067 cases. *Surgery* 1974; 75: 597-609.
4. Service FJ, McMohan, O'Brein PC et al. Functioning insulinoma, incidence, recurrence and longtime survival of patients. *Mayo Clinic Proc* 1991; 66: 711-719
5. Mansour JC, Chen H. Pancreatic Endocrine Tumor. *Journal of Surgical Research* 2003;120:139-61
6. Geric J, Charles M, Goadsky G :Regulation of pancreatic insulin and glucagon secretion. *Annu Rev Physiol* 1976;38:353-388
7. Dizon AM, Kowalyk S, Hoogwerf BJ. Neuroglycopenic and other symptoms in patients with insulinomas. *American Journal of Medicine* 1999; 106: 307.
8. Scholz D, Remine W, Priestley J; Hyperinsulinism. Review of 95 cases of functioning pancreatic islet cell tumours. *Mayo clin proc* 1960 ;35:545-550
9. Fajans S, Vinik A. Insulin producing islet cell tumors. *Endocrinol Metab Clin North Am* 1989; 18: 45-74.
10. Boukhman M, Karam J, Shaver J et al. Insulin: Experience from 1950 to 1995. *West J Med* 1998; 169: 98-104.
11. Witteles RM, Straus Fu ii, Sugg SL et al. Adult onset nesidioblastosis causing hypoglycemia. An important clinical entity and continuing treatment delima. *Arch Surg* 2001; 136: 656-663.
12. Gill G, Raufo, Macfarlane I. Diazoxide treatment for insulinoma. A national UK survey. *Postgrad Med J* 1997; 73: 640-641.

Author Information

Parvaiz A Shah, M.D, D.M, Professor & Consultant Neurologist

Postgraduate Department of Medicine (Neurology Division), Govt. Medical College & Associated S.M.H.S. Hospital
Srinagar, Kashmir. INDIA
parvaizshah11@rediffmail.com

Hameed A. Malik, MD, Registrar

Postgraduate Department of Medicine (Neurology Division), Govt. Medical College & Associated S.M.H.S. Hospital
Srinagar, Kashmir. INDIA

Hayat M Bhat, M.D.D.M, Lecturer (Endocrinologist)

Postgraduate Department of Medicine (Neurology Division), Govt. Medical College & Associated S.M.H.S. Hospital
Srinagar, Kashmir. INDIA

Javaid A Basu, Lecturer

Postgraduate Department of Medicine (Neurology Division), Govt. Medical College & Associated S.M.H.S. Hospital
Srinagar, Kashmir. INDIA