

Acute Reversible Hearing Loss In Scrub Typhus

K Soni, S Chhabra, S Yadav, J Gulia

Citation

K Soni, S Chhabra, S Yadav, J Gulia. *Acute Reversible Hearing Loss In Scrub Typhus*. The Internet Journal of Otorhinolaryngology. 2012 Volume 14 Number 1.

Abstract

Scrub typhus is a febrile illness caused by *Rickettsia tsutsugamushi*, a bacteria that belongs to the family Rickettsiaceae. This disease is endemic in certain regions of India. A case of scrub typhus presenting with acute sensorineural hearing loss which resolved with treatment is being reported. Hearing impairment with fever in a patient in endemic region of scrub typhus can give a clue to health care worker towards the diagnosis of scrub typhus and thus early administration of treatment.

INTRODUCTION

Scrub typhus, an infectious disease, is transmitted to humans from field mice and rats through the bite of mites. The main symptoms of the disease are fever, a wound at the site of the bite, spotted rash on the trunk, and swelling of the lymph glands. Scrub typhus is caused by *Rickettsia tsutsugamushi*, a tiny parasite about the size of bacteria that belongs to the family Rickettsiaceae. They are intracellular parasites, as they can live only within the cells of other animals.

R. tsutsugamushi lives primarily in mites that belong to the species *Leptotrombidium* (*Trombicula*) *akamushi* and *Leptotrombidium deliense*. The tiny chiggers (mite larvae) attach themselves to the skin. During the process of obtaining a meal, they may either acquire the infection from the host or transmit the rickettsiae to other mammals or humans. In regions where scrub typhus is a constant threat, a natural cycle of *R. tsutsugamushi* transmission occurs between mite larvae and small mammals (field mice and rats). Humans enter the cycle of rickettsial infection only accidentally.

The seasonal occurrence of scrub typhus varies with the climate in different countries. It occurs more frequently during the rainy season. Certain areas such as forest clearings, riverbanks, and grassy regions provide optimal conditions for the infected mites to thrive. These small geographic regions are high-risk areas for humans and have been called scrub-typhus islands. More than 1 billion people living in the area of endemicity and travelers are at risk from scrub typhus^[1-4]. Approximately 48%-82% of individuals develop an eschar^[5] at the site of the bite of the vector, the larvae of *Leptotrombidium* species mites (chiggers). The

patient's fever rises during the first week, generally reaching 40-40.5 degree Celsius. The disease is re-emerging in Southeast Asian countries. Limited serological surveys have clearly shown that scrub typhus is quite prevalent in India^[6]. The literature mentions this disease in hilly regions of the Himalaya but specific data are not available. The disease must have been prevalent in the area but was not noticed because, in the past, most cases of fever were treated with drugs like tetracycline and chloramphenicol, which effectively treat scrub typhus also^[7].

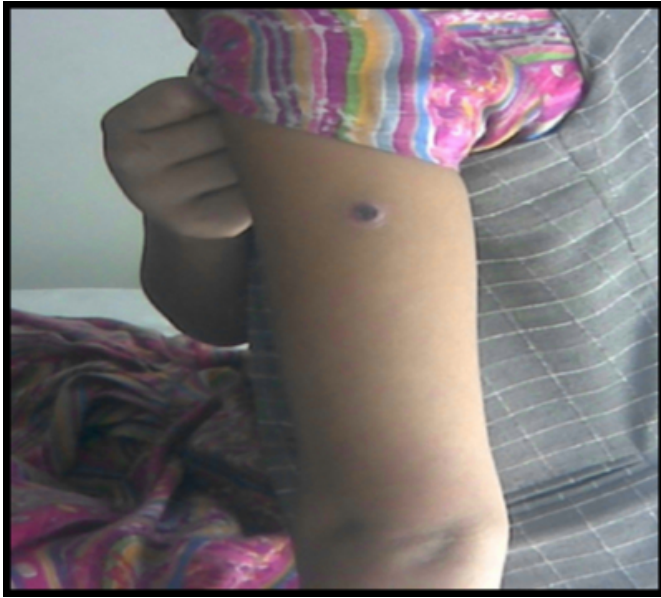Association between hearing loss and scrub typhus is known to exist. In a study from Sri Lanka sensorineural hearing loss was reported in 19% of patients with scrub typhus^[8] and can affect up to one third of the patients^[9]. We are reporting a case of 17 year old female who presented with fever, rash and impairment of hearing with serological diagnosis of scrub typhus.

CASE REPORT

A 17 year old female was admitted in medicine department of Indira Gandhi Medical College, Shimla, India with history of fever associated with cough and chest pain of 10 days duration. The patient was from countryside who usually works in fields. The patient noticed impairment of hearing in both ears 1 week after the onset of fever which was progressive. On admission, she was in an acute distressed state with body temperature 39°C, pulse rate 108 beats/min, respiratory rate 24/min and blood pressure 110/84 mm Hg. There was a well formed eschar over the left arm. (Figure 1)

Figure 1

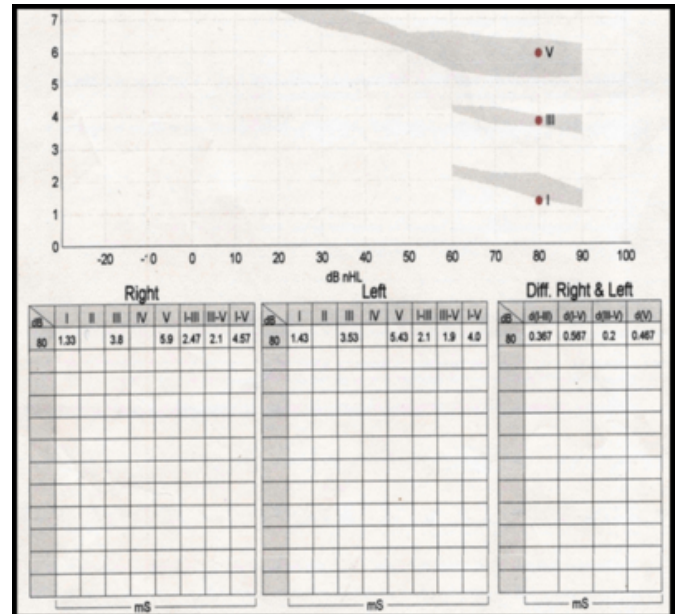
Figure 1: showing a well formed eschar over the left arm.



There was vesicular breath sound on auscultation of chest with air entry decreased on right side. Cardiovascular system and GIT examination was normal. Central nervous system examination was normal except for hearing impairment. On ear examination bilateral tympanic membrane were normal. Hematologic tests revealed hemoglobin, 11g/dl; WBC, 8800/mm³ and platelets, 1.8 lakh/mm³. Differential leucocytes count showed neutrophilia. Weil Felix test showed antibody titer against OX K >320. Elisa was positive for scrub typhus antigen. Blood test for typhoid, malaria, and dengue were negative. Renal function tests, liver function tests and serum electrolytes were normal. Chest x-ray showed right lower lung homogenous opacity. Rinne's test was positive in both ear in 256, 512, 1024 Hz frequencies respectively and Weber's test was not lateralized. On pure tone audiometry examination there was bilateral moderately severe sensorineural hearing loss. The hearing threshold level in left ear is 48dB and 52 dB in right ear for air as well as bone conduction. On brainstem evoked response audiometry there was significant prolongation of wave III and wave V latency and inter-peak latency of wave I-III and wave I-V (fig 2). Patient was treated with doxycycline and on follow up after 2 months patient hearing was almost normal. Only puretone audiometry examination was done which showed normal hearing threshold in speech frequencies with hearing loss persistent in higher frequencies.

Figure 2

Figure 2: Showing prolongation of wave III and wave V latency and inter-peak latency of wave I-III and wave I-V



DISCUSSION

Although the association of hearing loss and scrub typhus is not unknown, however very few cases of scrub typhus associated with hearing impairment are reported in literature.

BERA results in our patient showed a significant prolongation of absolute wave latencies of wave III & V and inter-peak latency of wave I-III and wave I-V suggesting probable site of lesion to be the cochlea and auditory nerve. The well-known pathology of scrub typhus is vasculitis, which is caused by the destruction of endothelial cells with accompanying perivascular infiltration of leukocytes and endothelial proliferation, followed by thrombosis or closure of the lumen by endothelial proliferation and swelling^[10].

Although the mechanism of hearing loss in scrub typhus has not yet been fully elucidated, at least two mechanisms have been proposed. In the first, the rickettsiae directly invade the central nervous system and induce vasculitis in the acute stage and damage the cochlear division of the eighth cranial nerve. In the second, vasculitis is produced in the vasa vasorum of the cochlear nerve by a secondary immune mechanism^[11-13]. Merei described early sensorineural hearing loss occurred in 60 – 65 percent of the cases^[14]. Friedmann et al described the characteristic histopathological features in scrub typhus. The VIIIth nerve showed multiple typhus nodules and there was extensive interstitial neuritis of the VIIIth nerve and demyelination of the nerve fibers^[15]. Kang et al^[16], Mahajan et al^[13], Premratna et al^[18] reported patients

with scrub typhus with acute sensorineural hearing loss. The acute hearing loss resolved after antibiotic therapy. In present case also reversible type of sensorineural hearing loss was observed.

Incidence of scrub typhus was more in females because they more commonly worked in the fields. Park et al observed in their study that in an outbreak in Korea, females were more commonly infected, i.e., the ratio of females to males was 3.4:1. This was also observed in present case^[17].

CONCLUSION

Hearing impairment with fever in a patient in endemic region of scrub typhus can give a clue to health care worker towards the diagnosis of scrub typhus and thus early administration of treatment. This is particularly important in country like India where the adequate diagnostic facilities are still lacking.

References

1. Rosenberg R. Drug-resistant scrub typhus—paradigm and paradox. *Parasitol Today* 1997; 13: 131–2.
2. Silpapojakul K. Scrub typhus in the Western Pacific region. *Ann Acad Med Singapore* 1997; 26: 794–800.
3. Watt G, Strickman D. Life-threatening scrub typhus in a traveler returning from Thailand. *Clin Infect Dis* 1994; 18: 624–6.
4. Watt G, Chouriyagune C, Ruangweerayud R, Watcharapichat P, Phulsuksombati D, Jongsakul K et al. Scrub typhus infections poorly responsive to antibiotics in northern Thailand. *Lancet* 1996; 348: 86–9.
5. Gormley TS. A diagnosis of scrub typhus. *Navy Med* 1996; 87: 20–2.
6. Directorate General of Health Services, Government of India. Manual of Zoonoses. Editors - Sehgal S, Bhatia R. National Institute of Communicable Diseases, New Delhi. 1985: 1-98.
7. Sharma A, Mahajan S, Gupta ML, Kanga A, Sharma V. Investigation of an outbreak of scrub typhus in Himalayan region of India. *Jpn J Infect Dis* 2005; 58: 208–10.
8. Premaratna R, Chandrasena TG, Dassayake AS, Loftis AD, Dasch GA, De Silva HJ. Acute hearing loss due to scrub typhus: a forgotten complication of reemerging disease. *Clin Infect Dis* 2006; 42: 1505–6.
9. Watt G. Scrub typhus. In: Warrell DA, Cox TM, Firth JD, Benz EJ Jr, editors. *Oxford text book of medicine*. 4th ed. London: Oxford University Press; 2003. p. 629–31.
10. Settle EB, Pinkerton H, Corbett AJ. A pathologic study of tsutsugamushi disease with notes on clinicopathologic correlation. *J Lab Clin Med* 1945; 30: 639–61.
11. Dolan S, Everett ED, Renner L. Hearing loss in Rocky Mountain spotted fever. *Ann Intern Med* 1986, 104: 285.
12. Walker DH, Parks FM, Betz TG, Taylor JP, Muehlberger JW. Histopathology and immunohistologic demonstration of the distribution of *Rickettsia typhi* in fatal murine typhus. *Am J Clin Pathol* 1989, 91: 720–4.
13. Mahajan SK, Bakshi D. Acute reversible hearing loss in scrub typhus. *J Assoc Physicians India* 2007, 55: 512–4.
14. Merei J. Diseases of the ear due to louse borne typhus (experience with 800 cases of typhus). *Acta Otolaryngologica (Stockholm)* 1946; 34: 572–5.
15. Friedmann I, Frohlich A, Wright A. Epidemic typhus fever and hearing loss": A histological study (Hallpike collection of temporal bone sections). *Journal of laryngol Otol* 1993; 107: 275–83.
16. Kang JI, Kim DM, Lee J. Acute sensorineural hearing loss and severe otalgia due to scrub typhus. *BMC Infectious Diseases* 2009 Oct 22; 9: 173.
17. Park JI, Han SH, Cho SC, Jo YH, Hong SM, Lee HH et al. Outbreak of hepatitis by *orientia tsutsugamushi* in the early years of the new millennium. *Korean J Hepatol* 2003; 9: 198–208.

Author Information

Kapil Soni, M.S

Senior Resident, Department of Otolaryngology, Pt. B.D Sharma University of Health Sciences Rohtak

S Chhabra, M.D, DNB

Assistant Professor, Department of Anesthesiology, Pt. B.D Sharma University of Health Sciences Rohtak

S P S Yadav, M.S, MNAMS, FAMS

Senior Professor, Department of Otolaryngology, Pt. B.D Sharma University of Health Sciences Rohtak

J S Gulia, M.S

Professor, Department of Otolaryngology, Pt. B.D Sharma University of Health Sciences Rohtak