

An Unusual Foreign Body In Upper Lip

S Yallamraju, S Gunupati

Citation

S Yallamraju, S Gunupati. *An Unusual Foreign Body In Upper Lip*. The Internet Journal of Dental Science. 2012 Volume 10 Number 2.

Abstract

Granuloma formation is a specific type of chronic inflammation characterized by accumulation of modified macrophages and initiated by infectious and noninfectious agents. They are uncommon and usually a sequel of accidents. It is important and interesting to know the reaction they evoke. Many times they have been overlooked and are the prime reason for morbidity. Trauma from accidents and bullet wounds are a common cause. Reports of glass, plastic, fish bone and wooden pieces have all been reported but in few numbers. We are reporting a case with a 12 year history of an embedded metal piece in the upper labial mucosa which evoked peripheral granuloma formation.

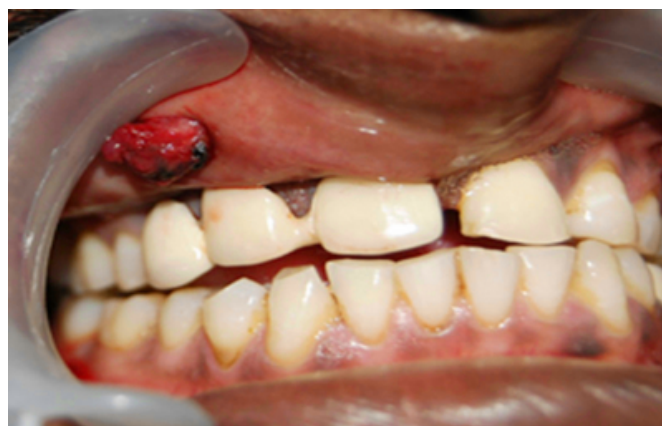CASE REPORT

A 36-year-old male patient presented to the dental outpatient department (OPD) with a chief complaint, to replace his existing prosthesis. The patient was in sound medical health with no relevant medical history of concern. He had no known allergies. The dental history revealed he had undergone extractions, restorations and prosthesis insertion previously with no reported complications, further history revealed he suffered a misfire injury of a hand grenade 12 years ago, he sustained soft tissue injuries to the face and there were no hard tissue injuries, following which he was hospitalized and treated for the same.

Intra oral examination revealed a single solitary growth with an erythematous surface and an area of grayish black hue towards the proximal end, roughly ovoid in shape measuring about 2*1.5 cm's in diameter. (Figure 1)

Figure 1

Figure 1: Intra-oral view showing foreign body with tissue attached on the upper lip

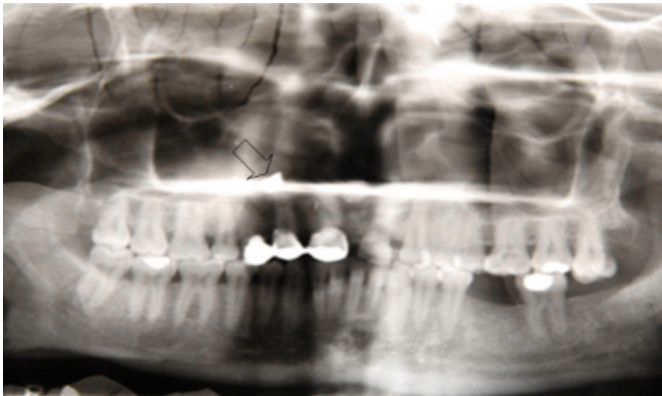


Palpation confirmed the inspector findings and the growth was solitary, mobile and nodular, also a hard mass was palpable within the growth. The cervical lymph nodes were not palpable.

The case was investigated with an Orthopantomogram (OPG) which revealed a radiopaque rectangular shadow superimposed with the shadow of the hard palate on the right side. (Figure 2)

Figure 2

Figure 2: Orthopantomogram showing tear drop shaped radiolucent area at apices of the maxillary right lateral incisor, which is shown by an arrow mark.



The area in relation to swelling was locally anesthetized. A combination of vertical and releasing incisions were placed and the metal piece was removed from the surgical site along with granulation tissue. The area was curetted and the surgical wound was sutured with 3-0 surgical silk. The excised specimen was submitted for histopathology examination. (Figure 3&4),

Figure 3

Figure 3: photograph showing the excised metal piece with the tissue attached.

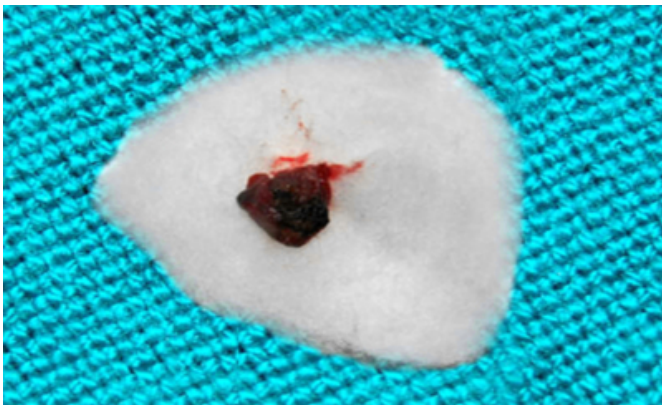



Figure 4

Figure 4: Removed Metal piece from upper lip.



He was prescribed antibiotics Amoxicillin 500mg t.i.d., Metronidazole 200mg q.i.d. and analgesic Ibuprofen 400 mg t.i.d. for 1 week and reviewed, there were no complications.

The excised specimen reported as foreign body granuloma. The Hematoxylin and Eosin stained sections reveal stratified squamous parakeratinized epithelium overlying a fibrous connective tissue consisting of densely arranged collagen fibers and inflammatory cell infiltrate with areas of hyalinization is seen (Figure 5).

Figure 5

Figure 5: Hematoxylin and eosin (H&E), X100 stained sections reveal stratified squamous parakeratinized epithelium overlying a fibrous connective tissue consisting of densely arranged collagen fibers and inflammatory cell infiltrate.

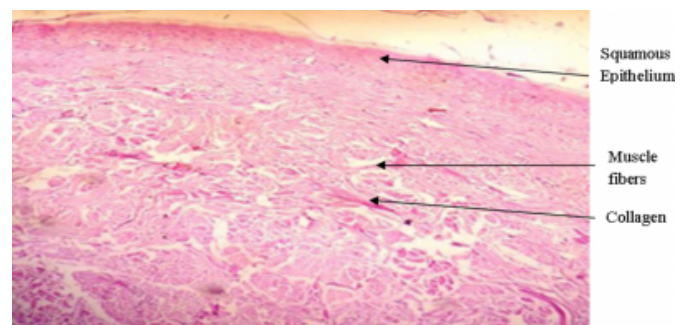
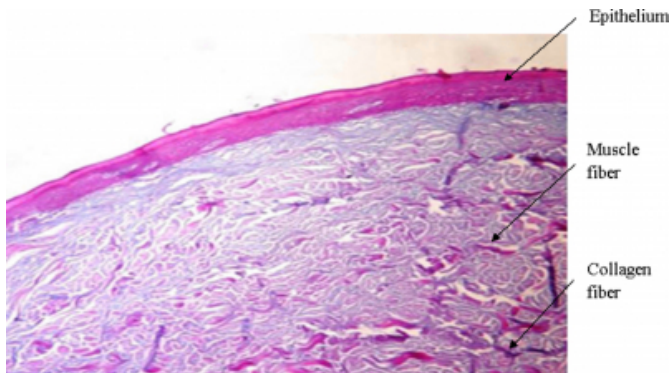


Figure 6

Figure 6: Special stain: Masson's trichrome was used for demonstration of muscle, collagen fibers which appeared pink and blue.



DISCUSSION

Clinical evaluations and diagnosis of foreign body reactions pose a challenge as they depend on the type of foreign body involved, the duration of its presence, symptoms associated and the clinical picture.

A careful evaluation of the radiographs is essential as the foreign bodies have different radiodensities, sizes and shapes. Their appearance is influenced by a number of factors which include its power to attenuate the x-ray beam which determine its radiodensity, superimposition of these objects with the anatomic hard tissue structures and the exposure parameters.¹⁰

Any materialistic substance which is not naïve to the human body is a foreign object and will evoke an immune response as a foreign body reaction resulting in a granuloma formation. There are circumstances in which the substances that provoke the acute inflammatory reaction are particulate and larger than the phagocytes and could not be digested by the reacting neutrophils causing a response namely granulomatous inflammation. The macrophages are the basic structural unit of chronic inflammation. After amassing substances that they cannot digest macrophages develop into epithelioid cells.¹¹

Imaging the maxillofacial region with Orthopantomograph was challenging as the metal piece appeared radiopaque and its position was in plane with the shadow of the hard palate. A careful evaluation of the radiodensity and the deviation of the normal anatomic structure of the hard palate on the right side were evaluated to locate the foreign body, however an IOPA of the lip would have been more informative and evaluative.

Hannon et al reported a silica granuloma of the lip.¹² Odell et al reported a foreign body giant cell reaction elicited by a haemostatic alginate.¹³ Owens et al published a study showing oral amalgam tattoos accounted for almost 1% of approximately 19000 pathology reports on file.¹⁴ Ding et al reported foreign body granuloma in the sub mental region due to fish bone,¹¹ however foreign body reactions and granuloma formation resulting due to an accidental explosion of hand grenade and a metal piece being lodged in the labial mucosa which was left undetected for 12 years is being reported for the first time.

Although foreign body reactions are commonly associated with trauma related events, it is important to investigate and evaluate them with utmost care. A proper history, clinical evaluation and the appropriate investigation will help us in diagnosis and treatment of these conditions with accuracy.

ACKNOWLEDGMENTS

I acknowledge Dr. R.C. Jagath Reddy M. D.S Department of Oral Medicine and Radiology, K.D Dental College and Hospital, Mathura, Uttar Pradesh, India

References

1. Feldman RP, Marcovici A, Suarez M, Goodrich JT. Foreign body granuloma mimicking intracranial meningioma: case report and review of literature. *Neurosurgery* 1999; 44:85-88.
2. Hunter TB, Taliyanovic MS. Foreign Bodies. *Radiographics* 2003; 23:731-757.
3. Holmstrup P. Non-plaque-induced gingival lesions. *Ann Periodontol* 1999; 4:20-29.
4. Mohanavalli S, Jasline david J, Gnanam J. Rare foreign bodies in oro-facial regions. *Indian J Dent Res* 2011; 22:713-55
5. Shehata E, Moussa K, Al-Gorashi A. A foreign body in the floor of the mouth. *The Saudi Dental Journal* (2010) 22, 141-143.
6. Anderson MA, Newmeyer WL, Kilgore Es. Diagnosis and treatment of retained foreign bodies in hand. *Am J Surg* 1982; 144:63-67.
7. Becker T and Neronov A. Orthodontic Elastic Separator-Induced Periodontal Abscess: A Case Report. *Case Reports in Dentistry* 2012; Article ID 463903, 3 pages.
8. Boyse TD, Fessell DP, Jacobson JA, Lin J, Holsbeeck MTV, Haynes CW. US of soft-tissue foreign bodies and associated complications with surgical correlation. *Radiographics* 2001; 21:1251-1256.
9. Sumanth KN, Boaz K, Shetty NY. Glass embedded in the labial mucosa for 20 years. *Indian J Dent Res*. 2008; 19(2):160-161.
10. Mahale AR, Shetty R, Venugopal A, Kumar A. radiological detection of unsuspected foreign bodies-letter to editor. *Indian J Radiol Imaging* 2002; 12:134
11. Ding X, Zhu XH, Fang YM, Zhang L. Foreign body granuloma in the submental region due to fish bone: a case report. *Oral Surgery* 2010; 3:43-46.
12. Hannon SM, Pickett AB, Frost JM. Foreign-body (silica) granuloma of the lip. *J Oral Maxillofac Surg*.

1983;41:470-472

13. Odell EW, Oades P, Lombardi T. Symptomatic foreign body reaction to haemostatic alginate. Br J Oral Maxillofac Surg.1994;32:178-179

14. Silveira VAS, Carmo EDD, Colombo CED, Cavalcante ASR, Carvalho YR. Intraosseous foreign-body granuloma in the mandible subsequent to a 20-year-old work-related accident. Med Oral Patol Oral Cir Bucal 2008; 13(10):657-660.

Author Information

Surya Narayana Yallamraju, M.D.S.

Department of Periodontology, Institute of Dental Sciences

Sumanth Gunupati, M.D.S

Department of Periodontology, Sri Sai College of Dental Surgery