

Comparison of Femoral Rotation in Total Knee Arthroplasty with Measured Resection Technique and Balanced Flexion Gap Technique

M Ahmed, J Scarvell, M Alfredson, T Ward, P Smith

Citation

M Ahmed, J Scarvell, M Alfredson, T Ward, P Smith. *Comparison of Femoral Rotation in Total Knee Arthroplasty with Measured Resection Technique and Balanced Flexion Gap Technique*. The Internet Journal of Orthopedic Surgery. 2012 Volume 19 Number 2.

Abstract

Purpose:

Avoiding femoral malrotation has always been a technical challenge for orthopaedic surgeons in total knee arthroplasty. While modern surgical techniques have made the surgeon's task easier, nevertheless it remains unclear which of the two most common techniques- the measured resection or balanced flexion gap techniques- more accurately restores femoral component rotation. This study aimed to compare the femoral rotation produced by these two surgical techniques and the relationship between the femoral rotation and coronal tibial alignments. This retrospective cohort study compared 20 posterior stabilized Anatomic Modular Knee (AMK), aligned using a measured resection technique to 20 mobile bearing Low Contact Stress knee (LCS) aligned using a balanced flexion gap referencing system. Long leg standing x-rays and CT scans of knees were used to measure rotation of the femoral component in the axial plane and tibial alignment in the coronal plane.

Results:

Average femoral component rotations were 2.98 (SD 3.21) degrees and 2.26 (SD 1.20) degrees for the AMK and LCS, respectively. Tibial component alignments were 0.66 (SD 1.94) degrees valgus and 0.4 (SD 1.09) degrees valgus for the AMK and LCS, respectively. These differences were not statistically significant.

Conclusion:

There were no statistically significant differences in femoral rotation between the two referencing systems. However, the balanced flexion gap method had a narrower range of implant rotational position. No statistically significant relationship was found between femoral rotation and tibial alignment in either system.

INTRODUCTION

Total Knee Arthroplasty (TKA) is the most common type of arthroplasty performed with 40,675 TKA's performed in Australia in 2009^[1]. The overall satisfaction from TKA procedures irrespective of type and technique is about 95%^[2]. Advancements in TKA technology have enhanced the design and fit of knee implants resulting in improved short and long term outcomes^[3]. Nevertheless, one of the complications of a TKA is malrotation of the prosthesis^[4]. In particular, appropriate axial alignment of the femoral component is challenging, as it requires adequate knowledge of anatomy as well as expertise in the surgical technique. The importance of femoral rotation can be gauged by the fact that discrepancies can lead to patello-femoral mal-tracking^[5], arthrofibrosis^[6], flexion instability^[7], accelerated

polyethylene wear^[8], anterior knee pain^[9] and decreased range of movement^[4].

The two most commonly used techniques for insertion of the femoral component of the TKA are the posterior condylar referencing measured resection (PCRM) technique and tibia first balanced flexion gap (TFBFG) technique. The PCRM technique starts with resection of the distal femur. It uses bony landmarks such as the femoral epicondyles^[10], anteroposterior axis (Whitesides line)^[11] and the posterior femoral condyles as references to resect the appropriate amount of the femoral condyles^[12]. The TFBFG technique starts with the tibial cut. The femoral component is then positioned by ligamentous balancing parallel to the resected proximal tibia.

There has been an ongoing debate whether the PCMR technique or the TFBFG technique achieves more optimal femoral component axial rotation. The comparison becomes difficult when parameters such as surgical expertise, manufacturers of the TKA systems, heterogeneity of populations and institutions are taken into consideration.

The question also arises whether femoral rotation is somehow related to coronal tibial component alignment, especially in the TFBFG technique. The rationale for this is as follows: the TFBFG technique starts with the tibial cut, followed by the femoral cut after balancing of the soft tissues of the knee^[13]. As these steps are interdependent, error in the varus/valgus tibial component placement may have the knock-on effect of altered femoral component rotation^[14]. On the contrary, it is less likely that tibial component alignment is related to femoral rotation in the PCMR technique, as the femoral cut precedes the tibial cut and the two cuts are made independently. Furthermore, coronal plane tibial component alignment is an important parameter in its own right, as any discrepancy can result in abnormal force distribution between medial and lateral tibiofemoral compartments, potentially resulting in accelerated wear and potentially failure of the arthroplasty^[15].

Two questions are posed by this study. First, does the PCMR technique or the TFBFG technique provide more normal rotational alignment of the femoral components? Second, is there a relationship between femoral axial rotation and tibial alignment in the coronal plane in both referencing systems?

PATIENTS & METHOD

Our study involved two TKA systems. First, we looked at the Anatomic Modular Knee (AMK) by DePuy (Johnson & Johnson, New Brunswick, New Jersey, USA) which has a fixed bearing and uses the PCMR technique. Second, we tested the Low Contact Stress (LCS) (also manufactured by DePuy) which uses the TFBFG technique. It is a mobile bearing TKA, and is widely used for both primary and revision TKA.

To predict sample size, we used our pilot data, informed by the literature^{[16], [17], [18]}. In our pilot study we found a mean femoral external rotation of 0.63 degrees and a standard deviation of 1.9 degrees. Given that a clinically relevant difference between the two groups was judged to be greater than 2°, a sample size of 20 subjects was sufficient to reveal

differences at the significance level $p < 0.05$.

All patients included in the study had either LCS or AMK TKA. All arthroplasty procedures were performed by a single surgeon (PNS) with an arthroplasty subspecialty. The exclusions included physical inability of the patient to participate or mentally incapacitated to participate in the study. The patients provided informed consent in accordance with the approval from the institutional human ethics committee.

The AMK group comprised 58 eligible patients of whom 20 participated in the study. 13 patients out of the 58 were deceased; 15 were reluctant to participate due to reasons ranging from inability to travel long distances, pressing engagements or being medically unwell to participate. Finally, 10 patients were untraceable. The TKA procedures for these patients were carried out between 1998 and 2000, with an average duration since procedure of 11.7 years. Of the 20 patients, none had bilateral AMK knees, but one had an AMK knee on one side and a LCS on the other. Of the 20, 18 were of Caucasian background, whereas one was from the West Indies and one from the Indian Subcontinent.


The LCS group comprised 40 eligible patients who were sent written invitations to participate in the study. The first 20 patients to respond were recruited. The TKA procedures for the LCS patients were carried out between 2000 and 2004 with an average duration since the procedure of 7.3 years. None of the LCS patients had bilateral LCS prostheses. All of the LCS patients were of Caucasian background. The AMK patients were slightly older (80.0 SD 5.0 years) than the LCS patients (79.2 SD 7.0 years), although this was not statistically significant ($p = 0.70$, t -test). Gender distribution was not significantly different between groups ($p = 0.47$, Chi squared) with the AMK group having 14 of 20 female, and the LCS group having 16 of 20 female.

Patients underwent CT scans of the operated knee as per the 'Perth CT Protocol'^[19]. A scout was obtained from the roof of the acetabulum to the base of the talus. A Multislice CT scanner, scanned 2.5mm slices from the acetabular roof to the dome of the talus with the legs in a standard position. Axial CT-scans at the level of the condyles were used to assess femoral rotation. Metal suppression sequences were deployed to suppress artifacts. A line drawn through the femoral epicondyles represented the transepicondylar axis (TEA)^[20] whereas a line drawn behind the posterior condyles

of the femur represented the posterior condylar axis (PCAx)^[20]. In order to measure femoral rotation, it was hypothesized that the TEA should be parallel to the PCAx^[21]. The rotational status of the femoral component can be expressed as the posterior condylar angle (PCA)^[20]. The PCA is the angle between the TEA of the femur and the PCAx of the prosthesis, and is the standard measure of rotation used in the literature, showing a mean of $3\pm$ of external rotation^{[22],[23]}. The landmarks to determine the PCA are best appreciated on axial CT scans. The ideal imaging modality to determine the posterior condylar angle has been the focus of a number of studies^{[24],[25]}. These studies concluded that CT scanning is the most reliable and accurate investigation. Plain radiography fails to appreciate bony landmarks that are apparent using three-dimensional imaging. For this reason all the subjects underwent CT imaging.

Figure 1

Figure 1 An axial CT through the distal femur shows the femoral component. Lines mark the transepicondylar axis and the posterior condylar axis. These lines should ideally be parallel

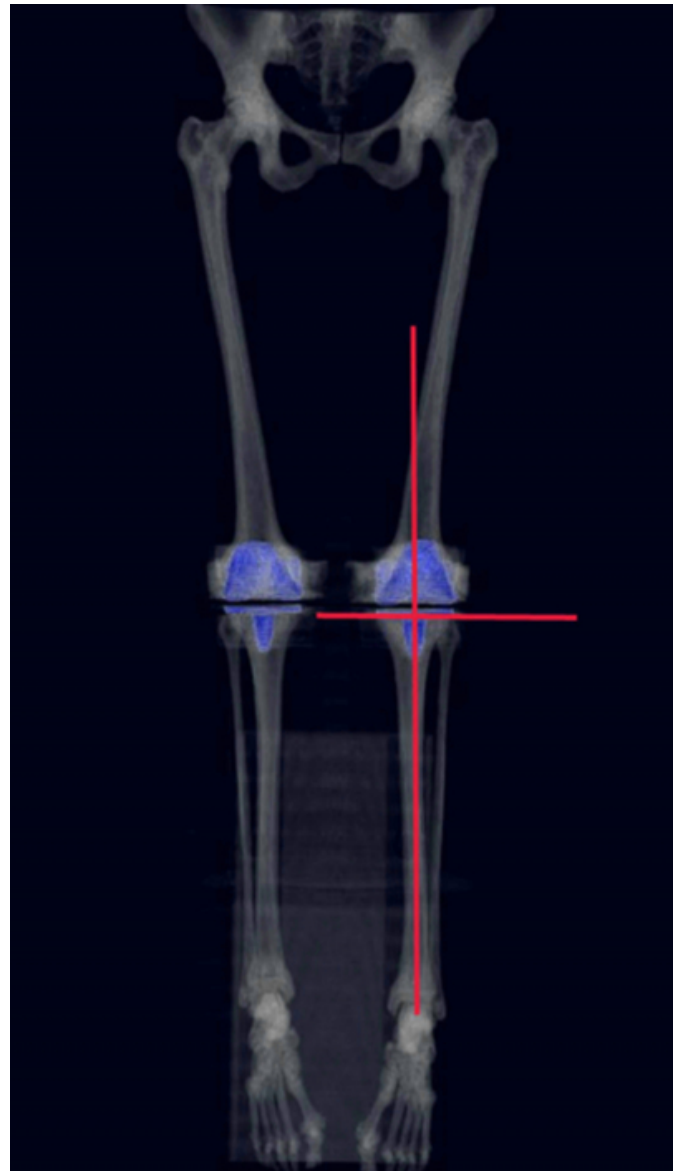


Measurement of the tibial alignment involved studying the coronal plane scout of the CT scan or the anterior-posterior long leg films of the affected side if the scout was insufficient. The scout included the roof of the acetabulum to the inferior surface of the talus. If the scout was not conclusive, then long leg x-rays were used. A line was drawn parallel to the base plate of the tibial component and

another line through the anatomical axis of the tibia. The angle between these two lines was used to describe Valgus (demonstrated as +) and Varus (demonstrated as -) angulation of the limb.

Figure 2

Figure 2: Coronal full length lower limb CT in a subject with bilateral total knee replacements. Lines show the long axis of the tibia, and the tibial component alignment. These lines should be perpendicular



RESULTS

There was no difference between mean femoral rotation in the AMK and LCS knees ($p = 0.36$). The femoral component rotation for the AMK knees was found to have a range of 4.8 degrees internal rotation to 7.6 degrees of external rotation (Mean 2.98 degrees external rotation, SD - 3.21 degrees).

For the LCS knees the rotation of the femoral component was found to have a range of 0.2 degrees internal rotation to 4.3 degrees of external rotation (Mean 2.26 degrees external rotation, +/- 1.26 degrees standard deviation).

There was no difference in the mean tibial alignment between the AMK and LCS knees ($p = 0.604$). Tibial alignment for AMK knees ranged from 1.4 degrees varus to 1.9 degrees valgus (Mean 0.4 degrees valgus, +/- 1.05 degrees Standard Deviation). Tibial alignment of the LCS knees ranged from 2.8 degrees varus to 4.9 degrees valgus (Mean 0.38 degrees valgus, +/- 2.01 degrees Standard Deviation) (Table 1).

Figure 3

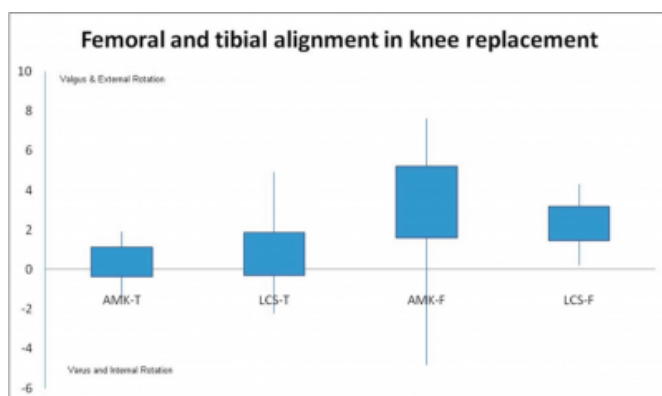
Table 1: Comparison of mean femoral rotation and tibial alignment.

		AMK	LCS	p =
Femoral Rotation	Mean (SD)	2.98 (3.21)	2.26 (1.26)	0.357
	Range	-4.80 to 7.60	0.20 to 4.30	
Tibial Alignment	Mean (SD)	0.40 (1.09)	0.38 (2.01)	0.604
	Range	-1.40 to 1.90	-2.80 to 4.90	

(Positive sign represents Valgus and External Rotation, whereas the negative sign shows Varus and Internal Rotation)

Figure 4

Figure 3: Distribution of tibial alignment for AMK & LCS; and AMK & LCS femoral component rotation. Boxplot describes the mean and the range. (T= Tibial Alignment), (F= Femoral Rotation)

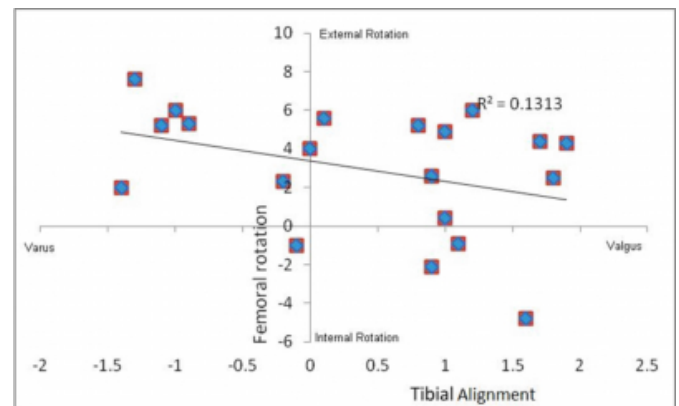


The data displayed in Fig. 3 didn't demonstrate a statistically significant relationship between the distributions of the

AMK and the LCS knees ($r = 0.36$, $p = 0.119$). Nevertheless, a wider range of distribution of the AMK Femoral component was noticed as compared to the LCS knee, which showed a neat narrower range of distribution with a mean quite similar to that of the AMK.

Figure 5

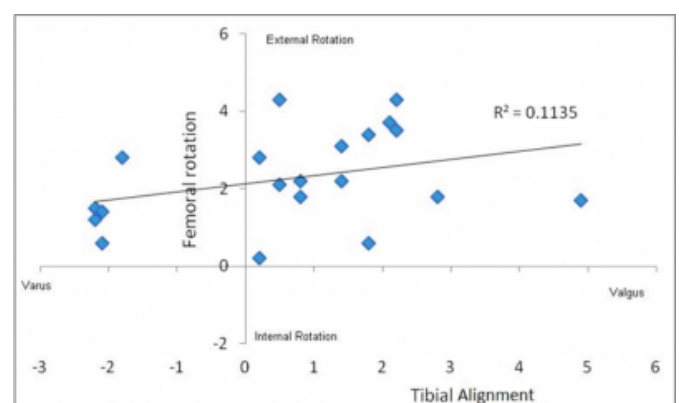
Figure 4: Femoral component rotation was not associated with tibial alignment in AMK knees.



The R^2 value for the AMK knee femoral rotation and tibial alignment in Fig 4 is 0.1313, which signifies that there is no correlation between the two parameters- as does the line of best fit. It can also be appreciated that the single dots are spread apart without significant clustering.

Figure 6

Figure 5: Femoral component rotation was not associated with tibial alignment in LCS knees.



The R^2 value for the LCS knee in Fig 5 is 0.1135, which signifies even less probability of a relationship existing between femoral rotation and tibial alignment. Nevertheless, the direction of the line of best fit may signify a remote possibility of some relationship. There seems to be less of a spread of the dots as compared to the AMK knees.

DISCUSSION

Improper placement of a prosthetic component, resulting in abnormal femoral component axial rotation, may impair its functionality in terms of prosthetic wear, arthrofibrosis, joint movement problems and eventually longevity of the prosthesis. This study investigated differences in femoral rotation produced by the PCMR technique and the TFBFG technique. Furthermore, the study explored if femoral rotation had any relationship with tibial alignment, especially in the case of the TFBFG technique.

The results demonstrated that the measured resection technique gave a satisfactory femoral external rotation of $2.9\pm$, which was close to the femoral rotation described in the literature for Caucasian populations^{[26], [20]}. Similarly, the flexion gap technique produced a mean femoral rotation of $2.26\pm$, which again was close to the rotation described in the literature on Caucasian populations^[27]. On the basis of sample means, neither of the two techniques was superior in achieving acceptable femoral rotation. However, the PCMR technique had a significantly larger range of component position, with several implants being in internal rotation. This may impact patellofemoral tracking, with a tendency toward lateral tracking with those implants in internal rotation. Considering the issue of reproducibility over the whole group, the TFBFG technique may offer an advantage. This is apparent from the boxplot chart in fig 3, where the range of distribution for the AMK is significantly larger than that for the LCS knees.

This study also demonstrated that in both referencing systems the femoral rotation did not have a statistically significant relationship with the tibial alignment of the prosthesis in the coronal plane. This is very much apparent from the low R^2 values in fig 4 and 5. However, the relationship between femoral rotation and tibial alignment is likely to apply for the TFBFG technique group^{[28], [29]}. It can be explained clinically by the inherent inaccuracy in tensioning the ligaments in the TFGFG. Furthermore, the line of best fit (Fig. 5) of the TFBFG technique group implies a relationship consistent with our hypothesis, although the R^2 value was slightly less than the one for PCMR. The sample size limitations of the study did not allow sufficient statistical power to assess significance.

This study did have some limitations. It was retrospective in design and sample size would need to be increased to allow effective analysis of the relationship between tibial alignment and femoral rotation in the TFBFG technique

group. The study's strengths were that the surgeries were performed by a single surgeon using consistent technique and the same standards. A larger prospective study involving several surgeons would improve the generalisability of the result to the wider surgical community and also give sufficient statistical power to assess significance.

References

1. Australian Orthopaedic Association National Joint Replacement Registry, Annual Report 2010.
2. American Association of Orthopaedic Surgeons 2010 Annual Meeting Presentation C. Ayers
3. NIH Consensus Development Program Conference on Total Knee Replacement- 2003
4. Verlinden C, Uvin P, Labey L, Luyckx J, Bellemans J, Vandenuecker H. The influence of malrotation of the femoral component in total knee replacement on the mechanics of patellofemoral contact during gait: an in vitro biomechanical study. *Journal Of Bone & Joint Surgery, British Volume* [serial online]. May 2010;92(5):737-742
5. Berger RA, Crossett LS, Jacobs JJ, Rubash HE; Malrotation causing patellofemoral complications after total knee arthroplasty. *Clinical Orthopedics and Related Research*. 1998 Nov;(356):144-53.
6. Amite Pankaj, Rajesh Malhotra and Surya Bhan; Femoral component malrotation and arthrofibrosis after total knee arthroplasty: cause and effect relationship? *International Orthopedics, Volume 31, Number 3, 423, DOI: 10.1007/s00264-006-0301-x*.
7. Huseyin S. Yercan, Tarik Ait Si Selmi, Tahir S. Sugun, Philippe Neyret; Tibiofemoral instability in primary total knee replacement: A review, *The Knee Journal, Volume 12, Issue 4, Pages 257-266*.
8. Vanbiervliet J, Bellemans J, Innocenti B, et al. The influence of malrotation and femoral component material on patellofemoral wear during gait. *Journal Of Bone & Joint Surgery, British Volume* [serial online]. October 2011;93(10):1348-1354
9. Blisard R. Component internal rotation malrotation a factor in pain after TKA. *Orthopedics Today* [serial online]. September 2011;31(9):24
10. Churchill DL, Incavo SJ, Johnson CC, Beynnon BD. The transepicondylar axis approximates the optimal flexion axis of the knee. *Clinical Orthopedics and Related Research*. 1998;356:111-8
11. Whiteside LA, Arima J. The anteroposterior axis for femoral rotational alignment in valgus total knee arthroplasty. *Clinical Orthopedics and Related Research* 1995;321:168
12. Hungerford DS, Krackow KA. Total joint arthroplasty of the knee *Clinical Orthopedics and Related Research* 1985;192:23-33
13. Stiehl JB, Cherveny PM. Femoral rotational alignment using the tibial shaft axis in total knee arthroplasty. *Clinical Orthopedics and Related Research* 1996: 47-55.
14. Hanada H, Whiteside L, Steiger J, Dyer P, Naito M. Bone landmarks are more reliable than tensioned gaps in TKA component alignment. *Clinical Orthopaedics And Related Research*. September 2007;462:137-142
15. Berend ME, Ritter MA, Meding JB, et al. Tibial component failure mechanisms in total knee arthroplasty. *Clinical Orthopedics and Related Research* 2004; (428):26-34.
16. Boldt JG, Stiehl JB, Hodler J, Zanetti M, Munzinger U

- (2006) Femoral component rotation and arthrofibrosis following mobile-bearing total knee arthroplasty. *International Orthopedics*, 30(5):420–425.
17. Siston RA; Patel JJ; Goodman SB; Delp SL; Giori NJ. The variability of femoral rotational alignment in total knee arthroplasty. *The Journal Of Bone And Joint Surgery. American Volume*. Vol. 87, no. 10. (1 October 2005) 2276-2280.
18. Katz MA, Beck TD, Silber JS, Seldes RM, Lotke PA. Determining femoral rotational alignment in total knee arthroplasty: reliability of techniques. *The Journal of Arthroplasty* 2001;16:301–5.
19. Chauhan SK, Clark GW, Lloyd S, Scott RG, Breidahl W, Sikorski JM. Computer-assisted total knee replacement. A controlled cadaver study using a multi-parameter quantitative CT assessment of alignment (the Perth CT Protocol). *J Bone Joint Surg Br*. 2004 Aug;86(6):818-23.
20. Yau W, Chiu K, Tang W et al. How precise is the determination of rotational alignment of the femoral prosthesis in total knee arthroplasty. *The Journal of Arthroplasty* 2007;Vol 22 No 7: 1042-1048.
21. Berger RA, Rubash HE, Seel MJ, et al. Determining the rotational alignment of the femoral component in total knee arthroplasty using epicondylar axis. *Clinical Orthopedics and Related Research* 1993;286:40
22. Griffin FM, Insall JN, Scuderi GR. The posterior condylar angle in osteoarthritic knee. *The Journal of Arthroplasty*. 1998; 13(7):812-815
23. Luo CF, Zeng BF, Koshino T. Transepicondylar line and condylar line as parameters for axial alignment in knee arthroplasty. *The Knee Journal*, 2004 June;11(3):213-7
24. Jazrawi LM, Birdzell L, Kummer FJ, Cesare PE. The accuracy of Computer Tomography for determining Femoral and Tibial Total Knee Arthroplasty Component Rotation, *The Journal of Arthroplasty*. 2000; 15(6):761-766
25. Boisgard S, Moreau PE, Descamps S, Courtalhiac C, Silbert H, Moreel P, Michel JL, Levai JP. Computed Tomographic study of the posterior condylar angle in arthritic knees: its use in the rotational positioning of the femoral implant of total knee prostheses. *Surgical Radiology and Anatomy*. 2003; 25(3-4):330-4
26. Poilvache PL, Insall JN, Scuderi GR, Font-Rodriguez DE. Rotational landmarks and sizing of the distal femur in total knee arthroplasty. *Clinical Orthopedics and Related Research*. 1996; (331):35-46.
27. Witoolkollachit P, Seubchompoo O. The comparison of femoral component rotational alignment with transepicondylar axis in mobile bearing TKA, CT-scan study. *Journal of Medical Association of Thailand*. 2008 Jul;91(7):1051-8
28. Hanada H, Whiteside L, Steiger J, Dyer P, Naito M. Bone landmarks are more reliable than tensioned gaps in TKA component alignment. *Clinical Orthopedics and Related Research* September 2007;462:137-142
29. Fang D, Ritter M. Malalignment: forewarned is forearmed. *Orthopedics [serial online]*. September 2009;32(9):681.

Author Information

Mansoor Ahmed, MD

Trauma and Orthopaedic Research Unit, Canberra Hospital

Jennie M. Scarvell, B(App)Sc, PhD

Trauma and Orthopaedic Research Unit, Canberra Hospital

Matthew Alfredson, MBBS

Trauma and Orthopaedic Research Unit, Canberra Hospital

Thomas Ward, MBBS, D.Phil

Trauma and Orthopaedic Research Unit, Canberra Hospital

Paul N. Smith, BMBS, FRACS

Trauma and Orthopaedic Research Unit, Canberra Hospital