

Splenic Abscess – A Report Of 2 Cases.

S Mittal, P Garg, S Aggarwal, A Narang, S Verma, S Bhoirwal

Citation

S Mittal, P Garg, S Aggarwal, A Narang, S Verma, S Bhoirwal. *Splenic Abscess – A Report Of 2 Cases..* The Internet Journal of Surgery. 2012 Volume 28 Number 3.

Abstract

Splenic abscess is an uncommon but potentially life-threatening disease that generally occurs in patients with neoplasia, immunodeficiency, hemoglobinopathies, trauma, metastatic infection, and diabetes. Splenic abscess should be considered in a patient with fever, left upper abdominal pain, and leucocytosis. Splenectomy has been the gold standard treatment for splenic abscess but is associated with high morbidity rates. With the recent development of minimally invasive techniques and percutaneous US or CT guided procedures, percutaneous aspiration has achieved excellent results with resolution of the disease in a high percentage of cases with low morbidity and negligible mortality. Percutaneous aspiration is indicated for uniloculated and biloculated abscess and for high-risk surgical patients. It is a reliable technique with a high rate of therapeutic success and low costs compared to surgery. Other advantages include avoiding risks of intra-abdominal spillage and perioperative complications and saving time, along with a better patient compliance and an easier nursing care. Our result suggests that ultrasound-guided percutaneous aspiration is a safe and feasible alternative to surgery in the treatment of carefully selected cases of splenic abscesses. This approach allows splenic preservation.

INTRODUCTION

Splenic abscess is an uncommon disease, with a reported incidence of 0.14-0.7% in autopsies in Western countries and a dismal prognosis if not properly treated.^{1,2} In tropical countries, where sickle cell anaemia is widespread, splenic abscess shows a higher incidence related to the fact that these patients have a predisposition to splenic infarction due to splenic vein thrombosis.

The first historical evidence of splenic abscess dates back to Hippocrates, who pointed out the peculiar features of this pathology. Nowadays, diagnosis is based on US examination and can be possibly completed by CT scan, selective angiography and ⁹⁹Tc-labelled scintigraphy, which permits a differential diagnosis with other affections as subphrenic and pancreatic abscesses.

In the past, splenectomy was considered the only treatment of such septic complications, with a low mortality rate but a relatively high morbidity related to patients' general conditions.³ With the recent development of percutaneous US and CT guided techniques, needle aspiration has gained excellent results with complete recovery of the patients in a high percentage of cases.⁴

We describe two cases of splenic abscess treated by percutaneous US guided needle aspiration followed by the

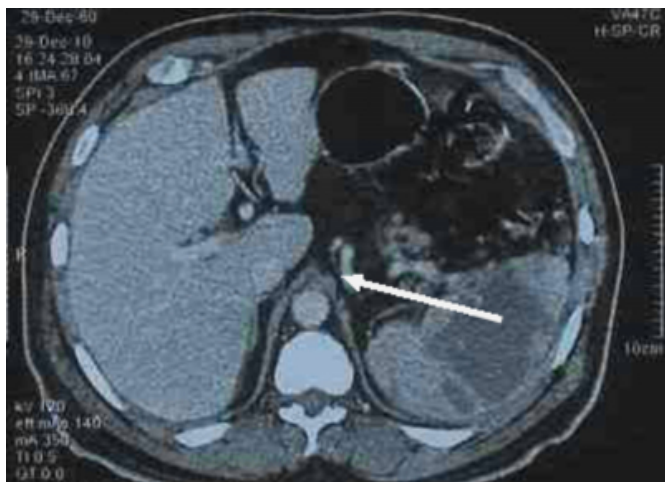
complete resolution of symptomatology.

CASE REPORT 1

A 55-year-old, known diabetic and alcoholic, male patient was admitted to our hospital with fever, dyspepsia and left upper quadrant pain. On physical examination, temperature was 39.4°C, pulse 102/min, respiratory rate 24/min and blood pressure 150/96mmHg. There was tenderness in the left hypochondrium. WBC count was 18000/mm³ with 90% neutrophils. Haemoglobin was 12.7g/dl and blood sugar was 220 mg/dl. Chest X-ray revealed no abnormality. USG and CECT of the abdomen revealed an abscess cavity of around 12 x 10cm in the spleen (figure 1). Initially, the patient was put on antibiotic therapy but he did not improve. He was switched on insulin to control his blood sugar. Eventually, USG-guided needle aspiration with an 18-G spinal needle was done. Around 300cc of thick yellowish fluid was aspirated. This fluid was sent for culture and antibiotics were started accordingly. The patient started improving after aspiration. Serial ultrasonographies were done every third day which showed progressive decrease in the size of the abscess cavity. The patient was discharged 2 weeks after the 1st aspiration.

Figure 1

Figure 1: CECT of the abdomen showing a splenic abscess



CASE REPORT 2

A young male patient of 20 years was admitted with complaints of fever and pain in the left upper half of the abdomen. On physical examination, he was having tachycardia and tachypnoea. There was tenderness in left hypochondrium and epigastrium. WBC count was 15000/mm³ with 85% neutrophils. USG examination revealed an abscess cavity of around 8 x 6cm in the spleen. The patient was initially put on antibiotic therapy but his clinical condition did not improve. USG needle aspiration was done and around 200cc thick yellowish fluid was aspirated. Antibiotics were given according to culture report of aspirated fluid. The patient started improving clinically. On serial ultrasonography the size of the cavity progressively decreased and he was discharged. He developed jaundice due to hepatitis A 4 weeks after discharge. He was managed by a physician after hospitalization and got well subsequently.

DISCUSSION

In the past, antibiotic therapy and splenectomy were considered the treatments of choice for splenic abscess.^{5,6} Because of the increased number of immunocompromised patients within the general population, the incidence of splenic abscesses has increased over the last decade.⁷ The spleen is important for proper immunologic function, and splenectomy carries an increased morbidity rate with the danger of postsplenectomy infections. Current therapeutic strategies established spleen-preserving treatment in cases of

trauma and benign lesions. Thus, percutaneous drainage of splenic abscesses is used instead of surgical treatment with good results^{8,9}, provided that certain conditions are present. Percutaneous treatment is the most convenient when the abscess collection is unilocular or bilocular with a discrete wall and no internal septations, and when its content is liquid enough to be aspirated. Percutaneous treatment is indicated especially when patients are in critical condition or when the risks of general anaesthesia, open drainage, or splenectomy are quite substantial. Some authors report that percutaneous drainage or needle aspiration should be considered as the first line of treatment, reserving splenectomy for exceptional cases only.^{8,9} We recommend needle aspiration, primarily in the treatment of splenic abscess, since experience with our cases showed that needle aspiration was sufficient to solve these splenic abscesses in most cases. Also, the method is much simpler and less aggressive than percutaneous catheter drainage, allowing shorter hospital stay and lower costs. In conclusion, ultrasound-guided percutaneous aspiration of splenic abscess is a safe and effective alternative to surgery, allowing preservation of the spleen, avoiding perioperative complications, ensuring better compliance and easier nursing care. This treatment is indicated especially when patients are in critical condition postoperatively or when the risks of general anaesthesia, open drainage, or splenectomy are substantial.

References

1. Lee WS, Choi ST, Kim KK: Splenic abscess: a single institution study and review of the literature. *Yonsei Med J*; 2011; 52: 288-92.
2. Ferraioli G, Brunetti E, Gulizia R, Mariani G, Marone P, Filice C: Management of splenic abscess: report on 16 cases from a single center. *Int J Infect Dis*; 2009; 13: 524-30.
3. Ooi LL, Nambiar R, Rauff A, Mack PO, Yap TL: Splenic abscess. *Aust N Z J Surg*; 1992; 62: 780-4.
4. Zerem E, Bergsland J: Ultrasound guided percutaneous treatment for splenic abscesses: the significance in treatment of critically ill patients. *World J Gastroenterol*; 2006; 12: 7341-5.
5. Tung CC, Chen FC, Lo CJ: Splenic abscess: an easily overlooked disease? *Am Surg*; 2006; 72: 322-5.
6. Paris S, Weiss SM, Ayers WH Jr, Clarke LE: Splenic abscess. *Am Surg*; 1994; 60: 358-61.
7. Farres H, Felsher J, Banbury M, Brody F: Management of splenic abscess in a critically ill patient. *Surg Laparosc Endosc Percutan Tech*; 2004; 14: 49-52.
8. Schaberle W, Eisele R: Percutaneous ultrasound controlled drainage of large splenic abscesses. *Chirurg*; 1997; 68: 744-8.
9. Chou YH, Tiu CM, Chiou HJ, Hsu CC, Chiang JH, Yu C: Ultrasound-guided interventional procedures in splenic abscesses. *Eur J Radiol*; 1998; 28: 167-70.

Author Information

Sachin Mittal, M.B.B.S.

Department of Surgery, Pt. B. D. Sharma Postgraduate Institute of Medical Sciences

Pradeep Garg, M.S, D.N.B.

Department of Surgery, Pt. B. D. Sharma Postgraduate Institute of Medical Sciences

Sourabh Aggarwal, M.B.B.S.

Department of Surgery, Pt. B. D. Sharma Postgraduate Institute of Medical Sciences

Amit Narang, M.B.B.S.

Department of Surgery, Pt. B. D. Sharma Postgraduate Institute of Medical Sciences

Surender Verma, M.S

Department of Surgery, Pt. B. D. Sharma Postgraduate Institute of Medical Sciences

Sandeep Bhoariwal, M.S

Department of Surgery, Pt. B. D. Sharma Postgraduate Institute of Medical Sciences