

# Unexpected Nasal Foreign Body Found During Adenoidectomy

J Gulia, S Yadav, A Hooda

## Citation

J Gulia, S Yadav, A Hooda. *Unexpected Nasal Foreign Body Found During Adenoidectomy*. The Internet Journal of Family Practice. 2012 Volume 10 Number 1.

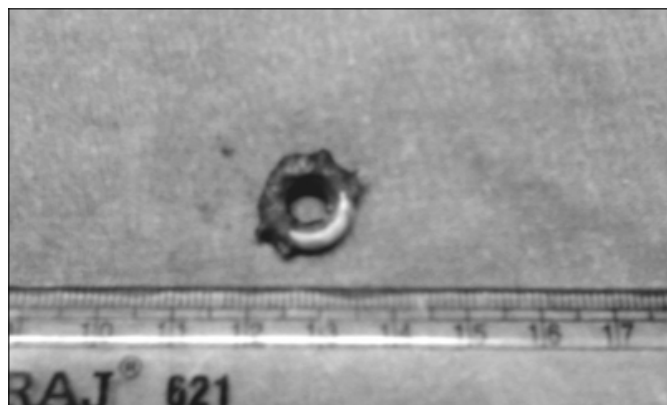
## Abstract

Dear Sir,

A case of unexpected foreign body nasal cavity is being presented. An 8 year old child presented with history of recurrent attacks of rhinosinusitis and otitis media. He was diagnosed as adenoid hypertrophy which was confirmed by an X-ray of the soft tissue nasopharynx. Under general anesthesia with oro-tracheal intubation, adenoidectomy was done using adenoid curette. After adenoidectomy we could not pass the suction catheter into the naso-pharynx in the right side. A rigid nasal endoscopy using pediatric 2.7 mm endoscope was done. A foreign body was seen impacted in the right inferior meatus surrounded by granulations and deposition of salts and it was removed. (Figure 1).

## Figure 1

Figure 1: Removed plastic ring from the right nasal cavity with deposition of salts



The incidence of nasal foreign bodies is highest in the

children aged 2-5 years. In most cases, the insertion of the nasal foreign body is witnessed, but in some cases there may be delayed presentations and the most common clinical scenario is unilateral nasal discharge. Unless the cause for the obstruction or rhinorrhea is investigated it may go undetected and continue to present further problems for the patient<sup>1</sup>. An inserted object can remain relatively asymptomatic or cause local tissue damage and potentially yield more serious consequences<sup>2</sup>. Nasal obstruction is common in children, and is often attributed to adenoid enlargement. Kubba and Bingham performed nasal endoscopy in forty-eight children aged two to nine years undergoing adenoidectomy, and six normal controls, under general anesthesia with a rigid endoscope. They found that three quarters of the children had abnormalities on endoscopy in addition to enlarged adenoids, and in 23 per cent these were potentially of major clinical significance (unsuspected foreign body, gross septal deviation, gross hypertrophy of the turbinates). The authors concluded that the nasal endoscopy is a safe, objective and useful means of identifying potentially significant abnormalities in children with nasal obstruction<sup>3</sup>. The present case also confirms that a nasal endoscopy should be performed after adenoidectomy.

## References

1. Passy V, Newcron S, Snyder S. Rhinorrhea with airway obstruction. *Laryngoscope* 1975; 85:888-95
2. Yasny JS, Stewart S. Nasal foreign body: an unexpected discovery. *Anesth Prog* 2011; 58: 121-3
3. Kubba H, Bingham BJ. Endoscopy in the assessment of children with nasal obstruction. *J Laryngol Otol* 2001; 112: 380-4.

**Author Information**

**Joginder Singh Gulia**

Professor, Department of Otolaryngology, Pt. B.D Sharma University of Health Sciences Rohtak

**S P S Yadav**

Senior Professor, Department of Otolaryngology, Pt. B.D Sharma University of Health Sciences Rohtak

**Anita Hooda**

Associate Professor, Department of Oral Anatomy, Pt. B.D Sharma University of Health Sciences Rohtak