

A Case Of Two Synchronous Tumour Of Different Histology - Advanced Cervical Adenocarcinoma With Borderline Mucinous Ovarian Tumour In A 22 Year Old Virgin.

N Kavitha, T Who, S Kanagasabai, F Ahmad

Citation

N Kavitha, T Who, S Kanagasabai, F Ahmad. *A Case Of Two Synchronous Tumour Of Different Histology - Advanced Cervical Adenocarcinoma With Borderline Mucinous Ovarian Tumour In A 22 Year Old Virgin..* The Internet Journal of Gynecology and Obstetrics. 2012 Volume 16 Number 2.

Abstract

We report a case of synchronous cervical adenocarcinoma with borderline mucinous ovarian tumour in a 22 year old virgin who presented with prolonged bleeding and dysmenorrhoea of four months duration. A transabdominal ultrasound demonstrated fluid in the endometrial cavity. This was confirmed by MRI pelvis revealing a distended endometrial cavity with cervical stenosis. Evacuation revealed hematometra and the post evacuation uterine cavity is empty. She was discharged and subsequently presented at three months with acute urinary retention and heavy bleeding. A CT pelvis showed complex bilateral ovarian cyst with minimal ascites, an enlarged paraaortic node at L2 and hematometra with cervical stenosis. An exploratory laparotomy was performed with cystectomy, supracolicomentectomy with uterine and cervical biopsy. The histopathology shows bilateral borderline mucinous tumor of the ovary with metastatic omental nodules and primary well differentiated adenocarcinoma of the cervix. The subsequent CT thorax revealed metastatic pulmonary nodules. In view of advanced cervical adenocarcinoma, she was advised palliative chemotherapy with carboplatin and paclitaxel for six cycles. She has currently completed one cycle of chemotherapy. Conclusion: This case is one of the rare presentations of synchronous tumours of different histology with primary cervical adenocarcinoma and bilateral borderline ovarian tumour occurring in a virgin with atypical clinical presentation and rapid progression.

INTRODUCTION

The incidence of cervical adenocarcinoma has increased dramatically over the past few decades especially in younger women. The frequency of adenocarcinomas is approximately 15-20 % of all the invasive cancers (1). Although the histological variants of cervical cancer share the same risk factors, they are extremely rare in virgins. The cases of multiple simultaneous primary cancers of female genital tract are of rare occurrence. They are often reported as malignancies with similar histopathology like carcinoma of ovary and endometrium in about 10 % of women probably attributed to the same embryological development of the surface epithelium of the ovary from the müllerian duct (3). This case is rare with synchronous tumours of cervix and ovary of different histopathology occurring in a virgin with atypical clinical presentation.

CASE REPORT

A 22 year old nulliparous and not sexually active woman presented to our hospital with prolonged heavy bleeding and

dysmenorrhoea of four months duration. She denied any gastrointestinal symptoms. Her previous menstrual history was unremarkable and there is no significant past medical or surgical history. Ultrasonography revealed a hypoechoic mass measuring 4.8x4.7 cm in the uterine cavity (Fig.1) that was confirmed by MRI pelvis as hematometra with cervical stenosis (Fig.2). Examination under anaesthesia was planned. The findings of EUA: The hymen is intact, cervix healthy, os stenosed, uterus 12-14 weeks size. Pipelle aspiration of the cavity revealed clear fluid followed by blood and pus and the specimen sent for infection screening and biochemistry workup. The post evacuation uterine cavity is empty with no evidence of hematometra. Her bleeding was controlled and was discharged subsequently. She presented after three months with acute urinary retention and heavy bleeding. At this stage, she was managed with medroxy progesterone acetate for her bleeding and continuous bladder drainage for urinary retention. Ultrasound revealed normal kidneys and urinary bladder and distended uterine cavity with recurrent hematometra. A CT abdomen and pelvis showed large

complex right ovarian cyst of size: 12.2 cm x 9.8cm x21.0 cm, left ovary measured 5 cmx2.9 cm x3.3 cm with several cyst inside (Fig.3). The uterus was enlarged with hematometra and no focal enhancing lesion was observed in the cervix. There is an enlarged paraaortic node of 1.2 cmx 1.1 cm at the L2 vertebral level. Minimal ascites was noted. The CA 125 levels were 112U/mL. The preoperative diagnosis was ovarian carcinoma and in view of suspected ovarian malignancy, an exploratory laparotomy was performed that revealed ascitic fluid of 800 cc, large right ovarian tumor of size 12x10x8 cm, multicystic, thin walled, left ovarian tumor of size 5x4x4 cm. The paraaortic node was enlarged. The upper one third of the vagina is stenosed and the cervix appeared flushed and adherent to the stenosed vaginal wall. As the patient is nulliparous, bilateral ovarian cystectomy with supracolicomentectomy was performed along with the biopsy of uterus cervix and omentum.

Figure 1

Fig 1: USG showing fluid in the endometrial cavity

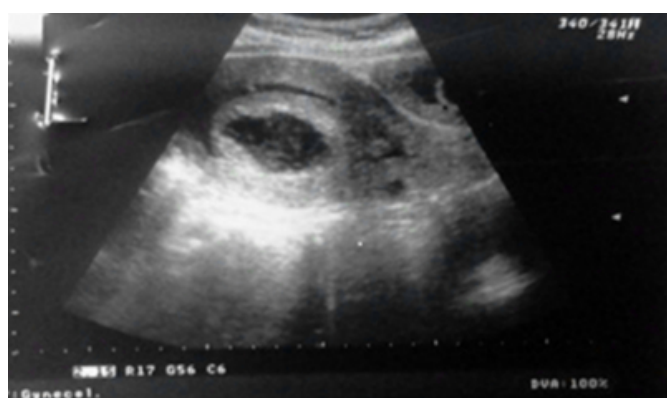

Figure 2

Fig 2: MRI showing hematometra with cervical stenosis

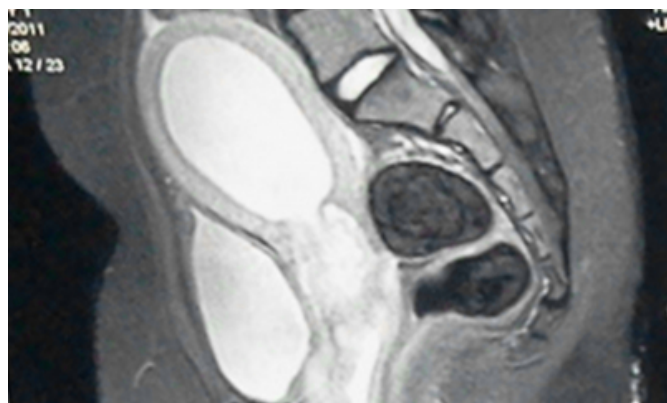
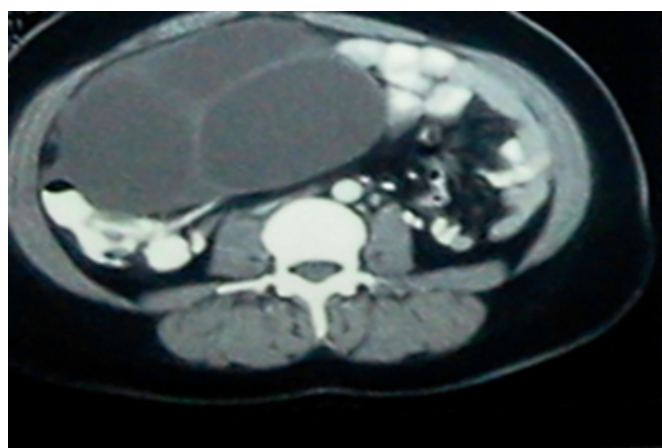


Figure 3

Fig 3: CT showing complex right ovarian cyst



The histopathology report of the right and left ovary revealed multiple locules lined by single layer of mucinous epithelium with mild nuclear stratification in not more than three layers of cells. There was no atypia, no invasion or any evidence of malignancy. The findings are consistent with borderline mucinous tumours. (Fig. 5A&B). The immunohistochemistry stain was positive for CK 7. They are negative for CK 20, vimentin, CEA and CA 125. The cervical biopsy is suggestive of well differentiated adenocarcinoma with immunohistochemistry positive for CK7, CEA (Focal) and increase in Ki 67, negative for CK 20, vimentin and CA 125, all suggestive of primary well differentiated adenocarcinoma of the cervix. (Fig 4 A,B,C,D). Also the biopsy was negative for HPV and p 53. The omental nodule, lymph nodes and uterine biopsy are suggestive of metastatic adenocarcinoma (6A, B). The subsequent CT thorax revealed metastatic nodules lung. The final diagnosis was primary cervical adenocarcinoma stage IV B. In view of advanced cervical adenocarcinoma, she was initiated on palliative chemotherapy with carboplatin and paclitaxel for six cycles. She has currently completed one cycle of chemotherapy.

Figure 4

Fig 4: Cervical biopsy H&E: 40 X 4A-Tumour cells arranged in crowded glands with desmoplastic stroma. The glands are well differentiated. Immunohistochemistry stain 4B-positive for CK7, 4C -focal positive for CEA, 4D-Increase in Ki-67.

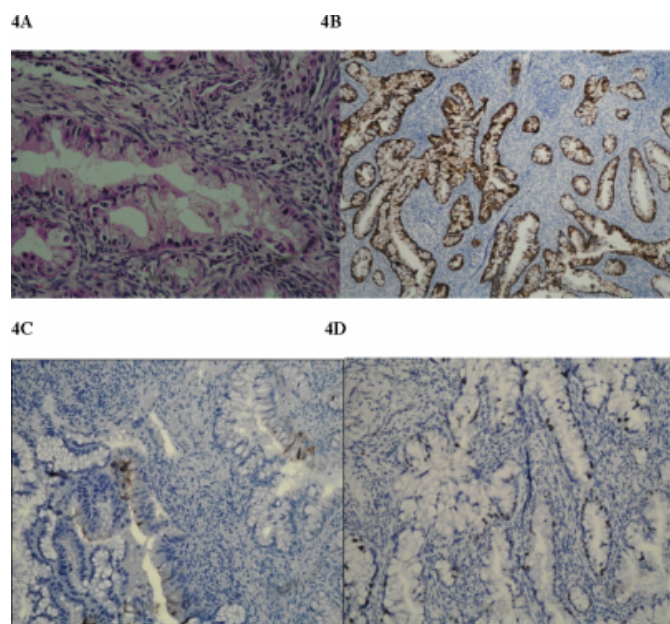


Figure 5

Fig 5A&B: Low malignant potential of the right and left ovary (H&E x 40).

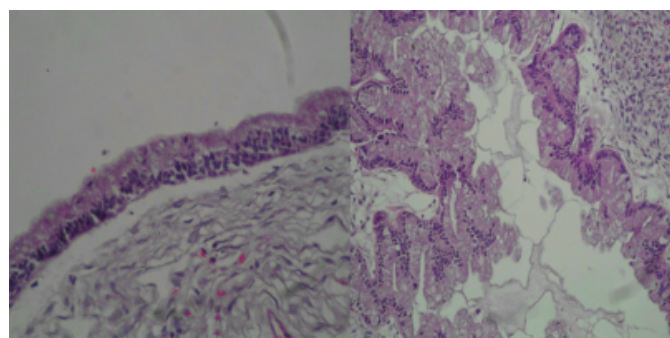
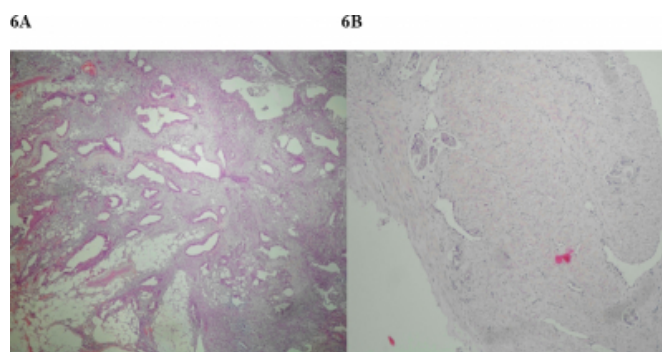


Figure 6

Fig 6 A: The omental nodule H & E 4X showing malignant epithelial cells in crowded glands with desmoplastic stroma. There is abundant intracytoplasmic mucin. 6B: Uterine biopsy H&E 10 X: Shows foci of tumor tissue embedded within the smooth muscle. There is prominent lymphatic embolization.



DISCUSSION

The majority of cervical cancers are squamous cell in origin. There has been a recent increase in the trend of adenocarcinomas and it accounts for 25 % of all invasive cervical cancers (1, 2). Although adenocarcinomas share the same risk factors with its squamous counterpart, the available evidence suggests that they have slightly different subtypes of HPV implicated in the carcinogenesis. The subtype HPV 18 is responsible for 50% of adenocarcinomas in comparison to 15 % in squamous cell carcinomas (3,4). Smoking is not a risk factor for adenocarcinoma and parity has a weaker association (5).

The presence of hematometra in young and adolescent women should raise a suspicion of müllerian anomalies like unicornuate uterus with non-communicating rudimentary horn that manifests as dysmenorrhoea and hematometra (6). The presence of uterine fluid collection is suggestive of uterine malignancy in a postmenopausal woman. In view of the age of our patient, an MRI was performed to rule out congenital anomalies of the uterus that was conclusive of fluid in the uterine cavity and cervical stenosis with no evidence of uterine anomalies.

The presence of synchronous bilateral borderline mucinous ovarian tumour and cervical adenocarcinoma in our case is a finding of considerable interest. Synchronous tumours are defined as the simultaneous occurrence of two or more tumours in a patient (7). It has been reported that synchronous multiple primary tumours are relatively rare and comprises about 0.63% of all genital malignancies (8). The most

common synchronous association frequently reported are endometrial and ovarian cancer. A case of synchronous ovarian endometrioid carcinoma and squamous cell carcinoma of the cervix has been reported in 1996 (9) and in 2010 (10). The mechanism of occurrence remains unclear and is probably when embryologically similar tissues (mullerian origin) are simultaneously exposed to carcinogens, they can predispose to synchronous neoplasms (11). This theory is plausible in case of tumors of similar histology; however, this may not be the mechanism of carcinogenesis operating in tumors of different histology like in our case and may require further studies.

The management dilemma is in the confirmation of these tumours as independent primaries or metastatic tumours. Immunohistochemistry plays an important role in their differentiation as suggested by Eswari et al especially in places with limited resources (12). In our case the presence of malignant cells exhibiting positive for CK7, CEA and vimentin negative is suggestive of primary endocervical carcinoma differentiating it from endometrial origin. The immunohistochemistry stains from the section of ovarian cyst are positive for CK7, negative for CK 20, vimentin, CEA are suggestive of primary ovarian tumour.

The other intriguing factor in our case is the etiology of the primary cervical adenocarcinoma. Although the current understanding is that 90 % of cervical cancers are diagnosed in sexually active women, it can also occur in virgins like in our case. The cervical biopsy sample section of our case was sent for immunostaining for HPV and p53 analysis and is found to be negative. It has been estimated that only 60-85% of cervical adenocarcinomas are associated with HPV infection (13). From the study by Milde-Langosch et al. the HPV dependent carcinogenesis is due to inactivation and inhibition of the antiproliferative effect of the cyclic kinase dependent inhibitors p16, p21, p27 by the viral oncogenes (14). The exact mechanism for the HPV independent pathway is not known. It is implicated that low levels of these cyclic kinase inhibitors demonstrated in the HPV negative cervical adenocarcinoma suggests that down regulation of these cell cycle inhibitors may play a role in the carcinogenesis (15).

The other etiology suggested is the activation of k-ras oncogene or inactivation of the tumor suppressor gene p53 such as point mutation or genetic polymorphism that initiates malignant transformation that is independent of HPV (16). But the findings by Kessis TD et al. suggest that

HPV infection and p53 gene mutation are not mutually exclusive and that many HPV-negative carcinomas may arise via a pathway independent of p53 inactivation (20).

There is also increasing body of evidence to support nonsexual transmission of HPV infection. There is a perinatal and vertical transmission of HPV with the development of laryngeal papillomatosis in the neonate. It has been suggested that there is evidence for indirect transmission through HPV contaminated fomites although their role in causing active infection is likely to be small (17).

Based on the current knowledge available, it is conceivable that the aetiology of cervical adenocarcinoma in our case is related to HPV independent carcinogenesis, probably independent of the P53 gene as evidenced by immunohistochemistry negative for HPV and p53 or activation of k-ras oncogene or down regulation of cyclic kinase inhibitors. It is well known that the time interval between the HPV infection to invasive cancer is around ten years. This rapid onset of adenocarcinoma of the cervix in a young patient is identified to be likely in HPV negative cases as studied by Liebrich et al. (18). This is also supported by findings of G. Riou et al. that these HPV negative tumours are biologically different subset of tumours with poor prognosis (19).

In conclusion, synchronous tumours of the ovary and cervix are rarely reported especially tumours of different histopathology. The underlying phenomenon responsible for these synchronous tumours of different histology is yet to be identified. The confirmation from our case finding suggests the likelihood of cervical adenocarcinoma occurrence in a virgin with atypical presentation and rapid progression that is probably related to HPV independent genetic mechanism of carcinogenesis. The present case is reported with these perspectives. However, the synchronous tumours of different histology and molecular genetics of HPV independent carcinogenesis deserve further studies to enhance our knowledge of these rare though potential occurrences.

References

1. Alfson GC, Thoresen SO, Kristensen GB et al: Histopathologic subtyping of cervical adenocarcinoma reveals increasing incidence rates of endometrioid tumors in all age groups: a population based study with review of all nonsquamous cervical carcinomas in Norway from 1966 to 1970, 1976 to 1980, and 1986 to 1990. *Cancer*; 2000; 89:1291.
2. Gien LT, Beauchemin MC, Thomas G. Adenocarcinoma: a unique cervical cancer. *Gynecol Oncol*; 2010; 116:140.
3. Tornesello ML, Losito S, Benincasa G et al. Human

- papillomavirus (HPV) genotypes and HPV16 variants and risk of adenocarcinoma and squamous cell carcinoma of the cervix. *GynecolOncol*;2011; 121:32.
4. Sherman ME, Wang SS, Carreon J, Devesa SS: Mortality trends for cervical squamous and adenocarcinoma in the United States. Relation to incidence and survival. *Cancer*; 2005; 103:1258.
 5. Castellsagué X, Díaz M, de Sanjosé S et al: Worldwide human papillomavirus etiology of cervical adenocarcinoma and its cofactors: implications for screening and prevention. *J Natl Cancer Inst*; 2006; 98:303.
 6. Beatriz L. P. Junqueira, MD, Lisa M. Allen, MD, FRCSC, Rachel F. Spitzer, MD, BSc, MPH, FRCSC et al: Müllerian Duct Anomalies and Mimics in Children and Adolescents: Correlative Intraoperative Assessment with Clinical Imaging. *RadioGraphics*; July 2009; 29:1085-1103.
 7. Ree YS, Cho SH, Kim SR, Kim KT, Park MH: Synchronous primary endometrial and ovarian cancer with three different histologic patterns: a case report. *Int J Gynecol Cancer*;2003; 13:678–682.
 8. Momcilo D, Slobodanka M, Gordana D, Bozidar J: Endometrioid tumour of the ovary and the uterus, metastasis or not – Case Report. *Acta Medica Medianae*;2007; 47 (4):15-19.
 9. Pitynski K, Bogdanowicz M, Jawornik M: Coexistence of endometrioid ovarian tumour and squamous cell carcinoma. *GinekPol*;1996;67(12):629-31.
 10. K.R. Srivatsava & F. Zahra: Synchronous primary malignancy of ovary and cervix with different histology presentation. *The internet journal of Gynaecology and Obstetrics*;2010; Volume 12 Number 2.
 11. Jaime P, Xavier M, Jose B: Simultaneous carcinoma involving the endometrium and the ovary. A clinicopathologic, immunohistochemical, and the DNA flow cytometry study of 18 cases. *Cancer*;1991; 68(11) 2455-2459.
 12. Eswariv, Geethaprakash, Irfan, Ansari et al: Endometrioid carcinoma of the ovary and uterus – synchronous primaries and metastasis: a case report. *Journal of clinical and diagnostic research*;2011 August; Vol-5 (4):875-879.
 13. Duggan MA, McGregor SE, Benoit JL et al: The human papillomavirus status of invasive cervical carcinoma: a clinicopathological and outcome analysis. *Hum Pathol*; 1995; 26:319–325.
 14. Karin Milde-Langosch, Sabine Riethdorf, Alexandra Kraus-Pöppinghaus, Lutz Riethdorf, Thomas Lönning: Expression of cyclin-dependent kinase inhibitors p16^{MTS1}, p21^{WAF1}, and p27^{KIP1} in HPV-positive and HPV-negative cervical adenocarcinomas. *Virchows Arch*;2001; 439:55–61.
 15. Riethdorf S, Riethdorf L, Milde-Langosch K, Park TW, Lönning T: Differences in HPV 16 and HPV 18 E6/E7 oncogene expression between in situ and invasive adenocarcinoma of the cervix uteri. *Virchows Arch*; 2001; 437: 491-500.
 16. Uchiyama M, Iwasaka T, Matsuo N, Hachisuga T, Mori M, Sugimori H: Correlation between human papillomavirus positivity and p53 gene overexpression in adenocarcinoma of the uterine cervix. *GynecolOncol*; 1997 Apr;65(1):23-9.
 17. F.X. Bosch, T. Iftner: The aetiology of cervical cancer, Sheffield, UK: NHS cervical screening programme, 2005.
 18. Liebrich C, Brummer O, Von Wasielewski R, Wegener G, Meijer C, Iftner T, Petry KU: Primary cervical cancer truly negative for high-risk human papillomavirus is a rare but distinct entity that can affect virgins and young adolescents. *Eur J GynaecolOncol*; 2009;30(1):45-8.
 19. G. Riou Prof MD, J. Bourhis MD, M. Favre PhD, G. Orth DVM, D. Jeannel MD V. Le Doussal MD : Association between poor prognosis in early-stage invasive cervical carcinomas and non-detection of HPV DNA. *Lancet*;1990 May 19;335(8699):1171-4.
 20. Kessis TD, Slebos RJ, Han SM, Shah K, Bosch XF, Muñoz N, Hedrick L, Cho KR: p53 gene mutations and MDM2 amplification are uncommon in primary carcinomas of the uterine cervix. *Am J Pathol*; 1993 Nov;143(5):1398-405.

Author Information

Nagandla Kavitha

Assistant Professor, Department Of Obstetrics And Gynaecology, Melaka Manipal Medical College

Tham Seng Who

Head Of Department, Department Of Obstetrics And Gynaecology, Melaka General Hospital

Sachchithanantham Kanagasabai

Head Of Department, Department Of Obstetrics And Gynaecology, Melaka Manipal Medical College

Faizah Ahmad

Pathologist, Department Of Pathology, Melaka General Hospital