

Giant Right Atrial Mass: An Unusual Presentation Of Unruptured Sinus Of Valsalva Aneurysm

S Chandraprakasam, L Stickley

Citation

S Chandraprakasam, L Stickley. *Giant Right Atrial Mass: An Unusual Presentation Of Unruptured Sinus Of Valsalva Aneurysm*. The Internet Journal of Cardiology. 2012 Volume 10 Number 2.

Abstract

Sinus of valsalva aneurysm (SOV) is an uncommon but well-recognized cardiac condition requiring emergent surgical management when it ruptures. We report a ninety-three-year-old woman with progressive dyspnea on exertion diagnosed to have a giant right atrial "mass" arising in close proximity to the non coronary cusp on sinus of valsalva on transthoracic echocardiogram. She underwent surgical excision of the aneurysm and confirmed to have unruptured sinus of valsalva aneurysm of non coronary cusp extending into the right atrium. This case also highlights the conduction abnormalities associated with this condition. We review the literature on sinus of valsalva aneurysm and discuss the unusual presentation and association with arrhythmias.

CASE DESCRIPTION

A 93-year-old white woman presented with gradual onset of progressively worsening dyspnea on exertion for four weeks. She denied orthopnea, paroxysmal nocturnal dyspnea, cough, leg swelling, and angina on exertion. Her past medical history was significant for essential hypertension, gastroesophageal reflux disease, degenerative arthritis of knees and transient ischemic attacks. Her medications included baby aspirin, metoprolol, and lansoprazole.

Physical examination revealed a pulse of 86 beats per minute, blood pressure of 132/86 millimeters of mercury with no significant difference between the extremities, and respirations of 16 per minute. Cardiac auscultation was unremarkable and the lungs were clear to auscultation. Her initial work-up revealed normal blood counts, electrolytes and electrocardiogram showed a first degree heart block. Chest X-ray revealed mild cardiomegaly and atherosclerotic aorta (Figure 1).

Transthoracic echocardiogram (TTE) revealed a large, 57mm x 65mm, spherical, heterogeneous mass in the right atrial cavity by the apical four chamber view (Figure 2). Short axis view at the level of aortic valve shows the aneurysm arising in close proximity to non coronary cusp of sinus of valsalva (Figure 3/movie clip). The parasternal long axis view showed an apparent defect in the aortic wall (Figure 4) although there was no demonstrable any doppler flow through the defect (Figure 5). There was no evidence of

significant regurgitation or stenosis of any valves. The calculated left ventricle ejection fraction was 60%. Right ventricular systolic function was within normal limits. Selective cardiac catheterization revealed non obstructive coronary artery disease involving the mid left anterior descending artery with no evidence of high grade obstruction of other epicardial coronary arteries.

A median sternotomy incision was created and cardiopulmonary bypass was created after successfully cannulating the ascending aorta and the vena cavae. On opening the right atrium open, a lobular necrotic mass measuring approximately six centimeters in size was seen to encroach on the entire right atrium (RA) which was found partially adherent to the right atrial roof, aortic wall and dissecting into the interatrial septum (IAS). The mass had a layer of tissue overlying. The entire mass was resected along with a button of the aortic wall which was quite adherent and thinned out in that region of attachment to the mass. Corrective surgeries to repair the defects in the right atrial roof, IAS and the aortic wall were performed successfully.

Post-operatively the clinical course was complicated by severe bradycardia. She underwent a permanent pacemaker insertion for her sick sinus syndrome. However, she then developed atrial flutter and was successfully cardioverted. She had to be started on amiodarone to prevent recurrence.

Histopathological exam (HPE) of the mass revealed

predominantly blood clot with a thin fibrous wall around the periphery composed of densely collagenous fibrous tissue showing areas of dystrophic calcification, collections of foamy histiocytes, hemosiderin deposition, and focal areas of mild chronic inflammation suggestive of atherosclerotic changes. These findings were consistent with an aneurysm containing a luminal thrombus. (Figure 6)

We report this case of sinus of valsalva aneurysm presenting as a giant right atrial mass because of its rarity, a very unusual presentation and association with conduction abnormalities such as sinus sick syndrome.

Figure 1

Figure 1 – CXR PA view shows cardiomegaly with atherosclerotic changes in the aorta (arrow)

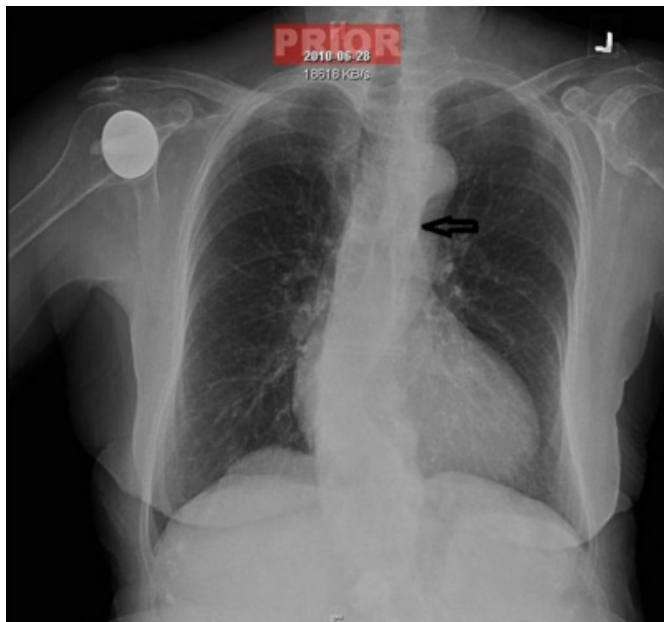


Figure 2

Figure 2 - Transthoracic echocardiogram – Apical four chamber view shows a giant right atrial spherical mass measuring 57 X 65 mm which appeared to be heterogeneous in appearance

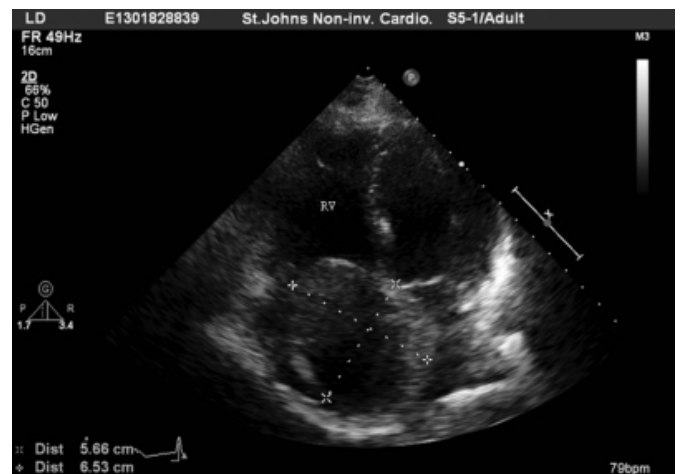

Figure 3

Figure 3 - Transthoracic echocardiogram – short axis view at the aortic valve level shows the aneurysm arising in close proximity to the non coronary cusp of the aortic valve (arrow)

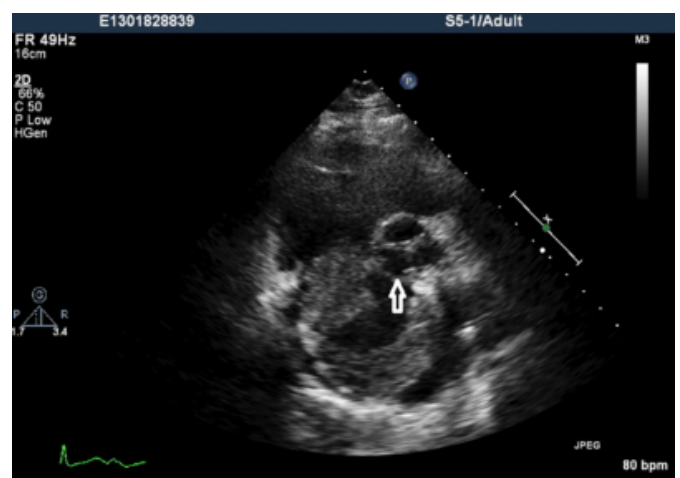


Figure 4

Figure 4 - Transthoracic echocardiogram - Parasternal long axis view showing an apparent wall defect in the aortic root (arrow)

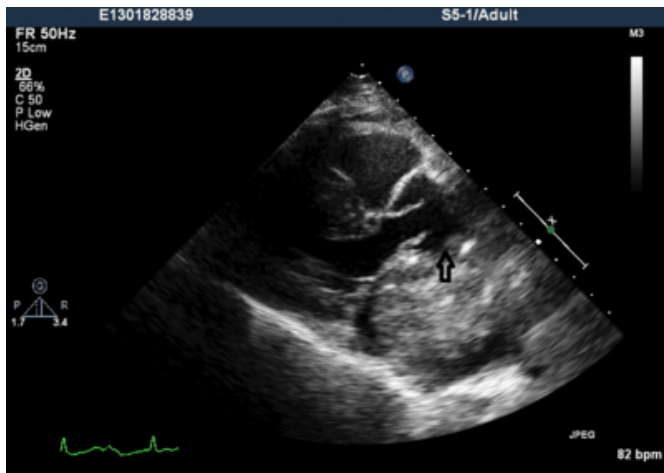


Figure 5

Figure 5 - Doppler Echocardiogram – short axis view at aortic valve level shows no abnormal flow between the aorta and the right atrium

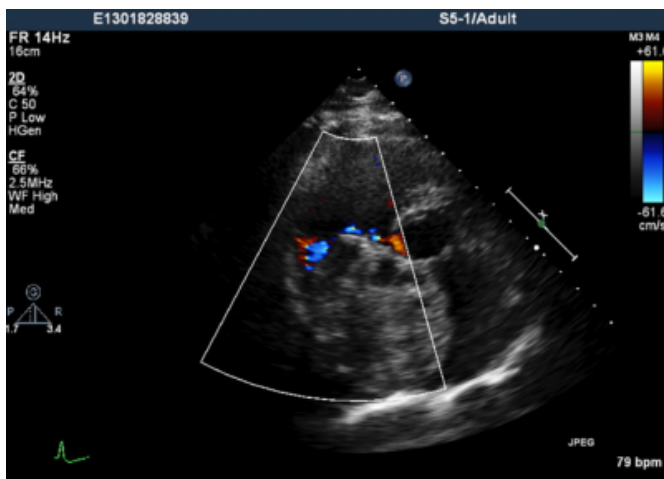
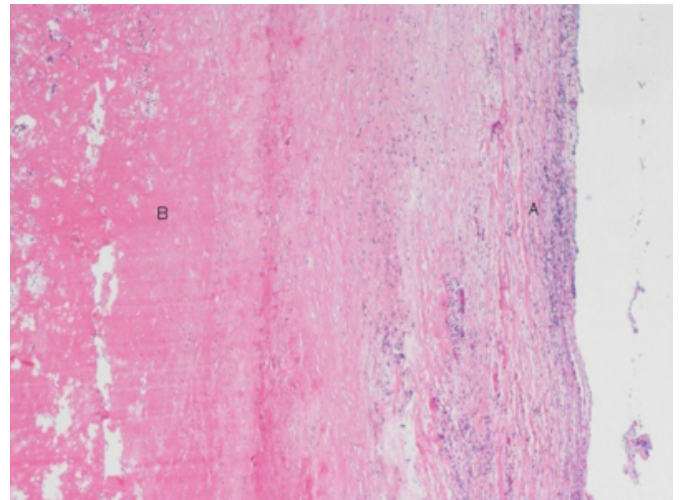


Figure 6

Figure 6 – Histopathological exam with Hematoxylin and Eosin stain shows a fibrous wall (A) with a luminal clot (B)



DISCUSSION

Sinus of valsalva aneurysm (SVA) is a rare congenital anomaly. SVAs are characterized by abnormal dilation of aortic sinus above the supra aortic ridge secondary to disease process affecting the medial wall of the aortic root. SVAs can be congenital, inherited or acquired. Congenital and inherited forms manifest in the third or fourth decade of life¹. The common etiologies of acquired sinus of valsalva aneurysm include atherosclerosis, syphilis, infective endocarditis, dissecting aortic aneurysms². The prevalence of SVAs varies from 0.1% to 4.5% with rates being higher in the Asian surgical series³⁻⁴. Approximately 65-85% of SVAs originate from the right sinus of Valsalva, while those originating from noncoronary (10-30%) and left sinuses (<5%) are exceedingly rare⁵. The aneurysm malformation usually involves a single cusp and more often arise from the right coronary cusp. It is uncommon to find the aneurysm abnormality on x ray as they are intracardiac. However, the evidence of aortic atherosclerosis is a clue to the etiology as evidenced in this patient. Rarely these aneurysms can cause heart border abnormalities depending upon the cusp involved⁶⁻⁷. Marked cardiomegaly can be visualized if aortic root dilation and aortic insufficiency are present⁷. Unruptured SVA is usually asymptomatic and is often detected serendipitously by routine 2-dimensional echocardiography, even in patients older than 60 years. Unruptured SVA is often asymptomatic and has almost no physical signs. When SVA ruptures, few specific signs of left-to-right shunting may become apparent. Physical exam shows a continuous murmur with signs of acute heart failure.

Heart failure is usually left-sided secondary to aortic regurgitation. Unusual presentation of sinus of valsalva aneurysm with right sided heart failure secondary tricuspid valve regurgitation has been described⁸. Other rare manifestations of unruptured SOVs include ventricular tachycardia, inter atrial septal mass, and stroke⁹⁻¹². However, the most feared complication of this anomaly is a rupture creating left to right aorto–cardiac shunts with profound hemodynamic instability¹³. The rupture can occur sometimes extracardiac e.g. into the pericardium. The most common site is the rupture of sinus of valsalva (RSOV) aneurysm of the right coronary cusp into the right ventricle (90%) followed by the non coronary cusp into the right atrium (8%) followed by the left coronary cusp into pericardial space (<2%) which are commonly fatal¹⁴. We suggest what appeared to be a giant “mass” in the right atrium was actually the SVA growing into the right atrium. The HPE confirmed the presence of aneurysm in the right atrium. The aneurysm wall did not reveal any epithelial lining or any tumor cytology ruling out cystic lesions and myxomas. In this case, the mass did not cause any significant obstruction or incompetence of the tricuspid valve nor any hemodynamic abnormality of the right ventricle which explains the benign clinical exam. We also highlight the tumultuous post-operative course complicated by tachy – brady syndrome requiring permanent pacemaker insertion. Our search in the literature did not reveal any report of association of sick sinus syndrome (SSS) with SVA at the time of the publication of this case report.

CONCLUSION

This case report illustrates a very unusual presentation of unruptured SVA and association of sick sinus syndrome with sinus of valsalva aneurysm which has not been reported in the literature. Two dimensional (2D) Echocardiography is

still the preferred non invasive modality used to diagnose this condition.

References

1. Perloff JK. Congenital aneurysms of the sinuses of Valsalva. In: Clinical recognition of congenital heart disease, 5th ed. Philadelphia: Saunders 2003, p. 457.
2. Fishbein MC, Obma R, Roberts WC. Unruptured sinus of Valsalva aneurysm. *Am J Cardiol* 1975; 35:918–22.
3. Prian GW, Diethrich EB. Sinus of Valsalva abnormalities. A specific differentiation between aneurysms of aneurysms involving the sinuses of Valsalva. *Vasc Surg.* 1973; 7(3):155-64.
4. Chu SH, Hung CR, How SS, Chang H, Wang SS, Tsai CH, et al. Ruptured aneurysms of the sinus of Valsalva in Oriental patients. *J Thorac Cardiovasc Surg.* 1990; 99(2):288-98.
5. Meier JH, Seward JB, Miller FA, et al. Aneurysms in the left ventricular outflow tract: clinical presentation, causes, and echocardiographic features. *J Am Soc Echocardiogr.* 1998; 11(7):729-45
6. Ritter M, Oechslin E, Jenni R. Giant congenital aneurysm of the noncoronary sinus of Valsalva. *Heart* 2002;88:243.
7. Goldberg N, Krasnow N. Sinus of Valsalva aneurysms. *Clin Cardiol* 1990; 13: 831–836
8. Shiv Bagga I, Prashant N. Mohite, Sreenivas Reddy, Shyam K. Thingnam, and Kewal K. Talwar. Unusual cause of rapidly progressive right-sided heart failure: aortic sinus of Valsalva aneurysm causing ball valve obstruction of the tricuspid valve. *European Journal of Echocardiography* 2009; 10: 721–723.
9. Channer KS, Hutter JA, George M. Unruptured aneurysm of the sinus of Valsalva presenting with ventricular tachycardia. *Eur Heart J* 1988; 9:186–90.
10. Walsh JT, Andrews R. Unruptured aneurysm of the left sinus of Valsalva presenting with atrial fibrillation. *Int J Cardiol* 1994; 46:297–8.
11. Reverdin S, Rabaeus M, Kalangos A. Large Valsalva sinus aneurysm simulating an interatrial septum mass. *Ann Thorac Surg* 2007; 83:696.
12. Stollberger C, Seitelberger R, Fenninger C, Prainer C, Slany J. Aneurysm of the left sinus of Valsalva. An unusual source of cerebral embolism. *Stroke* 1996; 27:1424–6.
13. Ruptured congenital aneurysm of the sinus of valsalva in the aged. Kyobu Geka. 1990;43(6):502-4.
14. Grellner W, Karsch KR, Bültmann B. Fatal outcome of a congenital aneurysm of the right sinus valsalvae ruptured into the right atrium. *Z Kardiol.* 1995 Jul; 84(7):553-9

Author Information

Satish Chandraprakasam, MD

Division of Internal Medicine, Mercy Hospital

Louis P Stickley, MD

Division of Cardiology, Mercy Heart and Vascular