

# Intussuscepting Rectal Lipoma: A Case Report and Review of Literature

K Manickavasagam, S Chandramohan, J Lakshmi, K Vairavan, J Madhusudhanan

## Citation

K Manickavasagam, S Chandramohan, J Lakshmi, K Vairavan, J Madhusudhanan. *Intussuscepting Rectal Lipoma: A Case Report and Review of Literature*. The Internet Journal of Gastroenterology. 2012 Volume 11 Number 1.

## Abstract

Lipomas are the second most common benign colorectal neoplasm. Rectallipomas are rare compared to colonic lipomas, with less than 15 cases described. In contrast to colonic lipomas which are usually asymptomatic, most of the rectal lipomas are symptomatic. We present here our patient with symptomatic rectal Lipoma and review the limited data available in the current surgical literature.

## CASE REPORT

An 85-year-old lady presented with difficulty of passing stools and bleeding per rectum. Her physical examination was normal. Colonoscopy revealed a large, solitary, polypoidal intussuscepting mass occluding more than 90% of circumference of the lumen of mid rectum. Carcinoembryonic antigen level was 1.950ng/ml. Contrast enhanced computerized tomography scan revealed a mobile, well defined lesion of fat density measuring 5 cm.

As the mass was large and sessile, it was not amenable for endoscopic resection. Also it was higher up in the rectum precluding transanal excision. Hence laparotomy was performed. The mass was found to be arising from the lateral and anterior wall of the mid rectum. The serosa over the lesion was normal except for mild indentation. A colotomy was made on the rectal wall opposite to the location of the mass. There was an ulcer at the summit and inflammation due to recurrent intussusception. The lesion was found to involve more than two-thirds of the circumference.

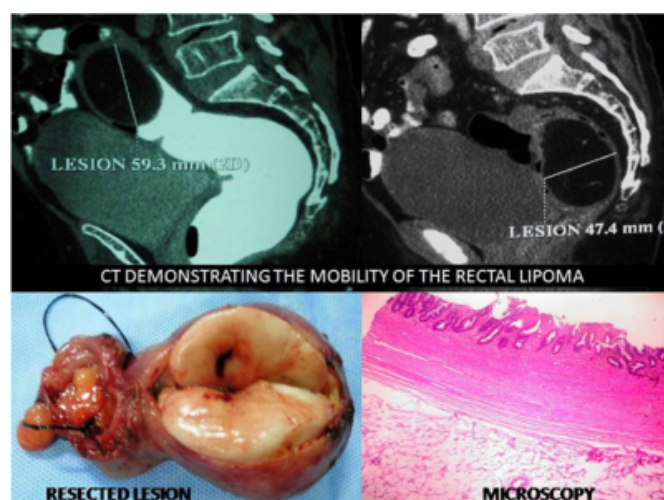
The rectum was mobilized all around with a five centimeter proximal and distal clearance preserving the rectal vascularity. The anvil of circular stapler DST EEA 28 was passed to the proximal sigmoid through a colotomy. The tip of the anvil was brought out through the antemesocolic incision, about seven centimeters from the proposed proximal transection. The proximal and distal low rectum were transected with DST TA 60 4.5mm stapler. The anvil was approximated to the EEA 28 stapler passed transanally and

side-to-side rectosigmoidostomy was completed. She had an uneventful recovery in the postoperative period.

Macroscopic inspection of the resected rectal specimen revealed a smooth, soft, lobulated, ovoid, sub mucous tumour of 7cm diameter (Figure 1). It had a wide base and cut section revealed adipose tissue. Histopathology was consistent with lipoma.

## Figure 1

Figure 1: CT scan picture demonstration intussusceptions of rectal lipoma (top panel). Resected gross specimen and microscopy.



## DISCUSSION

Lipomas are benign mesenchymal tumors that can arise anywhere in the gastrointestinal tract. They constitute the

second most common benign colorectal neoplasm after adenomatous polyps. The most common site of lipomas in the gastrointestinal tract is the cecum and ascending colon [4]. Lipomas located in the rectum are very rare. A search in PUBMED was attempted with the terms, 'colon lipomas' and 'rectal lipomas'. We selected series having more than 10 cases of colon lipomas published in the English language (Table 1). A total of 227 patients with colorectal lipomas were reported by seven different authors. The number of patients with rectal lipomas was 9 out of 227 with the incidence of 3.9%. There were also few solitary case reports of rectal lipoma presenting with prolapse and other complications.[8,9,10]

Most colonic lipomas are asymptomatic and usually detected at colonoscopy. The incidence at autopsy was reported to be 0.35 to 4.4% underlying the fact that they largely remain clinically silent.[2] They usually occur in 5<sup>th</sup> to 6<sup>th</sup> decades of life with slight female preponderance. Symptoms are probably related to size and location. Large colonic lipomas (> 2 cm) and most rectal lipomas are symptomatic. The usual symptoms of rectal lipoma are constipation, anal discomfort and tenesmus. They can also present with history of bleeding per rectum if the overlying mucosa is ulcerated in which case it becomes difficult to differentiate from malignancy. [12] Rectal lipoma can present with complications like bleeding, rectal prolapse and anal incarceration.[11]

Pathologically, lipomas in rectum can be sessile or polypoid. They may form a pseudostalk due to repeated episode of prolapses. Majority of them are located in the submucosal plane. 10% of colorectal lipomas can be found in the subserosal plane. Rectal lipomas are usually solitary. However, colonic lipomas can be multiple in upto 5 -10% of cases.

At colonoscopy, the lesions are well-defined, smooth, ovoid yellow structures sometimes with protruding fat on the surface (naked fat sign). The mucosa overlying it can be pinched up with a biopsy forceps (tent sign) and incompressible (cushion sign).[13] However, atypical appearances of lipoma mimicking adenomatous polyp or malignancy are also reported.[12] These features preclude an accurate preoperative diagnosis in up to 60% of cases.[14] Endoscopic ultrasound can be used especially to study the base of the lesion for assessing the feasibility of endoscopic resection. Barium enema may show a round regular filling defect which may deform easily with peristalsis (squeeze sign). Computerized tomography scan reveals a well-defined lesion with telltale attenuation of fat

(-40 to -120 Hounsfield Units). At magnetic resonance imaging, it appears hyperintense on both T1W and T2W images with suppression of signal on fat suppression sequences. However, small lipomas and long-standing lipomas with ischemic changes can give atypical appearances on imaging leading to diagnostic confusion.[15]

All rectal lipomas should be excised as they are usually large and produce symptoms. Rectal lipomas can be excised endoscopically, transanally or via open or laparoscopic surgery.[9,16] Endoscopic excision of large rectal lipomas can be difficult with increased risk of bleeding and perforation. Transanal excision is feasible as shown by Martelluci et al. especially if the lesion is already prolapsing.[16] Injection of lignocaine or adrenaline saline in the submucosa beneath the lesion will aid in safer resection decreasing the risk of perforation.

Surgical excision remains the gold standard. If the diagnosis is made preoperatively, these can be enucleated or excised by colotomy or anterior resection. As accurate preoperative diagnosis could not be made, patients may end up with major oncological resection and lipomas are detected only after histological examination of the specimen. We are in agreement with this approach and recommend aggressive resection in all atypical cases.

In conclusion, rectal lipomas are rare with less than 15 cases reported in the literature. They are usually symptomatic requiring excision. In atypical cases, it may present a diagnostic and therapeutic challenge.

### **References**

1. Castro EB, Stearns MW. Lipoma of the large intestine: A review of 45 cases. *Dis Colon Rectum*. 1972;15(6):441-444.
2. Haller JD, Roberts TW. Lipomas of the colon: A clinicopathologic study of 20 cases. *Surgery*. 1964;55:773-781.
3. Michowitz M, Lazebnik N, Noy S, Lazebnik R. Lipoma of the colon. A report of 22 cases. *Am Surg*. 1985;51(8):449-454.
4. Rogy MA, Mirza D, Berlakovich G, Winkelbauer F, Rauhs R. Submucous large-bowel lipomas--presentation and management. an 18-year study. *Eur J Surg*. 1991;157(1):51-55.
5. Taylor BA, Wolff BG. Colonic lipomas. report of two unusual cases and review of the mayo clinic experience, 1976-1985. *Dis Colon Rectum*. 1987;30(11):888-893.
6. Ryan J, Martin JE, Pollock DJ. Fatty tumours of the large intestine: a clinicopathological review of 13 cases. *Br J Surg*. 1989 Aug;76(8):793-6
7. Hancock BJ, Vajner A. Lipomas of the colon: A clinicopathologic review. *Can J Surg*. 1988;31(3):178-181.
8. Katsinelos P, Chatzimavroudis G, Zavos C, Kountouras J. Endoloop-assisted amputation of a large rectal lipoma. *Gastrointest Endosc*. 2007;66(3):636-637.
9. Nijhawan S, Rai RR, Mathur A, Bhargava N. Rectal

lipoma treated by endoscopic polypectomy. *Indian J Gastroenterol.* 1993;12(1):23.

10. Yadoo S, Dintzman M, Chaimoff C. Lipoma of the rectum. two case reports. *Am J Proctol.* 1971;22(2):120-122.

11. Robert PE, Meurette G, Lehur PA. An unusual case of rectal prolapse. *J Visc Surg.* 2011;148(6):e452-3.

12. Zhang X, Ouyang J, Kim YD. Large ulcerated cecallipoma mimicking malignancy. *World J Gastrointest Oncol.* 2010;2(7):304-306

13. Pfeil SA, Weaver MG, Abdul-Karim FW, Yang P. Colonic lipomas: outcome of endoscopic removal.

*Gastrointest Endosc.* 1990 Sep-Oct;36(5):435-8.

14. Lazaraki G, Tragiannidis D, Xirou P, Nakos A, Pilpilidis I, Katsos I. Endoscopic resection of giant lipoma mimicking colonic neoplasm initially presenting with massive haemorrhage: A case report. *Cases J.* 2009;2:6462.

15. Arora R, Kumar A, Bansal V. Giant rectal lipoma. *Abdom Imaging.* 2011 Oct;36(5):545-7

16. Martellucci J, Civitelli S, Tanzini G. Transanal resection of rectal lipoma mimicking rectal prolapse: description of a case and review of the literature. *ISRN Surg.* 2011;2011:170285. Epub 2011 Apr 10.

**Author Information**

**Kanagavel Manickavasagam, M.B.B.S, DNB, MRCS**

Consultant Surgeon, St Isabel Hospital

**SM Chandramohan, M.S., M.Ch. FACS**

Professor and Head, Department of Surgical Gastroenterology, Center of Excellence for Upper GI Surgery, Madras Medical College and Rajiv Gandhi Government General Hospital

**Jandhyala Soundarya Lakshmi, MD**

Consultant, Department of Obstetrics and Gynaecology, St Isabel Hospital

**Kamaraja Vairavan, MD PDCC**

Consultant, Department of Anaesthesiology, St Isabel Hospital

**J Madhusudhanan, MS**

Senior Resident, Department of Surgical Gastroenterology, Center of Excellence for Upper GI Surgery, Madras Medical College and Rajiv Gandhi Government General Hospital