

# Unilateral Tubal Twin Ectopic Pregnancy: An Unusual Case

A Kakani., S Goel., D Shrivastava., V Shrivastava.

## Citation

A Kakani., S Goel., D Shrivastava., V Shrivastava.. *Unilateral Tubal Twin Ectopic Pregnancy: An Unusual Case*. The Internet Journal of Gynecology and Obstetrics. 2012 Volume 16 Number 2.

## Abstract

Unilateral twin ectopic pregnancy is a rare condition and only about 100 cases have been reported in the literature. In this article, we present a case of ruptured twin ectopic pregnancy in the right fallopian tube. A 45 year old woman who had come to our department with acute pain in abdomen transvaginal ultrasonography showed ruptured right tubal ectopic twin pregnancy. Twin ectopic pregnancy, even though rare, must be looked for on ultrasound scanning with increasing incidence of pelvic inflammatory disease because of the potential mortality and morbidity associated with this condition.

## INTRODUCTION

Ectopic pregnancy is a common medical problem and it pose a serious diagnostic and therapeutic challenge in the obstetrics as the presenting symptoms and signs vary widely between patients. The incidence of this disease has been increasing over the past. There are multiple factors that contribute to the relative risk of ectopic pregnancy such as a history of tubal surgery, conception after tubal ligation, using fertility drugs and assisted reproductive technology(1). The unilateral twin tubal pregnancy is quite rare with a reported incidence of 1:200 ectopic pregnancies (2). It is a rare condition, first described in 1891 by De Ott (3). The present report describes a successful management of acute on chronic ruptured tubal twin ectopic pregnancy in a tubectomised female.

## CASE REPORT

A 45 year old tubectomised female, came to casualty at midnight with pain in abdomen since three days and bleeding per vaginum since morning .She had four living issues with all full term normal deliveries. She underwent tubal ligation 10 years back. She had a history of irregular cycles since then. Her last menstrual period was one and half months back (she was unsure of the dates). Upon examination, her vitals were stable. Her abdomen was distended and a vague tender mass was palpable in the right hypochondrium. Upon per vaginum examination the cervical movement was tender, the uterus was bulky and soft, and boggiess and tenderness were felt in the right adnexa. However, her urine pregnancy test was negative.

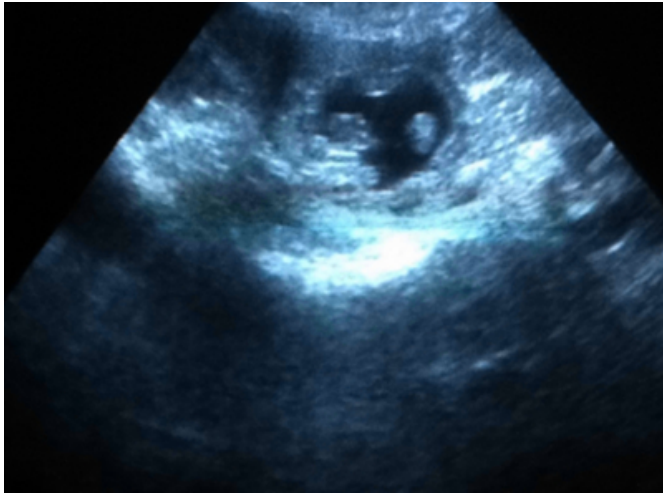
Ultrasonography with doppler study showed a uterus of 7.3X

6.4X 3.2 cms with endometrial thickness of 5mm and there was evidence of large heterogenous lesion in the right adnexa of a size 7.1X5.1 cms, with sac like structure within which two foetal poles measuring 1.2 = 7 weeks and five days with absent cardiac activity, and a positive ring of fire appearance was seen (Fig.1). Free fluids with internal echoes were seen in the abdomen. An impression of chronic twin ectopic pregnancy in the right adnexa was made with free fluid in an abdomen of ruptured chronic twin ectopic pregnancy.

In view of the ruptured ectopic pregnancy she was immediately shifted for exploratory laparotomy. Intraoperatively, a large collection of blood (approx.800 ml) was found in the pelvic cavity. The ampullar part of the right fallopian tube was found ruptured and a sac like structure was lying outside (Fig.2). A right sided salphingectomy was done. Haemostasis was achieved and the abdomen was closed. She received 2 units of blood transfusions and her post operative period was uneventful. She was discharged on the 7<sup>th</sup> day. On cut section of the sac there was evidence of two embryos (Fig.3). Pathological evaluation of the surgical specimen showed a monozygotic monochorionic twin pregnancy within the fallopian tube and measurement of the twin fetuses estimated their gestational age at 7 weeks.

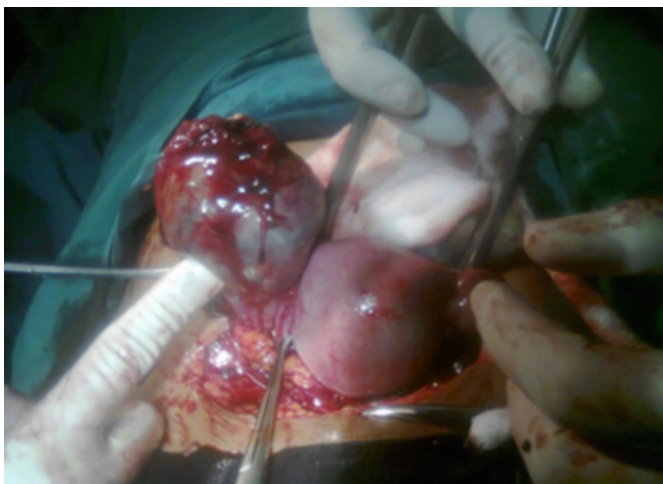
**Figure 1**

Fig.1 Ultrasonographic picture of ruptured twin ectopic pregnancy



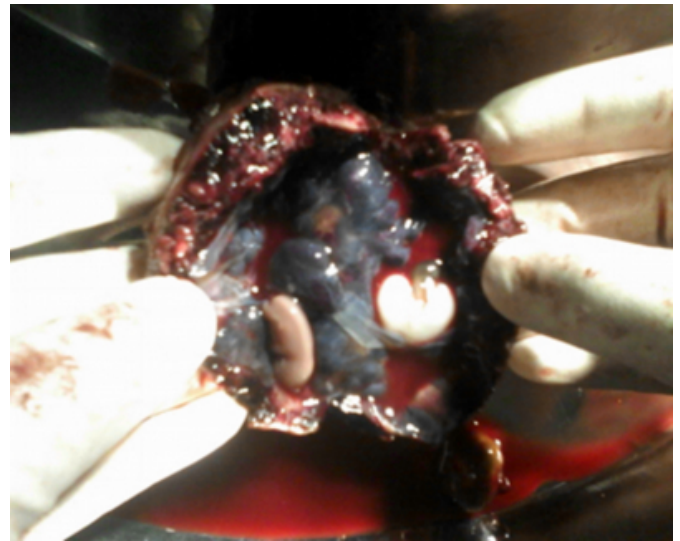
**Figure 2**

Fig. 2 Ruptured tube with sac lying outside



**Figure 3**

Fig.3 Cut section of sac showing 2 fetus



## DISCUSSION

The incidence of ectopic pregnancies has been increasing steadily since 1970s (4). Based on the changing pattern of clinical presentation, the gynecologist should pay special attention in suspected cases. All available methods of diagnosing should be used including ultrasonography and blood chemistry tests such as betahuman chorionic gonadotropin (hCG) level. There is evidence that the hCG level of twin tubal pregnancies is higher than that of a singleton tubal pregnancy (5) however in our case as it was a acute on chronic ectopic pregnancy urine pregnancy test was negative. Several factors are thought to increase the risk of ectopic pregnancy. Transvaginal ultrasonography is recommended for detailed evaluation of patient suspected of having ectopic pregnancies because of the superior resolution of uterine and adnexal structures.

In our case, the patient was symptomatic and transvaginal sonography has shown to be effective in the diagnosis of ruptured twin tubal pregnancy and extremely sensitive in the detection of free pelvic fluid. The pathogenesis of unilateral twin tubal pregnancy is not clear however several factors contribute to the occurrence of ectopic pregnancy. In the present case it was a spontaneous conception after tubal ligation.

Treatment of an ectopic pregnancy depends on its clinical presentation, size, and complications, and may entail conservative, medical, or surgical intervention. There are a few reports of successful laparoscopic management of ruptured tubal twin pregnancy and operative laparoscopic salpingostomy (6). However laparotomy was better for this

situation to control the bleeding point from the ruptured site.

Twin ectopic pregnancy, even though rare, must be looked for on ultrasound scanning, especially in suspected tubectomised patients, because of the potential mortality and morbidity associated with this condition.

### **CONCLUSION**

A spontaneous unilateral twin tubal pregnancy can occur in patients who have no known predisposing factor. Early diagnosis has made this disorder amenable to appropriate treatment. The high-resolution transvaginal sonography is very helpful in the diagnosis of this condition (15, 18).

### **References**

1. Atye, Lam SL. Clinics in diagnostic imaging (106). Viable left tubal twin ectopic pregnancy. Singapore Med J 2005; 46: 651-5.
2. Breen JL. A 21-year survey of 654 ectopic pregnancies. Am J Obstet Gynecol 1970; 106: 1004-19.
3. De Ott D. A case of unilateral tubal twin gestation. Annales de Gynecologie et d'Obstetrique. 1891;36:304.
4. Shwayder JM, Mahoney V, Bersinger DE. Unilateral twin ectopic pregnancy managed by operative laparoscopy. A case report. J Reprod Med. 1993;38:314-6.
5. Zakut H, Fiengold M, Lipnitzky W. Unilateral tubal pregnancy of twins. Clin Exp Obstet Gynecol 1983; 10: 157-8.
6. Gassibe EF, Gassibe E. Laparoscopic management of ruptured tubal twin pregnancy. J Am Assoc Gynecol Laparosc 1996; 3(4 Suppl): S15.

**Author Information**

**A Kakani.**

Associate Prof, Dept. of Obst. & Gynae, Acharya Vinoba Bhave Rural Hospital

**S Goel.**

Resident, Dept. of Obst. & Gynae, Acharya Vinoba Bhave Rural Hospital

**D Shrivastava.**

Prof., Dept. of Obst. & Gynae, Acharya Vinoba Bhave Rural Hospital

**V Shrivastava.**

Resident, Dept. of Radio Diagnosis, Acharya Vinoba Bhave Rural Hospital