

# Richter's Lymphoma of the Small Bowel

J McClenathan

## Citation

J McClenathan. *Richter's Lymphoma of the Small Bowel*. The Internet Journal of Surgery. 2012 Volume 28 Number 3.

## Abstract

When chronic lymphocytic leukemia (CLL) transforms into lymphoma, it is known as Richter's phenomenon or syndrome. In this article, we present a 73-year-old woman with CLL who was admitted for treatment of severe abdominal pain and free air. She had multifocal lymphoma and perforation of the jejunum.

## INTRODUCTION

Richter's syndrome is the development of or transformation to lymphoma in a patient with chronic lymphocytic leukemia. This is not a rare phenomenon, as it is reported to occur in 3-5% of patients with CLL. When it does occur, the patient generally develops a diffuse large B-cell lymphoma. Patients who develop a Richter's transformation usually develop lymphadenopathy, splenomegaly and hepatomegaly. They often have weight loss and fevers. It is quite rare for patients with a Richter's transformation to have gastrointestinal involvement with their lymphoma. Herein we report such a patient and summarize another 21 patients whose lymphoma involved the gastrointestinal tract.

## CASE REPORT

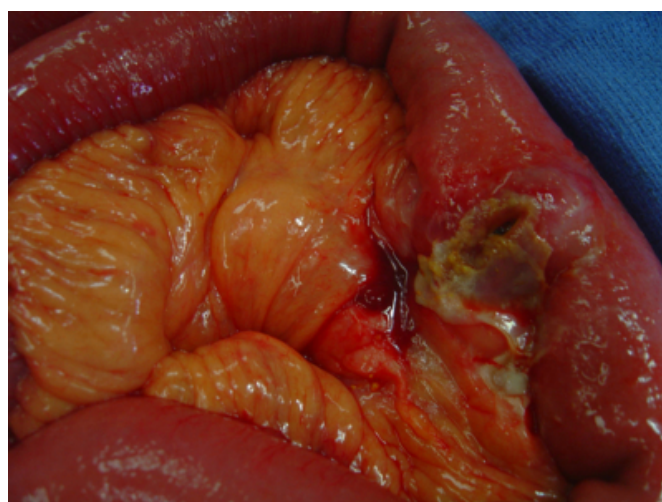
A 73-year-old woman was treated for severe abdominal pain of three days duration. Physical examination revealed that she had findings of an acute abdomen. Her past history included the fact that she had chronic lymphocytic leukemia for which she had not received treatment during the previous fourteen years. CT scan showed three findings. First, she had free air. Second, she had several loops of thickened small intestine. Third, she had extensive mesenteric and retroperitoneal lymphadenopathy. Based on these findings, she was suspected of having lymphoma of the small bowel with perforation.

At laparotomy, she had resection of three segments of jejunum involved with tumor. Two different segments were perforated (Figure 1). Three days after her operation she was transferred to a nearby hospital where her aggressive lymphoma was treated. Pathologic examination showed that she had a diffuse, large B-cell lymphoma. A small focus of low-grade CLL was found remotely in a segment of resected bowel. Numerous immunohistochemical stains confirmed

that the patient had both CLL and the Richter transformation.

## Figure 2

Table 1



## DISCUSSION

The transformation of chronic lymphocytic leukemia (CLL) into a diffuse large-cell lymphoma is known as Richter's syndrome. It is thought to occur in less than five percent of patients with CLL. When reviewed by Parents in 2001, only 16 patients were known to have Richter's lymphoma of the gastrointestinal tract. (1) Originally described in 1928, Richter described a patient whom he thought had longstanding CLL who then developed a rapidly growing malignant tumor that also arose from the lymphatic system. (2) Autopsy findings in his patient included involvement of the ileum by the more malignant pattern of cells. The transformation of chronic lymphocytic leukemia into a more aggressive lymphoma is now known as Richter's syndrome. This transformation is thought to occur in only 3-5% of

patients with CLL. (1) When Richter's transformation to lymphoma does occur, it involves the gastrointestinal tract only rarely. Table 1 summarizes 21 additional patients with Richter's involvement of the gastrointestinal tract that we are aware of. (1-13) Eleven patients had involvement of the stomach. Seven patients had involvement of the small intestine. Four patients had involvement of the colon or rectum. Twice, the site of involvement was described only as gastrointestinal. Three patients presented with perforation, two in the small bowel and one in the stomach. Other presentations included bleeding, pain and obstruction. The patients ranged in age from 46-83 years. Thirteen were men and eight were women. The time from diagnosis of leukemia to transformation ranged from simultaneous to 14 years. At the time of diagnosis of high-grade lymphoma, white blood count ranged from 7,800 to 200,000, and the percentage of lymphocytes was usually more than 60%.

The descriptions of surgical management in the cases reviewed were brief. Some were discovered at autopsy. Some were only biopsied and others had partial resection. Resection was mentioned in several of the gastric lymphomas and one rectal tumor. In our own patient, three small-bowel resections were done, but the patient had obvious mesenteric and retroperitoneal disease, which was not removed. The primary care of these patients should be with chemotherapeutic agents. Our own patient was transferred to the care of her hematologist, who had cared for her CLL, three days after her operation.

{image:2}

### References

1. Parrens M, Sawan B, Dubus P, Lacombe F, Marit G, Vergier B, Reiffers J, de Mascarel A, Merlio JP: Primary digestive Richter's syndrome. *Mod Pathol*; 2001; 14(5): 452-7.
2. Richter MN: Generalized reticular cell sarcoma of lymph nodes associated with lymphatic leukemia. *Am J Pathol*; 1928; 4(4): 285-292.
3. Givler RL: Lymphocytic leukemia with coexistent localized reticulum cell sarcoma. *Cancer*; 1968; 21(6): 1184-92.
4. Armitage JO, Dick FR, Corder MP: Diffuse histiocytic lymphoma complicating chronic lymphocytic leukemia. *Cancer*; 1978; 41(2): 422-7.
5. Trump DL, Mann RB, Phelps R, Roberts H, Conley CL: Richter's syndrome: diffuse histiocytic lymphoma in patients with chronic lymphocytic leukemia. A report of five cases and review of the literature. *Am J Med*; 1980; 68(4): 539-48.
6. Foucar K, Rydell RE: Richter's syndrome in chronic lymphocytic leukemia. *Cancer*; 1980; 46(1): 118-34.
7. Brousse N, Solal-Celigny P, Herrera A, Breil P, Molas G, Flejou JF, Boivin P, Potet F: Gastrointestinal Richter's syndrome. *Hum Pathol*; 1985; 16(8): 854-7.
8. Jasani B, Gough J, Myers K, Wells AL: Gastrointestinal Richter's syndrome. *Hum Pathol*; 1986; 17(11): 1184.
9. Wilson JA: Richter's syndrome mimicking chronic colitis. A patient with diffuse histiocytic lymphoma complicating chronic lymphocytic leukemia. *Dis Colon Rectum*; 1986; 29(3): 191-5.
10. Desablens B, Gineston JL, Joly JP, Piprot-Choffat C, Sevestre H, Capron JP: Immunoblastic lymphoma of the ileocecal region in chronic lymphoid leukemia. Richter's syndrome localized in the intestine and disclosed by ascites. *Gastroenterol Clin Biol*; 1987; 11(12): 901-3.
11. Monforte R, Feliu E, Campo E, Llebaria C, Montserrat E, Vives-Corrons JL, Rozman C: Intestinal lymphoma in a patient with chronic lymphocytic leukemia of atypical phenotype: Richter's syndrome of unusual presentation. *Acta Haematol*; 1988; 80(2): 116-9.
12. Ott MM, Ott G, Roblick U, Linke B, Kneba M, de Leon F, Müller-Hermelink HK: Localized gastric non-Hodgkin's lymphoma of high-grade malignancy in patients with pre-existing chronic lymphocytic leukemia or immunocytoma. *Leukemia*; 1995; 9(4): 609-14.
13. Chacaltana Mendoza A, Espinoza Garcia J: Richter's syndrome in colon: Case Report. *J Gastrointest Cancer*; 2012; 43(2): 358-60.

**Author Information**

**James McClenathan, MD**

Associate Professor of Clinical Surgery, South Campus Hospital, University of Arizona