

Spontaneous Rupture Of An Intra-Abdominal Testicular Tumor: A Case Report

N Kumar, B Rehmani

Citation

N Kumar, B Rehmani. *Spontaneous Rupture Of An Intra-Abdominal Testicular Tumor: A Case Report*. The Internet Journal of Surgery. 2012 Volume 28 Number 3.

Abstract

The rupture of an intra-abdominal testicular tumor is a rare cause of acute abdomen with haemoperitoneum. We report a case of a 25-year-old male presenting with acute abdomen with haemoperitoneum caused by the rupture of intra-abdominal a non-seminomatous, mixed germ cell testicular tumor (NSMGCT), a predominantly yolk sac tumor and embryonal carcinoma in an undescended testis. The clinical details and difficulties in diagnosis of this testicular tumor are discussed.

INTRODUCTION

Cryptorchidism is a developmental defect in which the testes fail to descend completely into the scrotum. Isolated cryptorchidism affects 3% of full-term male newborns. True undescended testis is unilateral in 80% cases. Approximately 70-77% of cryptorchid testes will spontaneously descend, usually by 3 months of age. [1, 2]. Approximately 10% of testicular tumors arise from undescended testes. The higher the position of an undescended testis, the greater is the risk for development of malignancy. Almost half of the tumors that occur in testes are located abdominally, with 6-fold higher frequency than in an inguinal testis. The most common tumor that develops from the cryptorchid testis is the seminoma. Complications of intra-abdominal testis such as torsion, rupture and bleeding are rare. We describe a case of non-seminomatous mixed germ cell testicular tumor, predominantly yolk sac tumor and embryonal carcinoma that has developed in a left cryptorchid testis and ruptured intra-abdominally causing massive bleeding.

CASE REPORT

A 25-year-old male presented with pain in the left lower abdomen for 7 days, associated with lower abdominal distension for 4 days. On admission, his pulse rate was 110 beats/minute and his blood pressure was 120/80mmHg. His abdomen was mildly distended and soft, with tenderness only in the left iliac fossa (LIF) and no guarding; liver dullness and bowel sounds were also present. The patient had a left undescended testis and a normally descended right testis. After this finding, a reexamination of the patient's history revealed that he had untreated cryptorchidism on the

left-side since childhood and infertility. Lab findings were as follows; Hb 8.75g%, TLC 20800/cu mm and the rest of the CBC and biochemical examination was normal. An X-ray of the chest (erect PA view) did not show any free gas under the right dome of the diaphragm. Ultrasonography of the abdomen was suggestive of a well defined hypo-echoic solid mass lesion in the LIF with ascites. A CT scan of the abdomen was performed; the results suggested haemoperitoneum with left testicular mass. Then, in view of testicular tumor on the left undescended testis, serum tumor markers were done, which showed an increase in AFP (Alpha-fetoprotein, 484.24ng/ml) and normal B-HCG (2.0 ml U/L) and LDH (187 U/L). The patient was initially managed conservatively, but his condition did not improve. Exploratory laparotomy was done on the third day of admission and, at laparotomy, 2000ml of blood was found in the abdominal cavity, along with a shattered testicular mass in the left lower abdominal cavity near the sigmoid colon, extending up to the left deep inguinal ring with a normal spermatic cord. After excision of the mass, complete abdominal exploration was done and no other mass or suspicious lymph nodes were found. The excised mass was sent for histopathological examination (HPE). The postoperative period was uneventful. HPE revealed a non-seminomatous mixed germ cell tumor (predominantly a yolk sac tumor and embryonal carcinoma). The patient was put on adjuvant chemotherapy with two cycles of bleomycin, etoposide (500mg/m²/cycle) and cisplatin.

Figure 1

Fig. 1: CECT of the abdomen showing haemoperitoneum

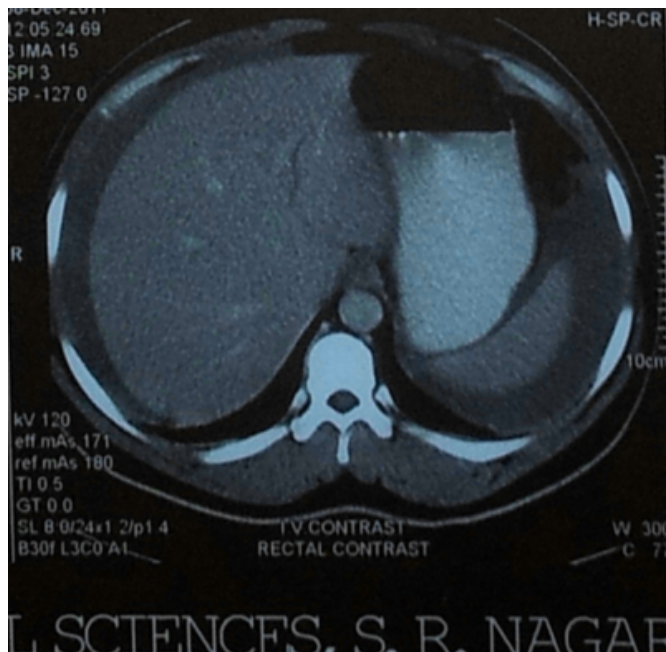
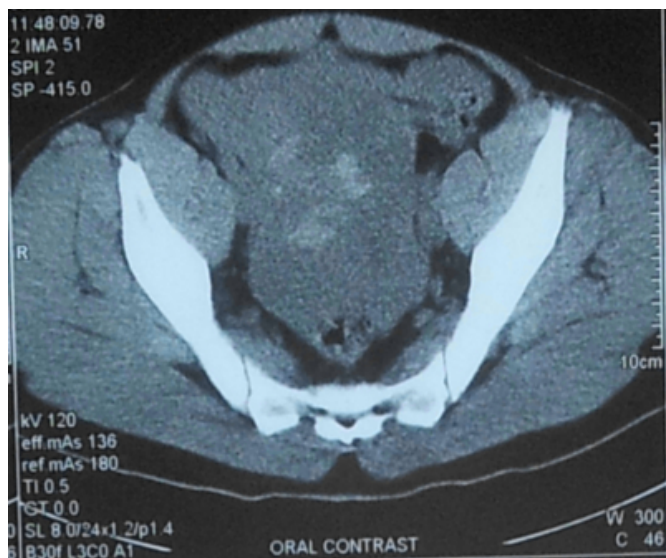

Figure 2

Fig. 2: CECT of the abdomen showing haemoperitoneum with the hypodense mass on the left



DISCUSSION

Approximately 10% of testicular tumors arise from undescended testes, and the risk of developing a germ cell tumor when a cryptorchid testis is intra-abdominal is about 5%. [6]. The higher the position of undescended testis from the scrotum, the greater is the risk for development of malignancy. In mixed groups of men treated for cryptorchidism, the risk is typically 3.6 to 7.4 times higher than in the general population. The incidence curve increases

steeply after the onset of puberty, and occurrences are most frequent in men in their 20s and 30s; 50% are diagnosed before the age of 35. While orchidopexy improves fertility, it does not alter the risk of developing carcinoma. Rather, it allows clinical surveillance of patients with a previously impalpable gonad [1,2,4]. The most common tumor that develops from the cryptorchid testis is seminoma. Ultrasonography, magnetic resonance imaging, computed tomography and Gallium scanning are usually used in the monitoring of an intra-abdominal testis. [4].

Our case presented a rare mixed yolk sac tumor and embryonal cell carcinoma in a left undescended testis in an adult. The pure yolk sac tumor is the most common testicular tumor of infants and children. It is extremely rare in postpubertal males. In adults, it occurs most frequently in combination with other histologic types and is presumably responsible for the production of AFP. Serum tumor markers; HCG and AFP are important for diagnosis, prognosis and follow-up. If the AFP level does not return to normal post orchiectomy, metastatic disease must be suspected. [5] Lymphatic spread is common to all germ cell testicular tumors except pure choriocarcinoma which disseminates by vascular invasion.

Patients presenting with non-seminomatous germ cell tumor (NSGCT) are subdivided into low and advanced stage disease. Patients with low stage NSGCT may be candidates for surveillance, chemotherapy or retroperitoneal lymph node dissection (RPLND), depending upon clinical staging, serum tumor markers and tumor histological findings. On the other hand, patients with advanced disease are further sub-categorized into good and poor risk categories and are then subjected to primary chemotherapy depending on the nature of their disease. Adjuvant chemotherapy with two cycles of bleomycin, etoposide (500mg/m²/cycle) and cisplatin is recommended. [9]

Acute abdomen and massive bleeding is a very rare presentation in cryptorchid testicular tumor with two cases of ruptured intra-abdominal seminoma reported in the literature [7, 8]. To our knowledge, acute abdomen with haemoperitoneum caused by intra-abdominal rupture of a non-seminomatous mixed germ cell tumor is a very rare presentation in cryptorchid adult males.

References

1. Fonkalsrud EW: Current management of undescended testes. *Semin Pediatr Surg*; 1996; 5: 2-7.
2. Cortes D: Cryptorchidism - aspects of pathogenesis, histology and treatment. *Scand J Urol Nephrol Suppl*; 1998;

196: 1-54.

3. Cortes D, Thorup J, Petersen BL: Testicular neoplasia in undescended testes of cryptorchid boys - does surgical strategy have an impact on the risk of invasive testicular neoplasia? *Turk J Paediatr* 2004; 46 (supplement): 35-42.

4. Fritzsche PJ, Hricak H, Kogan BA, Winkler ML, Tanagho EA: Undescended testes; value of MR imaging. *Radiology*; 1987; 164: 169-173.

5. Kaplan GW, Cromie WC, Kelalis PP, Silver I, Tank ES Jr.: Prepubertal yolk sac testicular tumor registry. *J Urol*; 1988; 140: 1109-12.

6. Bosl GJ, Motzer RJ: Testicular germ cell cancer. *N Engl J Med*; 1997; 337: 242-253.

7. Watkins GL: Massive haemoperitoneum resulting from rupture of seminoma in an undescended testicle. *J Urol*;

1970; 103: 447-448.

8. Küçük HF, Dalkilic G, Kuroglu E, Altuntas M, Barisik NO, Gülmen M: Massive bleeding caused by rupture of intra-abdominal testicular seminoma: case report. *J Trauma*; 2002; 52:1000-1001.

9. Hotte S, Mayhew LA, Jewett M, Chin J, Winkquist E, and Members of the Genitourinary Cancer Disease Site Group: Management of stage I nonseminomatous testicular cancer: guideline recommendations. A quality initiative of the Programme in Evidence-Based Care (PEBC), Cancer Care Ontario (CCO) 2008. Evidence-Based Series #3-19: Section 1, 2, 3; available on the CCO website <http://www.cancercare.on.ca/toolbox/qualityguidelines/diseasesite/genito-ebs/>

Author Information

Navin Kumar, MBBS, MS

Assistant Professor, Himalayan Institute of Medical Sciences

Babar Rehmani, MBBS, MS

Associate Professor, Himalayan Institute of Medical Sciences