

Testicular Kaposiform Hemangioendothelioma Of An 80-Year-Old: A Case Report And Literature Review.

J Manwaring, A Luchey, J Hakim, S Zaslau

Citation

J Manwaring, A Luchey, J Hakim, S Zaslau. *Testicular Kaposiform Hemangioendothelioma Of An 80-Year-Old: A Case Report And Literature Review..* The Internet Journal of Urology. 2012 Volume 9 Number 3.

Abstract

Kaposiform hemangioendothelioma (KHE) is a rare vascular tumor of low or intermediate malignant potential most often appearing in the extremities or retroperitoneum in infants and children. Vascular tumors such as KHE are sometimes complicated by consumptive coagulopathy, a condition termed Kasabach-Merritt phenomenon (KMP). KHE presentation in adults is extremely rare, and to our knowledge, has never been reported in an individual over 75 years old, nor in the male genitalia. This article describes the case of an 80-year-old white male with KHE presenting as a testicular mass.

INTRODUCTION

KHE is a rare vascular tumor occurring primarily in children and most often found in the limbs or retroperitoneum. In the literature, Kaposiform Hemangioendothelioma (KHE), a rare vascular tumor, has mainly been reported in the limbs or retroperitoneum of children.^{1,2} KHE was first described by Zukerberg et. al in 1993, however, tumors with descriptions suggestive of KHE have been reported previously.³ These cases included patients from neonate to 2 ½ years old of various races with retroperitoneal/peritoneal hemangioendotheliomas.⁴⁻⁷ Microscopic examination of tumor biopsies in each of these cases revealed slit-like vascular channels surrounded by flattened or spindle-shaped cells. KHE grossly and microscopically resembles characteristics of Kaposi sarcoma and must be differentiated from other vascular tumors. Fortunately, a combination of unique biochemical characteristics, distinct pathologic findings, and certain clinical clues enable KHE to be identified with confidence. As of 2009, fewer than 170 cases of KHE had been reported with less than 20 occurring in adults.²

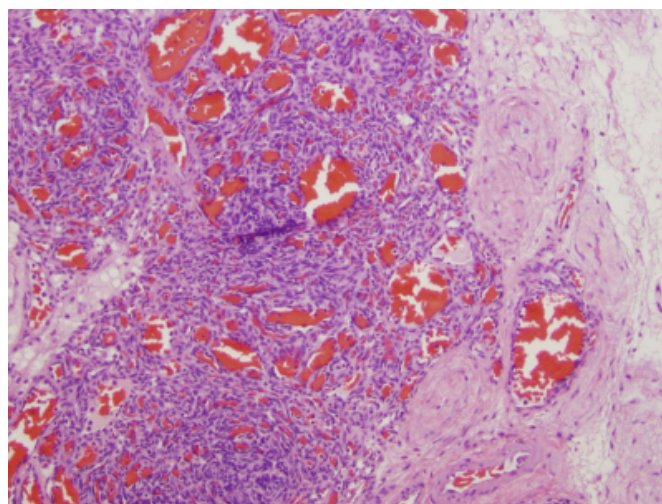
REPORT OF CASE

The patient is an 80-year-old Caucasian male that initially presented with a one month history of left scrotal swelling and was found by scrotal ultrasound to have a testicular tumor with an associated hydrocele. His urological history is significant for neurogenic bladder. He underwent a left radical orchiectomy with final pathology of Kaposiform

hemangioendothelioma. Figure 1 represents a low power view of the tumor with Hematoxylin and Eosin stain.

Figure 1

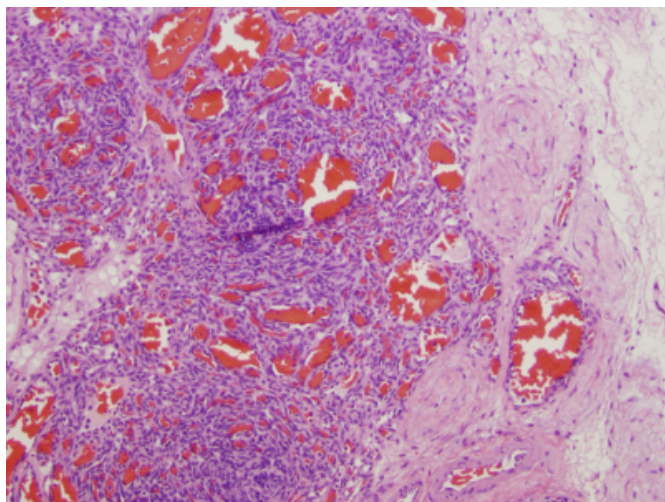
Figure 1: Low power view of tumor. Numerous vascular channels are present and appear slit-like. Lack of atypia and mitotic figures can be appreciate even at high power.



In figure 2, a high power view reveals that atypia and mitotic figures are not seen. Tumor cells appear well differentiated. Slit like vascular channels are present. Spindle shaped cells appear flattened.

Figure 2

Figure 2: High Power view of Kaposiform hemangioendothelioma. Cells appear uniform and the absence of mitotic figures and atypia are noted.



The lesion was limited to the testicle and no further therapy was indicated. At his one month post-operative visit he was found to have gradual left scrotal swelling and denied any anorexia, fever, weight loss, or bone pain. A scrotal ultrasound revealed a 5 x 6.5 x 7 cm complex fluid collection occupying the left hemiscrotum. A CT of the abdomen and pelvis with and without contrast and a chest x-ray did not demonstrate any grossly metastatic or obvious disease. He is doing well at 6 month follow up.

DISCUSSION

KHE has a low metastatic potential but can be locally aggressive². Vascular tumors including KHE are sometimes complicated by consumptive coagulopathy, a condition termed Kasabach-Merritt phenomenon (KMP). Definitive treatment is surgical removal. When surgery is not an option, a number of medical therapies have been tried with varying degrees of success. These agents include corticosteroids, interferon alpha, and vincristine². This rare tumor more commonly presents in infants and children and is most often found retroperitoneally or in the superficial tissues of the limbs, but a growing body of case reports demonstrates that this tumor has the potential, albeit rare, to arise in a large variety of organs and tissue types.

In order to properly identify KHE lesions and differentiate them from other similar vascular lesions, a combination of pathologic findings and biochemical markers can be used. A

variety of endothelial and lymphatic markers have been found to be expressed on KHE cells including CD31, CD34, LYVE-1, podoplanin, Prox1⁹, VEGFR-2, VEGFR-3¹⁰, D2-40¹¹, and vimentin¹². Importantly, KHE is seen to lack HHV-8 DNA and PAS-positive globules (seen in Kaposi sarcoma) and GLUT-1 (seen in infantile hemangiomas). Microscopic examination of the KHE tumor will fail to show the cellular atypia and frequent mitotic figures observed in Kaposi sarcoma.

CONCLUSION

This report presents, to our knowledge, the oldest patient to present with a KHE lesion in addition to being the only instance of testicular KHE reported to date. This highlights the possibility of KHE presentation in the elderly population and in unexpected locations, as well as expands the differential diagnosis for a testicular mass.

References

1. Sidbury R. Update on Vascular Tumors of Infancy. *Curr Opin Pediatr*. 2010;22(4):432-7.
2. Fernández Y, Bernabeu-Wittel M, García-Morillo JS. Kaposiform Hemangioendothelioma. *Eur J Intern Med*. 2009;20:106-13.
3. Zukerberg LR, Nickoloff BJ, Weiss S.W. Kaposiform hemangioendothelioma of infancy and childhood: an aggressive neoplasm associated with Kasabach-Merritt syndrome and lymphangiomatosis. *Am J Surg Pathol*. 1993;17:321-328.
4. Al-Rashid RA. Cyclophosphamide and radiation therapy in the treatment of hemangioendothelioma with disseminated intravascular clotting. *Cancer*. 1971;27:364-8.
5. Pearl GS, Matthews WH. Congenital retroperitoneal hemangioendothelioma with Kasabach-Merritt syndrome. *South Med J*. 1979;72:239-40.
6. Niedt GW, Greco MA, Blanc WA, Knowles DM. Hemangioma with Kaposi's sarcoma-like features. *Pediatr Pathol*. 1989;9:567-75.
7. Tsang WYW, Chan JKC. Kaposi-like infantile hemangioendothelioma: distinctive vascular tumor of the retroperitoneum. *Am J Surg Pathol*. 1991;25:982-9.
8. Le Huu AR, Jokinen CH, Rubin BP, Mihm MC, Weiss SW, North Pew Dadras SS. Expression of prox1, lymphatic endothelial nuclear transcription factor, in Kaposiform hemangioendothelioma and tufted angioma. *Am J Surg Pathol*. 2010 Nov;34(11):1563-73.
9. Saito M, Gunji Y, Kashii Y, et al. Refractory Kaposiform Hemangioendothelioma That Expressed Vascular Endothelial Growth Factor Receptor (VEGFR)-2 and VEGFR-3. *J Pediatr Hematol Oncol*. 2009 Mar;31(3):194-7.
10. Tamai N, Hashii Y, Osuga K, et al. Kaposiform hemangioendothelioma arising in the deltoid muscle without the Kasabach—Merritt phenomenon. *Skeletal Radiol*. 2010;39:1043-46.
11. Yu L, Yang SJ. Kaposiform hemangioendothelioma of the spleen in an adult: an initial case report. *Pathol Oncol Res*. 2011 Dec;17(4):969-72.

Author Information

Jared Manwaring, BA

Medical Student, School of Medicine, West Virginia University

Adam Luchey, MD

Chief Resident, Division of Urology, West Virginia University

Jonathan Hakim, MD

Staff Urologist, War Memorial Hospital

Stanley Zaslau, MD

Chief, Division of Urology, West Virginia University