

# Role Of Ultrasonography And Orchidopexy In Undescended Testis In Semi Urban Setting Of A Developing Country

S JADHAV, P KUMAR

## Citation

S JADHAV, P KUMAR. *Role Of Ultrasonography And Orchidopexy In Undescended Testis In Semi Urban Setting Of A Developing Country*. The Internet Journal of Urology. 2013 Volume 11 Number 1.

## Abstract

Cryptorchidism is one of the most common congenital anomalies of the genito-urinary tracts in males. Cryptorchidism or Undescended testis is a developmental defect in which there is failure of the testis to descend in to the scrotum<sup>1</sup>. Cryptorchidism is a rare condition, occurring between 0.7% and 2% of children over one year of age<sup>2</sup>. The abnormality assumes particular importance in cases of bilateral undescended testis, where correct diagnosis and timely treatment can save patient from lifelong misery of sterility. In unilateral cases treatment is directed to prevent complications known to be associated with undescended testis (UDT) <sup>1</sup>. Incidence of testicular cancers in cryptorchid patients is estimated to be 3-5 times higher than in the general population<sup>3</sup>. Ultrasonography (USG) is exceptionally well suited to study of scrotum and its contents. Sonography is simple to perform, rapid, non-invasive relatively inexpensive, easily reproducible, widely available and does not involve irradiation of gonads. Ultrasonography, an efficient and easy investigation, is used as a first line diagnosis in undescended testis<sup>4</sup>. Surgery for undescended testis is indicated to reduce the chances of infertility, malignant degeneration, strangulation of associated hernias and torsion. It also helps increase the chances of early detection of malignancy and other testicular complication. Besides, it avoids psychosocial problems associated with an empty scrotum in later life<sup>5</sup>.

The current study is being carried out to analyze the reliability of Ultrasonography in identification of undescended testis and the efficacy of orchidopexy in surgical management of undescended testis in developing country like India where these services are easily and practically accessible.

## INTRODUCTION

Cryptorchidism is one of the most common congenital anomalies of the genito-urinary tracts in males. Cryptorchidism or Undescended testis is a developmental defect in which there is failure of the testis to descend in to the scrotum<sup>1</sup>. Cryptorchidism is a rare condition, occurring between 0.7% and 2% of children over one year of age<sup>2</sup>. The abnormality assumes particular importance in cases of bilateral undescended testis, where correct diagnosis and timely treatment can save patient from lifelong misery of sterility. In unilateral cases treatment is directed to prevent complications known to be associated with undescended testis (UDT) <sup>1</sup>. Incidence of testicular cancers in cryptorchid patients is estimated to be 3-5 times higher than in the general population<sup>3</sup>. Ultrasonography (USG) is exceptionally well suited to study of scrotum and its contents. Sonography is simple to

perform, rapid, non-invasive relatively inexpensive, easily reproducible, widely available and does not involve irradiation of gonads. Ultrasonography, an efficient and easy investigation, is used as a first line diagnosis in undescended testis<sup>4</sup>.

Surgery for undescended testis is indicated to reduce the chances of infertility, malignant degeneration, strangulation of associated hernias and torsion. It also helps increase the chances of early detection of malignancy and other testicular complication. Besides, it avoids psychosocial problems associated with an empty scrotum in later life<sup>5</sup>.

The current study is being carried out to analyze the reliability of Ultrasonography in identification of undescended testis and the efficacy of orchidopexy in surgical management of undescended testis in developing country like India where these services are easily and practically accessible.

## **AIMS AND OBJECTIVES**

To study the accuracy of ultrasonography in localization of the undescended testis.

To study the efficacy of “Orchidopexy” in surgical management of undescended testis.

## **MATERIALS AND METHODS**

This is a prospective study carried out at Padmashree Dr. D. Y. Patil Medical College, Hospital and Research Centre, Pune, Maharashtra, India from July 2010 to September 2012. Institutional Ethics Committee Clearance was obtained before start of study and written informed consent for the procedure was obtained from adult patient. In case of children, parents consent was taken. The study population included thirty four (34) patients with undescended testis presenting to the surgery out patient department between age of one month to fifteen years. Ultrasonographically detected intra abdominal testis were not included in our study. All patients were examined in a systematic order as mentioned in the proforma.

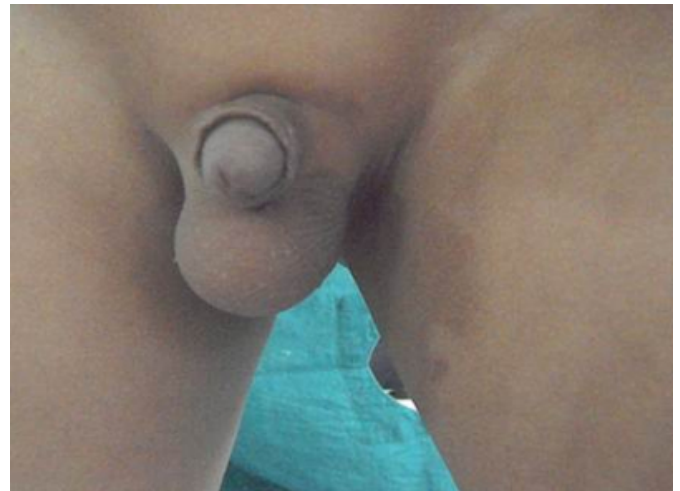**Figure 1**

Right sided undescended testis



**Figure 2**

Left sided undescended testis



The position of testis was confirmed with Ultrasonography abdomen, pelvis and scrotum by using linear array transducer of 7-12 MHz on ACUSON X300 and ACUSON ANTARES machines.

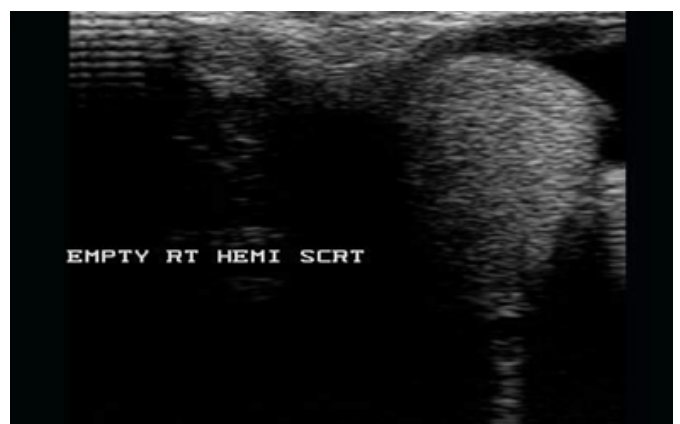### **SCANNING TECHNIQUE**

Scanning was routinely performed in supine position. Both hemiscrotums were examined in transverse, sagittal and oblique planes. Additional scans of spermatic cord in region of scrotal neck and inguinal canal region were obtained in special circumstances: Inguinoscrotal hernias and encysted hydrocele of cord.

The position of testis found on the operation table was taken as the marker of accuracy of ultrasound.

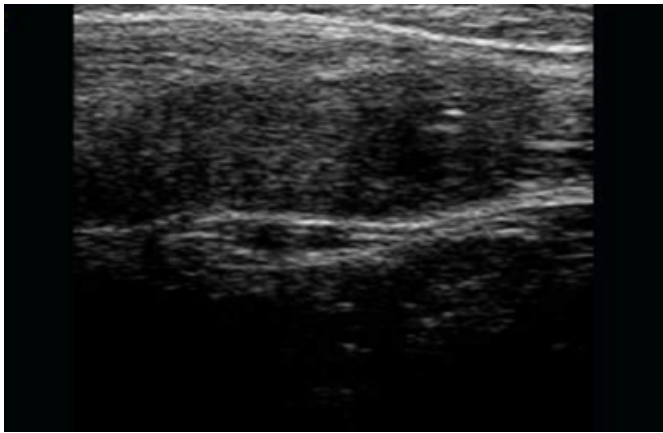
**Figure 3**

Transverse US image showing left testis and empty right scrotal sac.



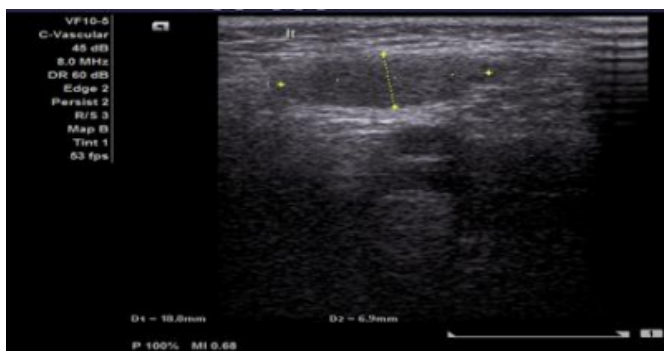
**Figure 4**

Longitudinal US image shows right testis in the inguinal canal.



**Figure 5**

Shows Left testis at deep inguinal ring



Surgical management of undescended testis was done by orchidopexy.

#### ORCHIDOPEXY

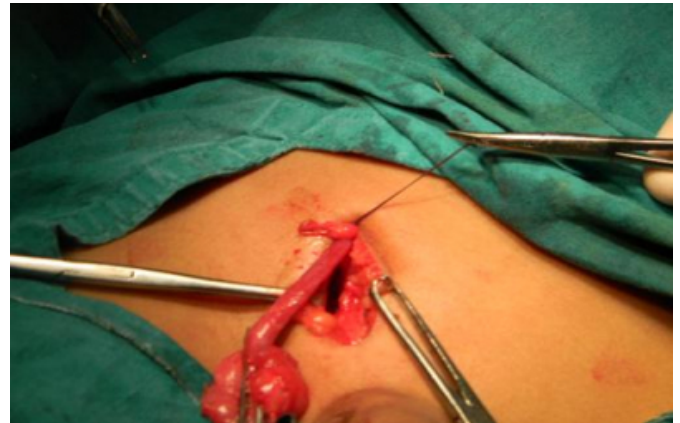Inguinal canal accessed through an adequately sized inguinal crease incision. The external oblique fascia cut and opened through the external ring. Inguinal testis identified. The gubernacular attachment is divided. Processus vaginalis is separated from the vas and vessels. The testis is mobilized from its attachment and adhesions along with the cord for sufficient length so as to bring it to the scrotum without tension on the vessels. Once the testis is mobilized a traction stitch is placed through the tunica so that, the testis can be pulled down to the scrotum for fixation. The method of fixing the testis in its scrotal bed is to pass a stitch through the tunica albuginea at the lower pole of the testis and to bring this out through the bottom of the scrotum to anchor it to the skin by tying it over a piece of gauze. The stitch was kept in position for 10 days and then removed.

All patients were observed in the postoperative period, and

complications, if any had been noted. All patients followed up after three weeks, three months and six months.

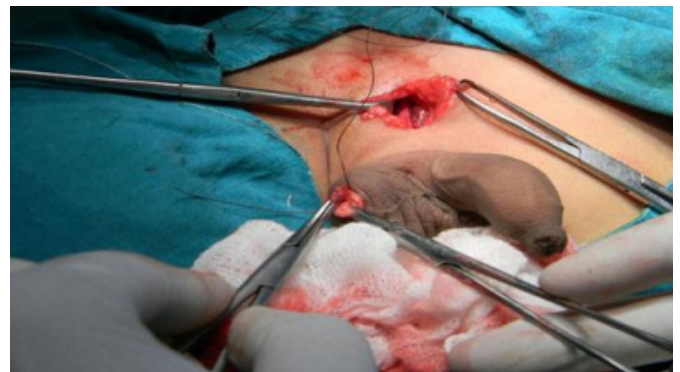**Figure 6**

Shows mobilized of testis from its attachment and adhesions along with the cord for sufficient length so as to bring it to the scrotum without tension on the vessels.



**Figure 7**

Shows traction stitch through the tunica so that, the testis can be pulled down to the scrotum for fixation.



#### OBSERVATIONS AND RESULTS

Wide variations were seen in our study of 34 cases. No patients presented between 0 to 6 months of age, sixteen (47.5%) cases between 6 months to 2 years of age, eleven (32.5%) between 2 to 5 years of age, seven (20%) cases between 5 to 15 years of age.

In our study, twenty one (62%) patients presented with palpable testis whereas thirteen (38%) patients presented with impalpable testes.

Our study reported 17 (50%) cases of right sided undescended testis, 11 (32.5%) cases of left sided undescended testis and 6 (17.5%) cases of bilateral undescended testis.

In terms of location, 16(47%) testes were at inguinal canal,

10(29.5%) were at superficial ring, and 8 (23.5%) at deep ring . In our study ultrasonography was performed in all patients who presented with undescended testis. USG located testis in 34 patients i.e 100% sensitivity and specificity. Out of 34 cases of undescended testis, we performed subdartos pouch orchidopexy in all the patients. Post operatively three patients (9%) presented with surgical site infection.

**Table 1**

Ultrasonographic location of testis compared with intraoperative location

	ULTRASONOGRAPHIC LOCATION OF TESTIS	INTRAOPERATIVE LOCATION OF TESTIS
Inguinal canal	16	16
At Superficial ring	10	10
At Deep ring	8	8
Total	34	34

**Table 2**

Post operative complications

	NUMBER OF PATIENTS	PERCENTAGE
Wound infection	3	9%
Hematoma	0	0
Torsion	0	0
Retraction of testis	0	0
Atrophy of testis	0	0

## DISCUSSION

The testis develops intra abdominally and moves toward the scrotum during fetal development. Undescended testis also known as cryptorchidism, the condition in which the testis fails to reach the scrotum . The descent may be arrested at any levels along the path from the retroperitoneum to the scrotum. The condition is associated with complications such as testicular malignancy, sub fertility, torsion and inguinal hernia if not corrected early<sup>6</sup>.

Undescended testis is a condition of great concern to surgeons and urologists owing to the risk of impaired spermatogenesis and consequent infertility later in life. The risk of testicular cancer gave a history of cryptorchidism, even though there appears to be no conclusive proof that correction of cryptorchidism protects against cancer, but

renders testis easily accessible<sup>7</sup>. It has been shown that fertility after treatment for unilateral undescended testis is about 84%, bilateral 60% and overall 79%. Hence, need for early diagnosis and surgical treatment is necessary<sup>8</sup>.

The status of undescended testis may include a testis of normal size, abnormally enlarged testis like tumour or torsion, atrophic testis or vanished testis. According to our study we performed ultrasonography in all the patients with undescended testis and location , site, is confirmed and surgically treated by orchidopexy.

Current evidence based studies indicate that early intervention for an undescended testis may improve fertility<sup>9</sup> and decrease the risk of testicular cancer<sup>10</sup>. Therefore the current recommended age for orchidopexy is between 6 and 12 months of age<sup>11-12</sup>.

Unfortunately our data showed that there is a significant delay in referral of patients with an undescended testis either because the condition was not identified early or the parents of the patients failed to seek proper surgical advice due to fear of surgery and ignorance as is common in rural areas of developing countries like India . This resulted in a significant delay in the timing of orchidopexy, shifting the average age of surgical intervention towards 1 to 5 years.

This average age is consistent with the average age at orchidopexy observed in other studies<sup>13-15</sup>, indicating the need for proper health awareness.

It is imperative that proper examination of male genitalia is carried out soon after birth as well as during the early immunization schedule and if any suspicion of an undescended testicle , the child should be referred to a specialist surgeon for further assessment and follow up<sup>16</sup>. In rural and semi-rural pockets of developing countries like India, availability, access and training in sonography and orchidopexy is fairly good which can be an early implementable method with good results as shown in this study.

## CONCLUSIONS

In our study the maximum number of cases were recorded between 6 months to 5 years of age Right sided undescended testis is commoner presentation.

Ultrasonography remains the specific easily available non-invasive modality of diagnosis and localisation.

Orchidopexy is the most common technique for placement of undescended testis in the

scrotum with low complication rate and high success rate.

## References

1. Francis X Schneck, MD, Mark F Bellinger MD. The Undescended Testis. *Campbell's Urology*. 2006; 8(3): 2353-93.
2. Dr. Jaime F. Perez Nino et al. Clinical Practical Guidelines Evidence Based Undescended Testicle. *Colombian Uro J* 2002.
3. Salehian MT et al. Testicular tumor associated with a history of contralateral undescended testis. *Int J Endocrinol Metab* 2005; 4: 199-201.
4. Vikram S. Dogra, MD et al. Sonography of the Scrotum. *J Radiology* 2003; 227 (1) :18 - 36.
5. Christine JP Bruijnen et al. Age at Orchidopexy as an indicator of the quality of regional child health services. *Journal of Paediatrics and Child Health* July 2012; 48 (7) : 556-559.
6. S Boopathy vijayaraghavan. Sonographic localization of nonpalpable testis : Tracking the cord technique *Indian J Radio Imaging*. 2011; 21(2):134-141.
7. E.A. Ameh, H.N. Mbibu. Management of Undescended Testis in Children in Zaria, Nigeria. *East African Medical Journal* 2000 ; 77 (9).
8. Kumar D., Bremner D.N., Brown P. W. Fertility after orchidopexy for cryptorchidism: a new approach to assessment. *Brit. J. Urol*. 1993; 73: 516 – 520.
9. Murphy F , Sri Paran T, Puri P. Orchidopexy and its impact on fertility. *Pediatr Surg Int* 2007; 23 :625-632.
10. Andreas Petterson, M.D., et al. Age at surgery for undescended testis and risk of Testicular cancer *N Eng J Med* 2007 ; 356 : 1835-1841.
11. European Association of Urology guidelines 2007 <http://www.uroweb.org>.
12. American Academy of Pediatrics, Section on Urology. Timing of elective surgery on the genitalia of male children with particular reference to the risks, benefits, and psychological effects of surgery and anesthesia. *Paediatrics* 1996; 97 : 590-594.
13. McCabe JE, Kenny SE. Orchidopexy for undescended testis in England; is it evidence based? *J Ped Surg* 2008; 43: 353-357.
14. Bonney T, Southwell B, Donnath S, Newgreen D, Hutson J. Orchidopexy trends in the paediatric population of Victoria 1999-2006. *Journal of Paediatric Surgery* 2009; 44: 427-431.
15. Bruijnen CJP, Vogels HDE, Beasley SW. Review of the extent to which orchidopexy is performed at the optimal age: Implications for health services. *ANZ J SURG* 2008; 78 : 1006-1009.
16. Kalid Founda Neel. Orchidopexy for undecended testis among Saudi children : Is it conducted at the optimal age?. *Curr pediater Res* 2010; 14 (1) : 39-41.

**Author Information**

**SANGRAM JADHAV, Dr., Professor and Unit Head**

DEPARTMENT OF GENERAL SURGERY DR. D. Y. PATIL MEDICAL COLLEGE, HOSPITAL & RESEARCH  
CENTRE PIMPRI

PUNE, MAHARASTRA, INDIA

**PHANI KUMAR, Dr., Chief Resident**

DEPARTMENT OF GENERAL SURGERY DR. D. Y. PATIL MEDICAL COLLEGE, HOSPITAL & RESEARCH  
CENTRE PIMPRI

PUNE, MAHARASTRA, INDIA