

Case Series: Intensity Modulated Radiotherapy to Treat Limited Stage Non-Endemic Nasal Natural Killer/T Cell Lymphoma

A Kumar, C Bui, S Nasta, S Schuster, J Plastaras

Citation

A Kumar, C Bui, S Nasta, S Schuster, J Plastaras. *Case Series: Intensity Modulated Radiotherapy to Treat Limited Stage Non-Endemic Nasal Natural Killer/T Cell Lymphoma*. The Internet Journal of Hematology. 2012 Volume 8 Number 1.

Abstract

Initial treatment with radiation alone to doses >54 Gy with has become standard treatment for patients with limited stage extranodal natural killer/T-cell lymphoma, nasal type (NKTL-NT). We report on four consecutive non-Asian patients with NKTL-NT treated with IMRT to spare critical structures while delivering high dose to the nasal and paranasal sinuses. Three patients are alive and without evidence of disease at 43.7, 19.5, and 30.4 months following radiation. One patient who died failed locally in an area of modest dose (45-50 Gy) as well as distantly. Acute toxicities were mainly mucositis (3 with Grade 2, 1 with Grade 3) managed with gabapentin and/or narcotics, Grade 2 xerostomia (1 patient), and Grade 1 dermatitis (1 patient). Two patients had late Grade 2 xerostomia and 1 patient required dacryocystorhynchostomy for excessive tearing. Early stage NKTL-NT can be treated definitively with high-dose radiation treatment, and we believe that IMRT offers an advantage to improve the therapeutic index over conformal 3-dimensional RT.

INTRODUCTION

Extranodal natural killer/T-cell lymphoma, nasal type (NKTL-NT) is a rare malignancy that has its highest incidence in East Asian countries and Latin America (1). NKTL-NT, also previously known as lethal midline granuloma, polymorphic malignant reticulosis, and angiocentric immunoproliferative lesion, is recognized as a distinct entity in the WHO classification, and is staged according to the Ann Arbor system. The immunophenotype of NKTL-NT reflects natural killer (NK) cells but also reflects T cells. NKTL-NT is histologically associated with frequent angioinvasion and angiocentricity with zonal necrosis, has been associated with the Epstein-Barr Virus (EBV), and is associated with the absence of B-cell markers and the presence of T and NK cell markers CD2 and CD56, respectively. Typically patients with NKTL-NT present with a chronic sinusitis that does not abate with conservative medical management.

Chemotherapy, typically a mainstay in treating Non-Hodgkin's Lymphoma (NHL), is largely ineffective in treating NKTL-NT. Several reports have shown a survival benefit to patients diagnosed with limited stage (IE, IIE) NKTL-NT and treated with high-dose radiation, especially when used as the initial treatment modality (2-8). One

retrospective study has suggested that radiation doses above 54 Gy are associated with better outcomes (5). As there have been few studies to date evaluating the optimal radiation dose, prescribed doses have encompassed a wide range, but it is clear that 30 - 40 Gy that are routinely used to treat other types of lymphoma is too low. In order to deliver higher doses near the base of skull while sparing normal structures, more conformal radiation techniques may be of value. In a dosimetric study, Tomita et al. determined that IMRT provided better tumor coverage while sparing organs at risk compared to conventional 3D techniques (9). As such, in this report, we discuss our experience in treating four non-Asian patients with NKTL-NT using intensity modulated radiotherapy (IMRT).

METHODS

Patients diagnosed with biopsy proven NKTL-NT were treated with definitive radiotherapy planned using IMRT treated between 2008 and 2009. Patients were simulated with a head mask for immobilization and a bite block to displace the tongue inferiorly. In general, gross tumor volume (GTV) was identified by flexible nasopharyngolaryngoscopy, FDG PET and/or MRI. The GTV was expanded by 0.5 to 1 cm to create a high dose CTV. A low dose CTV was defined based on patient's GTV

and areas thought to be at risk which could include paranasal sinuses in all patients and elective cervical levels Ib, II, III, upper V, and retropharyngeal lymph nodes. PTV expansions of 5 mm were added to account for set up error with 5 mm cropping from skin. For IMRT planning, non-coplanar beams were used as needed.

CASE REPORTS

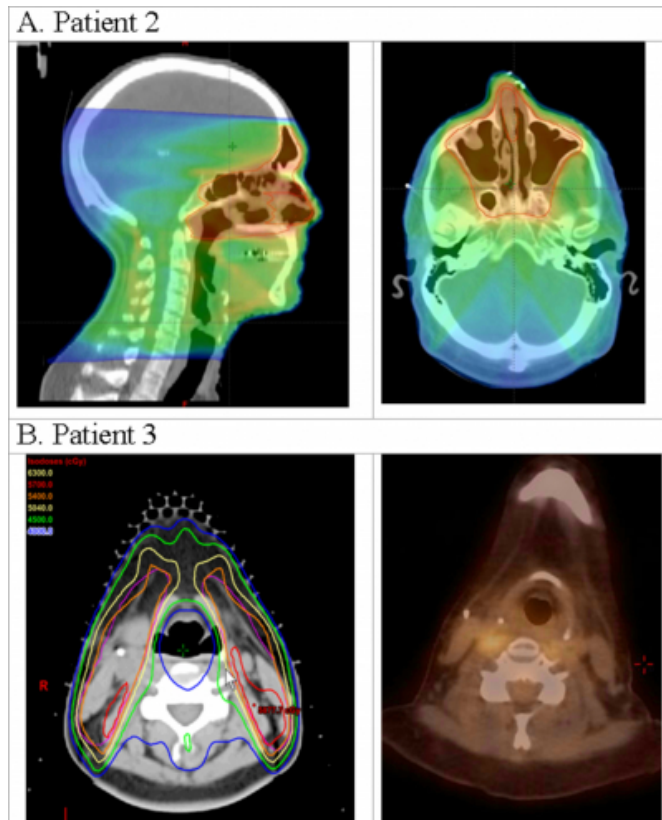
Patient 1, a 70 year old Caucasian male with a history of Parkinson's disease, presented with chronic sinusitis for six years that had progressively worsened. He had two sinus surgeries 3 years prior to diagnosis with no relief. Nasopharyngeal biopsies were inconclusive, but nasal culture revealed a fungal infection that was treated with voriconazole that briefly improved symptoms. Repeat biopsy demonstrated NKTL-NT with characteristic necrosis. Early IgG antibodies to EBV were elevated at 1.96. The cells were CD3+, CD5+ with a subset of CD57+, CD56+ NK cells (10-15% of total infiltrate). There were numerous cells weakly positive for Epstein-Barr virus encapsulated RNA (EBER). A staging PET scan showed uptake in the primary tumor, and mild uptake in bilateral level II nodes that was inconclusive. His performance status was ECOG-0, and his LDH was elevated at 628 prior to treatment. His Stage IaA NKTL-NT was treated with a 9-field IMRT plan using 6 MV photons including a vertex field and an anterior superior oblique field. CTV_6300 was treated at 210 cGy per fraction for 30 fractions to 63 Gy using a simultaneous infield boost.. The CTV_5250 was treated at 175 cGy per fraction for 30 fractions to 52.5 Gy. Acutely, he developed Grade 2 xerostomia, Grade 2 mucositis in the nasal and oral cavities, and Grade 2 odynophagia managed with gabapentin and narcotics. He had no major skin reaction but developed altered mental status that resolved with discontinuation of narcotics. After the completion of treatment, he was admitted for failure to thrive, and was given total parenteral nutrition for several weeks. He was followed with MRI, PET, and endoscopic exam. He had Grade 2 xerostomia at 8 months, which subsequently improved. He had excessive tearing and required dacryocystorhynchostomy at 15 months. At 43.7 months follow-up, he was without evidence of NKTL-NT.

Patient 2, a 47 year old Caucasian male presented with sporadic nasal bleeding for 2 years and a mass in his left nares for 1 year. He was empirically treated for nasal polyps with antibiotics and steroids. A CT of the sinuses showed a left nasal mass and nasal septum deviation. He subsequently

underwent resection. Surface markers were CD2+, CD56+, CD20+, and CD30-. The lack of TCR and IGH gene rearrangements further supported the diagnosis of NKTL-NT. A bone marrow biopsy was negative. A post-operative MRI showed a 1.1 x 0.5 cm enhancing mass in the left nasal cavity, and a PET scan showed uptake in the nasal cavity that was suspicious for residual disease. His Stage IaA NKTL-NT was treated with radiotherapy alone with a 9-field IMRT plan with 6 MV photons at 200 cGy per day to 50 Gy. The CTV_5000 included the GTV, the paranasal sinuses including the frontal and anterior ethmoids, as well as the bilateral lymph node levels II, III, and retropharyngeal nodes. CTV_6400 (GTV with margin) was boosted to 64 Gy with 20 MeV electrons. The patient developed Grade 2 mucositis of the soft palate and was also treated for oral thrush. His odynophagia was managed with gabapentin alone without narcotics. He has been followed by MRI (at 1 and 3 months), PET (at 3 and 15 months), and CT (at 4 and 19 months). At 19.5 months follow-up, the patient is without evidence of disease, but he does have Grade 2 xerostomia.

Figure 1

IMRT dose distribution and location of regional recurrence. A) Sagittal and axial slices of IMRT dose distribution in color wash for Patient 2. B) Axial slices of the IMRT dose distribution (left) with isodose lines on the planning CT of Patient 3. PET/CT (right) of the same patient 3.7 months after treatment at the same level showing recurrence on the right.



Patient 3, a 35 year old Caucasian female presented with sinusitis for 3 years that did not improve with antibiotics and steroids. CT of the sinuses showed opacification of the right nasal cavity and nasopharyngeal asymmetry. A biopsy of the nasal cavity, sinus contents, and adenoids, showed necrotic vasculitis and granulomatous changes, and she was treated with steroids, methotrexate and subsequently cytoxan for a presumed diagnosis of Wegener's granulomatosis. She was subsequently had a right cervical node excision that showed NKTL-NT, which in retrospect was similar to her prior sinus/adenoid biopsy. The cells were CD20-, CD3+, CD5+, CD56-, CD57-, but EBER+. A bone marrow biopsy and CT of the neck, chest, abdomen, and pelvis showed no other disease. A PET/CT showed "physiologic uptake" in the vallecula (SUV 5.0). Endoscopy was performed and biopsy of the right tonsil and soft palate was suspicious for NKTL. Her Stage IIeA NKTL-NT was treated with radiotherapy alone with a 7 field IMRT technique with 6 MV photons.

CTV_5400 included the nasal cavity, sinuses and the suspected part of the oropharynx as well as the bilateral lymph node levels II, III, and retropharyngeal nodes, which was planned to an initial 54 Gy. However, after 16.2 Gy, a region of the posterior pharyngeal wall was felt to be suspicious for NKTL. The plan was modified at this point and the higher dose CTV treated to either. 63 Gy or 46.8 Gy. She developed Grade 3 oral mucositis, and Grade 1 dermatitis. Her odynophagia was managed with gabapentin and narcotics. At the completion of radiation, she developed a suspicious abdominal skin lesion that was biopsied and showed NKTL. She was started on systemic chemotherapy with Hyper-CVAD, followed by ICE salvage at progression. Endoscopy at 2.5 months with biopsy of the right maxillary sinus and nasopharynx showed no overt NKTL. A follow up PET/CT 3.7 months after radiation showed avid disease in her skin, kidneys, and multiple lymph nodes. Interestingly, the region of uptake in her right vallecula persisted. Although the positions are different, it appears that this lesion was in the moderate dose region between 45 and 50 Gy (Figure 1B). Her disease progressed rapidly despite salvage chemotherapy before she could be offered allogeneic stem cell transplant. She died of distant disease 7.6 months after completing radiotherapy.

Patient 4 is a 54 year old man with multiple medical problems including morbid obesity status post gastric banding and renal failure on hemodialysis who was discovered by head CT to have a sinonasal mass during an extended hospitalization for bacteremia. CT of the chest, abdomen, and pelvis did not show additional disease. Nasal mass biopsy showed NKTL-NT with cells that were CD3+, CD5-, CD56+ CD57-, and EBER+. A PET/CT showed an FDG avid (SUV 18.4) left nasal mass with extension to the left maxillary and ethmoid sinuses, but no evidence of metastatic disease. His Stage IAe NKTL-NT was treated with a 6 field IMRT plan (including SAO and IAO fields) in 180 cGy fractions. Due to his poor performance status (ECOG 3), the CTV_5400 included just the nasal cavity, paranasal and frontal sinuses, and retropharyngeal lymph nodes. His course was complicated by near syncope and fall following hemodialysis, resulting in a nasal fracture. He developed Grade 2 mucositis and odynophagia treated with intermittent narcotics. Before the planned boost could be delivered, the patient was admitted with sepsis felt to be related to hemodialysis. He was followed with MRI, PET, and endoscopic exam. He is without evidence of disease after 30.4 months of follow up with no late sequelae of

radiation.

DISCUSSION

An emerging standard of care for Stage I and II NKTL-NT is definitive high-dose radiation with overall survival (OS) and disease free survival (DFS) rates of 52% and 39% at 5 years, respectively (5). Published accounts of treatment show that radiation doses range between 40 and 70 Gy and used various beam arrangements including opposed laterals (8), extended field (2), and 3-field technique (opposed laterals and AP) (3,4,6). Median doses in these studies were (in Gy) 45 (2,4), 50 (3,5) and 55 (6). While the trend in these studies has been dose escalation, further increases using conventional techniques is made difficult by dose-limiting structures adjacent to the nasal and paranasal sinuses; the concerns are similar to treatment of nasopharyngeal carcinoma. Recent retrospective data indicate that doses of at least 54 Gy have a significant difference in OS and DFS (5). It should be noted that studies for which lower ranges were prescribed included patients who were receiving concurrent or adjuvant chemotherapy. For example, CHOP-like regimens can produce responses in many patients (10), however chemotherapy followed by radiation has had mixed results (11). In a more recent phase II trial reported by Kim et al evaluating the outcomes with concurrent weekly cisplatin (30 mg/m²) and radiation (40-52.8 Gy) using conventional fields followed by adjuvant VIPD, 100% of patients completed the planned treatment course with a 3 year progression free survival of 83% (12). However, there were 12 of 29 patients who developed grade 4 neutropenia. Yamaguchi et al reported that concurrent chemoradiation with dexamethasone, etoposide, ifosfamide, and carboplatin and 50 Gy was tolerable with an excellent overall response rate (81%) (13). The 5-year OS (73%) and PFS (67%) compares very favorably to historical controls with radiation alone (14). Other treatments such as consolidative autologous stem cell transplant may benefit patients who are in a complete remission (15). New therapeutic agents such as L-asparaginase containing regimens have shown promise in Stage IV disease refractory to other chemotherapy with a complete response rate near 60% (16,17). There is evidence that advanced NKTL may be suppressed by the graft-versus-lymphoma effect associated with allogeneic transplant (18).

Only recently have both toxicity and outcomes with IMRT been explored. For example, a Chinese study reported on 42 patients diagnosed with early stage NKTL-NT that were treated with IMRT (extended involved field) with an average

PTV dose of 55.5 Gy in 2 Gy per fraction (19). The 2 year locoregional control was 93% with no reported grade 4 or 5 toxicity. In our experience treating NKTL-NT definitively with high dose radiation (greater than 54 Gy) and a lower dose elective nodal volume, only one patient (patient 3) had grade 3 toxicity; the three other patients only had grade 2 toxicity. Three of the 4 patients are living without evidence of disease. While higher doses (60-63 Gy) may provide better local control than moderate doses (50-54 Gy), this is certainly still not known, and it is possible that the higher doses used in some of the patients in our series were “over-treated.” Similar to nasopharyngeal carcinoma, we believe the treatment of NKTL-NT benefits from IMRT given the ability to deliver high doses of radiation near the base of skull and sparing the eyes, optic apparatus, and parotid glands. From a radiation planning perspective, superior or inferiorly oblique fields can aid in target coverage while sparing organs at risk. In our series, we were able to constrain the chiasm and optic nerves to our target of maximum doses of less than 54 Gy for all four patients (Table 1). We were only able to keep the mean parotid gland doses below our target of 26 Gy in 2 of the 4 patients, but all were under 40 Gy. When treating a target that is between the eyes, it is very difficult to achieve the dosimetric goals, and some compromises may be made compared to usual organ-at-risk constraints. In our series, the mean eye doses were all 37 Gy or less (target usually less than 30 Gy), and maximum doses were 54 Gy or lower (target usually less than 45 Gy).

In the patients that we treated, there has been no evidence for local recurrence following treatment except in patient 3. She had PET-avid disease in the head and neck was in an area that received a moderate radiation dose that may represent a marginal miss, although this region was never biopsied. Her pre-treatment PET/CT did not show uptake in the regions of biopsy-proven gross disease, possibly due to prior treatment with chemotherapy for presumed Wegener’s Granulomatosis. Although her simultaneous distant failure may just reflect her poor biology, her case does hint at a dose response, supporting the idea that greater than 54 Gy is required to control gross NKTL. In fact, a published consensus statement in-field failures are mainly due to inadequate radiotherapy dosage (less than 50 Gy) and/or lack of imaging studies during radiation planning (20). In two of the other patients, the pre-treatment PET/CT was helpful in defining the extent of the disease and targeting the boost. The role of PET in NKTL-NT is still unclear, but it appears to be helpful when correlated with other staging modalities

to plan radiotherapy (Figure 2).

Figure 2

Figure 2. FDG-PET/CT imaging prior to radiotherapy. Patient 1 axial view of CT (Panel A) and FDG-PET (Panel B) was used to define the target volume. Patient 4 axial view of fused FDG-PET/CT (Panel C) performed at the time of radiation treatment planning shows the FDG-avid gross tumor volume (thin orange line) and the clinical target volume (thick orange line) that was treated to 54 Gy.

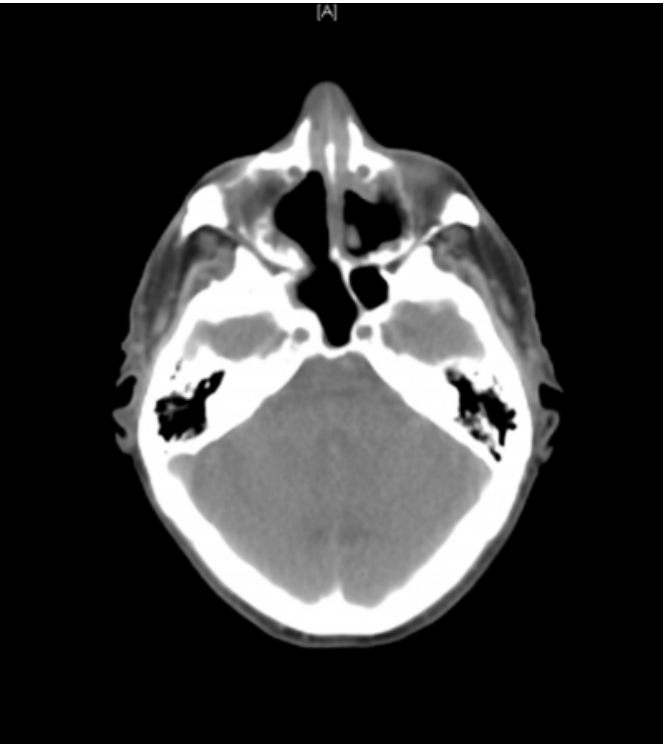
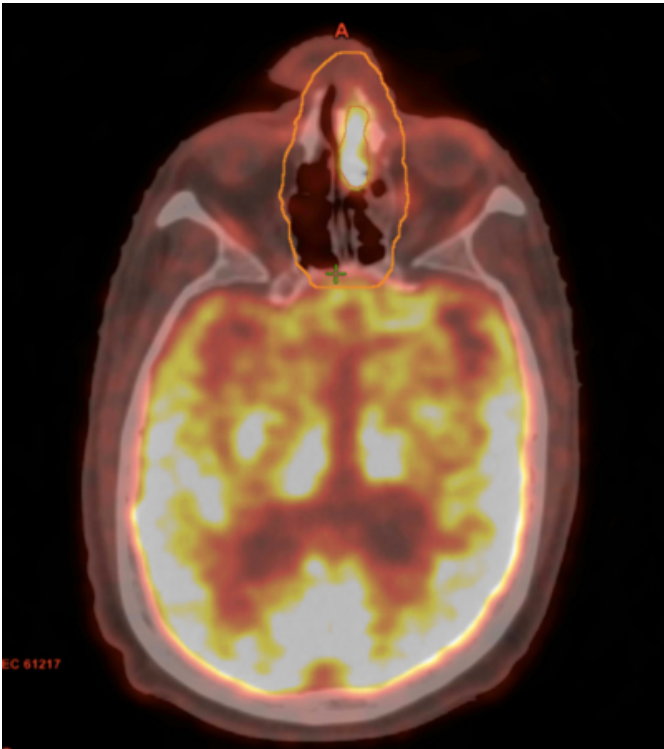


Figure 3

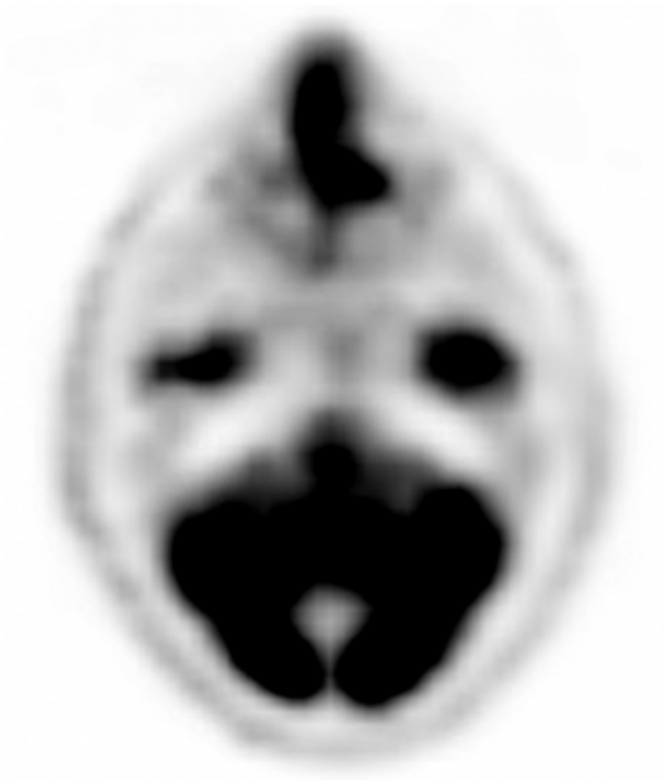

Figure 4



While these four patients do not represent classic demographic cases of NKTL-NT (young Asian male), their

presentations are typical. The side effects they experienced are common for patients receiving radiation to the nasopharynx, but lesser in severity given the lack of concurrent chemotherapy and slightly lower total doses used (21). In Asian studies, the neck nodes are routinely omitted as the risk of nodal spread is thought to be low (22). In the Chinese IMRT study only the involved nodes were part of the GTV and there was no routine coverage of cervical lymph nodes (19.) Of the 42 patients on the study, 13 (31%) had a locoregional or distant failure and 3 (7%) had a failure in the cervical neck. Since IMRT allows for nodal treatment with minimal added morbidity, we chose to treat extended volumes in patients with good performance status in an effort to minimize regional failure which is approximately 7% based on the Chinese data. However, as can be seen with patient 4, the parotids can be spared more easily if cervical nodes are not electively treated (Table 1). Treating the elective lymph nodes should be determined on a case-by-case basis but routinely including them in high dose treatment volumes is likely to cause more significant toxicity with only a potential locoregional control benefit of 7%. When available, IMRT is a logical method to radiate early stage NKTL-NT to a sufficiently high dose with acceptable toxicity.

CONCLUSION

Early stage NKTL-NT can be treated definitively with high-dose radiation treatment, and we believe that IMRT offers an advantage to improve the therapeutic index.

ACKNOWLEDGEMENTS

The authors would like to thank Dr. Stefan Both, Paul James, Rochelle Wise-Payne, Dr. Tien Xue, and Bill Marsh for their assistance with IMRT planning.

References

1. Aozasa, K., Takakuwa, T., Hongyo, T., and Yang, W. I. (2008) *International journal of hematology* 87, 110-117
2. Aviles, A., Diaz, N. R., Neri, N., Cleto, S., and Talavera, A. (2000) *Clinical and laboratory haematology* 22, 215-220
3. Cheung, M. M., Chan, J. K., Lau, W. H., Ngan, R. K., and Foo, W. W. (2002) *International journal of radiation oncology, biology, physics* 54, 182-190
4. Chim, C. S., Ma, S. Y., Au, W. Y., Choy, C., Lie, A. K., Liang, R., Yau, C. C., and Kwong, Y. L. (2004) *Blood* 103, 216-221
5. Huang, M. J., Jiang, Y., Liu, W. P., Li, Z. P., Li, M., Zhou, L., Xu, Y., Yu, C. H., Li, Q., Peng, F., Liu, J. Y., Luo, F., and Lu, Y. (2008) *International journal of radiation oncology, biology, physics* 70, 166-174
6. Kim, K., Chie, E. K., Kim, C. W., Kim, I. H., and Park, C. I. (2005) *Japanese journal of clinical oncology* 35, 1-5
7. Li, Y. X., Coucke, P. A., Li, J. Y., Gu, D. Z., Liu, X. F., Zhou, L. Q., Mirimanoff, R. O., Yu, Z. H., and Huang, Y. R. (1998) *Cancer* 83, 449-456
8. Li, Y. X., Yao, B., Jin, J., Wang, W. H., Liu, Y. P., Song, Y. W., Wang, S. L., Liu, X. F., Zhou, L. Q., He, X. H., Lu, N., and Yu, Z. H. (2006) *J Clin Oncol* 24, 181-189
9. Tomita, N., Kodaira, T., Tachibana, H., Nakamura, T., Nakahara, R., Inokuchi, H., Mizoguchi, N., and Takada, A. (2009) *Br J Radiol* 82, 756-763
10. Guo, Y., Lu, J. J., Ma, X., Wang, B., Hong, X., Li, X., and Li, J. (2008) *Oral oncology* 44, 23-30
11. Wang, B., Lu, J. J., Ma, X., Guo, Y., Lu, H., Hong, X., and Li, J. (2007) *Leukemia & lymphoma* 48, 396-402
12. Kim, S. J., Kim, K., Kim, B. S., Kim, C. Y., Suh, C., Huh, J., Lee, S. W., Kim, J. S., Cho, J., Lee, G. W., Kang, K. M., Eom, H. S., Pyo, H. R., Ahn, Y. C., Ko, Y. H., and Kim, W. S. (2009) *J Clin Oncol* 27, 6027-6032
13. Yamaguchi, M., Tobinai, K., Oguchi, M., Ishizuka, N., Kobayashi, Y., Isobe, Y., Ishizawa, K., Maseki, N., Itoh, K., Usui, N., Wasada, I., Kinoshita, T., Ohshima, K., Matsuno, Y., Terauchi, T., Nawano, S., Ishikura, S., Kagami, Y., Hotta, T., and Oshimi, K. (2009) *J Clin Oncol* 27, 5594-5600
14. Yamaguchi, M., Tobinai, K., Oguchi, M., Ishizuka, N., Kobayashi, Y., Isobe, Y., Ishizawa, K., Maseki, N., Itoh, K., Usui, N., Wasada, I., Ishikura, S., Kagami, Y., Kinoshita, T., Hotta, T., Tsukasaki, K., and Oshimi, K. (2012) Long-term follow-up results of a phase I/II study of concurrent chemoradiotherapy for localized nasal NK/T-cell lymphoma (NKTCL): JCOG0211. in *ASCO Annual Meeting*
15. Lee, J., Au, W. Y., Park, M. J., Suzumiya, J., Nakamura, S., Kameoka, J., Sakai, C., Oshimi, K., Kwong, Y. L., Liang, R., Yiu, H., Wong, K. H., Cheng, H. C., Ryoo, B. Y., Suh, C., Ko, Y. H., Kim, K., Lee, J. W., Kim, W. S., and Suzuki, R. (2008) *Biol Blood Marrow Transplant* 14, 1356-1364
16. Jaccard, A., Gachard, N., Marin, B., Rogez, S., Audrain, M., Suarez, F., Tilly, H., Morschhauser, F., Thieblemont, C., Ysebaert, L., Devidas, A., Petit, B., de Leval, L., Gaulard, P., Feuillard, J., Bordessoule, D., and Hermine, O. (2011) *Blood* 117, 1834-1839
17. Yong, W., Zheng, W., Zhu, J., Zhang, Y., Wang, X., Xie, Y., Lin, N., Xu, B., Lu, A., and Li, J. (2009) *Ann Hematol* 88, 647-652
18. Kako, S., Izutsu, K., Oshima, K., Sato, H., Kanda, Y., Motokura, T., Chiba, S., and Kurokawa, M. (2007) *Am J Hematol* 82, 937-939
19. Wang, H., Li, Y. X., Wang, W. H., Jin, J., Dai, J. R., Wang, S. L., Liu, Y. P., Song, Y. W., Wang, Z. Y., Liu, Q. F., Fang, H., Qi, S. N., Liu, X. F., and Yu, Z. H. (2012) *International journal of radiation oncology, biology, physics* 82, 1115-1121
20. Kwong, Y. L., Anderson, B. O., Advani, R., Kim, W. S., Levine, A. M., and Lim, S. T. (2009) *Lancet Oncol* 10, 1093-1101
21. Lee, N., Xia, P., Fischbein, N. J., Akazawa, P., Akazawa, C., and Quivey, J. M. (2003) *International journal of radiation oncology, biology, physics* 57, 49-60
22. Wang, Z. Y., Li, Y. X., Wang, W. H., Jin, J., Wang, H., Song, Y. W., Liu, Q. F., Wang, S. L., Liu, Y. P., Qi, S. N., Fang, H., Liu, X. F., and Yu, Z. H. (2009) *Blood* 114, 4771-4776

Author Information

Aryavarta M. S. Kumar

Case Western Reserve School of Medicine

Courtney Bui

Department of Radiation Oncology, University of Maryland

Sunita Nasta

Department of Internal Medicine (Hematology-Oncology), Hospital of the University of Pennsylvania

Stephen J. Schuster

Department of Internal Medicine (Hematology-Oncology), Hospital of the University of Pennsylvania

John P. Plastaras

Department of Radiation Oncology, Hospital of the University of Pennsylvania